

Trends in the treatment of dermatophytosis

Amalia del Palacio, Margarita Garau, Alba Gonzalez-Escalada and M^a Teresa Calvo

Department of Microbiology, Hospital Universitario "12 de Octubre", Madrid, Spain

Summary The aim of this paper is to give an updated view of treatment schedules discussing topical and systemic antifungal therapy of dermatophytosis with current available antifungals.

Key words Dermatophytosis, Topical treatment, Systemic treatment

According to WHO (World Health Organisation), the dermatophytes are defined as a group of molds that form three genera: *Epidermophyton*, *Trichophyton* and *Microsporum* [1]. They comprise about 40 different species, and have common characteristics:

1. Close taxonomic relationships
2. Keratinolytic properties (they all have the ability to invade and digest the keratin as saprophytes "in vitro" and parasites "in vivo", producing lesions in the living host).
3. Occurrence as etiologic agents of infectious diseases of man and/or animals (dermatophytoses are mycoses of man and animals caused by dermatophytes).

In man they invade hairs, nails and skin (they are found in the stratum corneum - the keratinized outer layer - and within the hair follicle, in the nail folds and subungually in the nail bed). All these are extensions of the stratum corneum.

Dermatophytes may be classified according to the genera, the ecology and patterns of infection [1]. The clinical picture forms distinct entities grouped according to the infected site, namely *tinea capitis* (Figure 1), *tinea barbae*, *tinea favosa*, *tinea corporis* (Figures 2 and 3), *tinea imbricata*, *tinea cruris*, *tinea pedis* (Figure 4), *tinea manuum* and *tinea unguium* (Figure 5)[1,2].

Presumptive diagnosis of dermatophytosis on clinical grounds should always be confirmed by direct microscopy (Figures 6 and 7) and culture [2]. The success of mycological examination is dependent on the selection of suitable specimens.

The dermatophyte fungi are ubiquitous and no geographical area nor any group of people is spared by these organisms. Since dermatophytosis is not notifiable by law, the real prevalence and incidence is unknown. However, they have a worldwide distribution [3], although some species are restricted to certain geographical areas [3,4].

The management of dermatophytosis begins with topical agents. These agents should penetrate the skin and remain there in order to suppress the fungus.

In the last 50 years numerous drugs have been introduced for the treatment of superficial infections. The choice of treatment is determined by the site and extent of the infection, the species involved as well as by the efficacy and safety profile, and kinetics of the drugs available. For localised non-extensive lesions caused by dermatophytes topical therapies with an imidazole, allylamines, tolnaftate, morpholine derivatives, etc is generally used.

For *tinea unguium*, scalp ringworm, extensive dermatophytosis, or skin lesions with folliculitis, systemic antifungal treatment is necessary.

The rational treatment of dermatophytosis requires mycological confirmation (KOH and culture); in other words the clinician should confirm a presumptive clinical diagnosis of dermatophyte infection before the start of treatment. Since spontaneous healing of dermatophytosis is uncommon, treatment implementation is necessary.

Dermatophytes are located in the stratum corneum within the keratinocytes. The signs and symptoms that appear in infected individuals are due to acute and chronic inflammatory changes that appear in the dermis. For these reasons, antifungal agents should have the ability to penetrate the stratum corneum cells to be efficient when applied topically. The vast majority of antifungals are fungistatic with the concentrations achieved in the skin when applied topically; the growth of dermatophytes is delayed and these are shed with the skin renewal and healing is achieved. The antifungal agents and the components incorporated on the vehicle should be non-irritant and well tolerated.

The vast majority of antifungals are applied twice daily, although the latest ones introduced are applied only once daily. Attention is currently being directed towards shortening the course of therapy and applying the medication once daily in an attempt to increase patient compliance and it is generally advisable to prolong treatment for two weeks once clinical cure is achieved. Skin lesions located on face, trunk and limbs usually require two or three weeks of treatment. Inflammatory dermatophyte infections of the feet should be treated for four or six weeks and hyperkeratotic lesions of palms and soles are best treated with oral antifungals since they are usually unresponsive to topical antifungals.

Corresponding address:

Dra. Amalia del Palacio
Department of Microbiology,
Hospital Universitario "12 de Octubre",
Madrid 28041, Spain
Tel.: +34 91 390 8239; Fax: +34 91 390 8358

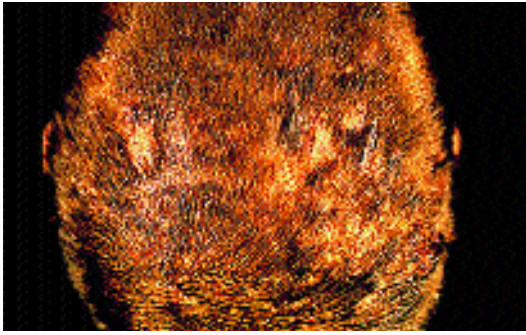


Figure 1. *Tinea capitis*. Highly inflammatory form (kerion) due to *T. tonsurans*.

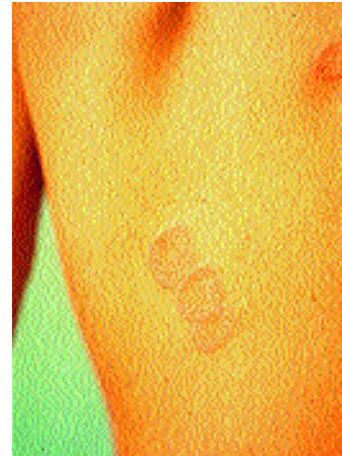


Figure 2. Ringworm due to *M. canis*.

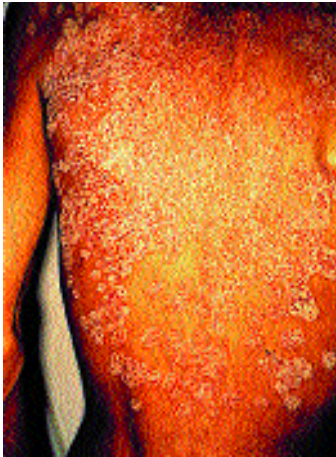

Figure 3. Extensive *tinea corporis* due to *T. gallinae* in a patient with AIDS.

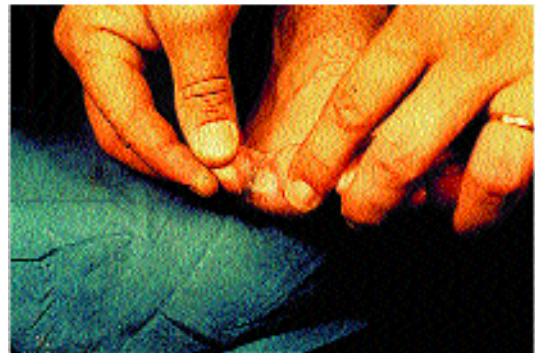

Figure 4. *Tinea pedis interdigitalis* due to *T. rubrum*.

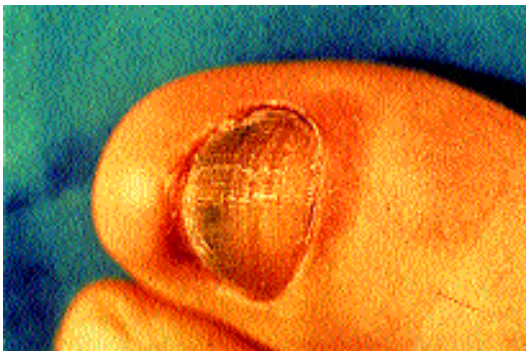


Figure 5. Toe nail onychomycosis due to *T. rubrum*.

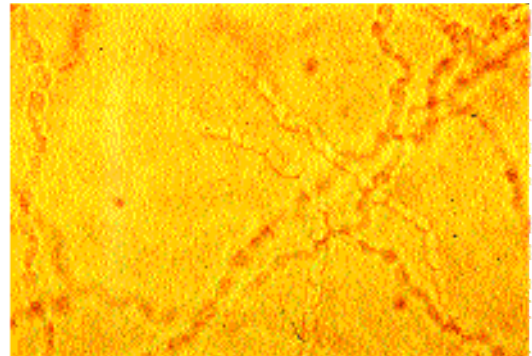


Figure 6. Direct microscopy with dematophyte hyphae. KOH (400x).

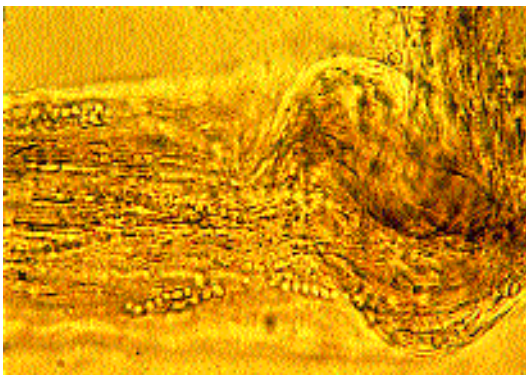


Figure 7. Direct microscopy of hair showing dermatophyte hyphae and spores. KOH (400x).

Topical treatment of dermatophytosis is possible with non-extensive lesions, the application of medication should be done rubbing it in gently in the affected skin area and should exceed (surpass) one cm. of healthy skin. It is important that the patient follows the application of treatment with the schedule recommended by the doctor.

Oral treatment is indicated in widespread skin lesions, *tinea capitis*, *tinea barbae*, *tinea unguium*, in skin lesions with folliculitis, and when either there is no response to topical treatment or tolerance is not adequate.

Oral antifungal agents for the treatment of dermatophytosis

The oral compounds with the potential for treating dermatophytosis are shown in table 1.

Table 1. Oral antifungal agents for the treatment of dermatophytosis.

Class	Drug
Miscellaneous	Griseofulvin
Azoles	Ketoconazole
Triazoles	Itraconazole Fluconazole Voriconazole
Allylamines	Terbinafine

Griseofulvin is still currently the gold standard for treatment of dermatophytosis (excluding *tinea unguium*) since being introduced clinically in the sixties following the observations of Gentles [5]. This antifungal, produced by a *Penicillium* sp., has successfully eradicated dermatophyte infections. This drug has been widely used both in adults and children and has an excellent safety profile.

Absorption of griseofulvin is poor in the gastrointestinal tract and it is influenced by particle size, dietary fat intake and the dissolution rate of the various preparations. Micronized and ultramicrotonized formulations are better absorbed [6]. Overall bioavailability is variable, ranging from less than 25% to approximately 70% of the administered dose [7]. In skin the highest concentration is achieved in the outermost stratum corneum. Non-protein-bound drug is carried in the extracellular fluid, in sweat, and through transepidermal fluid loss [7]. Several investigations have shown that the concentration of griseofulvin in the skin is sensitive to the rate of eccrine sweat production, although in diseased skin the participation of sweat is not clear [8]. Once griseofulvin reaches the stratum corneum, reversible protein binding and lipid solubility result in its concentration in the horny layer and when administration is discontinued the drug is rapidly cleared.

Griseofulvin is eliminated as different metabolites in the urine and faeces and requires a daily dosing. Once treatment is discontinued, griseofulvin is rapidly cleared from the site of infection and as a consequence, treatment should be maintained until a clinical cure is apparent [7].

Dosages of 10 mg/kg/day microsize are widely used, but 20 to 30 mg/kg/day may be required, particularly in *tinea capitis*. Resistance has not been documented clinically.

When the drug is taken with meals, side effects are generally uncommon. Headache is the most common, but it usually disappears if treatment is discontinued. Other side effects that occur infrequently involve the skin, the gastrointestinal, nervous, genitourinary and musculoskeletal systems.

No new oral antifungal agents appeared until ketoconazole was introduced in 1980. This drug was an advance in the treatment of mycoses, but nowadays there are many concerns about its use, basically due to a significant incidence of idiosyncratic hepatic toxicity [7,9], with an estimated incidence as high as 1 in 3000 patients. Other serious side effects involve the central nervous system or endocrine system (adrenal androgens and glucocorticosteroids) [7].

Itraconazole is a triazole agent, poorly water-soluble and whose bioavailability improves when the drug is

taken with a fatty meal [10]. Oral absorption is dose-dependent [10-12]. It is >99.8% protein bound in plasma (albumin), but some binding is also associated with red blood cells. It is extremely lipophilic and achieves high concentrations in fat, omentum, skin/nails and vaginal/cervical tissues [10]. Accumulation in skin is slow and antifungal therapeutically active high concentrations persist up to a month after the end of treatment [13]. The concentrations in skin exceed 3 to 10 times those found in plasma [13]. Itraconazole has a terminal elimination half-life of 20 to 60 hours, suggesting that steady state concentrations are achieved after 2 weeks of continuous treatment. Approximately 65% of the compound is eliminated in faeces and 35% in urine, in the form of diverse metabolites. No dosage adjustment is required for hepatic or renal function.

Itraconazole appears as a safe drug [10], the frequency of side effects appearing to depend on the duration of therapy and occurring in 7% to 12% of patients [10]. Nausea, vomiting and headache are the most frequent side effects, and liver function abnormalities occur in <1% of patients. Itraconazole is available in liquid and capsule form. The solution contains cyclodextrin, which raises carcinogenic concerns, since it has been shown to cause pancreatic adenocarcinomas in rats at human exposure doses. However, at present the significance of this is uncertain. In any case, the cyclodextrin formulation increases markedly the absorption of itraconazole, may be taken while fasting and there appears to be no interference by H₂ or proton pump blockers [14]. One distinct advantage of this liquid formulation is its potential for topical therapy of mucosal candidiasis, but a disadvantage is that it has an unpleasant taste. The upper dose limit for liquid itraconazole has not been determined. Table 2 shows the bioavailability of itraconazole capsules and solution. At present liquid itraconazole is being developed as a parenteral agent and studies are in progress in several countries for the management of deep-seated mycoses in patients that have had bone marrow transplants.

Table 2. Relative bioavailability of itraconazole capsules and solution determined by measuring serum concentrations. Data from Janssen Pharmaceuticals.

	Capsule	Solution
With meals	100%	125%
Fasting	60%	165%

Fluconazole is a triazole that is water-soluble and extremely well absorbed [12]. Its high bioavailability appears unaffected by food intake, pH or antacids [11]. There is minimal protein binding, a property that precludes many adverse drug-drug interactions. Fluconazole is widely distributed to body tissues, including cerebrospinal fluid [11,12]. It has a long half-life, approximately 22 to 30 hours in adults and steady state concentrations are reached 6 to 10 days after the start of treatment [12]. Most of the drug is excreted unchanged in the urine since it undergoes no hepatic metabolism. It is eliminated more slowly from skin, and therefore clinical cures may be achieved after the withdrawal of treatment. It requires dosage adjustment in patients with impaired renal function. Side effects occur in ~16% of patients [11,12]. Nausea, vomiting and liver test abnormalities are most common side effects.

Voriconazole is a third generation triazole under preclinical development [15]. It has a wide spectrum of activity that includes yeasts (including those usually resistant to fluconazole such as *Candida glabrata*, *C. krusei* and *C. lusitanae*). It is also active *in vitro* against *Aspergillus* spp, *Cryptococcus neoformans*, dimorphic fungi and different emerging pathogens such as *Fusarium* spp., *Acremonium* spp., *Scedosporium* spp., *Trichosporon* spp. and *S. apiospermum* [15,16]. Pharmacokinetics show bioavailability up to 90% after oral dosing and has widespread distribution throughout the body. Plasma protein binding in humans is approximately 65%, 78%-88% of which is metabolised and appears in urine, and less than 5% remains unchanged [17].

From a dermatological point of view it is interesting to note that voriconazole is active *in vitro* against dermatophytes and *Malassezia* spp [18,19]. There are no current published data on the pharmacokinetics of voriconazole in skin, sebum, hair and nails. This *in vitro* activity against dermatophytes is promising but it remains to be seen if these preliminary *in vitro* data will indeed be predictive of clinical efficacy in dermatophyte infections.

At present, voriconazole is available as an oral formulation and an intravenous cyclodextrin suspension. Oral absorption seems to be impaired by food intake [15]. Voriconazole interacts with cyclosporine and warfarine and plasma levels drop when rifampicin, rifabutin and phenitoin are administered simultaneously [15,16].

Terbinafine is a fungicidal allylamine that is absorbed from the gastrointestinal tract, with a bioavailability of 70-80%, reaching peak plasma concentration in two hours approximately [20]. Terbinafine binds strongly to plasma proteins and about 8% binds to blood cells [12], achieving high concentrations in skin and skin structures [21,22].

Almost 80% of the administered dose is eliminated as metabolites in urine. Dosage adjustment is required in patients with severe hepatic or renal dysfunction, or both [12,20]. When treatment with terbinafine ceases the concentration in stratum corneum remains high (0,1 µg/ml) for 8 weeks and enables the use of short courses of treatment. The incidence of adverse effects with terbinafine therapy is approximately 10% [12]. Most of them appear during the first few weeks of treatment and tend to disappear with continued therapy.

Table 3 shows the most relevant characteristics of oral antifungal used for the management of dermatophyte infections.

Several recently published reports discuss safety considerations with the commonly used oral antifungal agents [6,23-29].

Table 4 which is adapted from reference 30 shows the most common drug interactions with newly introduced antifungals. As shown in this table, terbinafine has rare interactions when compared with fluconazole and itraconazole.

Table 4. Triazoles and terbinafine interactions (Adapted from [30]).

Terbinafine	Fluconazole	Itraconazole
Drugs that increase antifungal levels		
Cimetidine	Hydrochlorotiazide	None
Drugs that decrease antifungal levels		
Rifampicine Phenobarbital	Rifampicine	Rifampicine Isoniazide Phenitoin Antiacid agents Anticolinergic agents Phenobarbitone Carbamacepine
Drugs whose levels may be increased by antifungal agents		
None	Warfarine Oral antidiabetics Phenitoin Cyclosporine Terfenadine Astemizole	Phenitoin Warfarine Ciclosporine Terfenadine Astemizole Oral antidiabetics Digoxine Insulin Corticoids Triazolam Felodipine Midazolam Cisapride
Drugs whose levels may be decreased by antifungal agents.		
None	Oral contraceptives	Antipirine Oral contraceptives

Topical antifungal treatment of dermatophytosis

The topical compounds with potential utility for treating dermatophytosis are shown in table 5 and table 6 shows the indications for topical treatment of dermatophyte infections.

The doctor who prescribes treatment of dermatophytosis should choose a given antifungal or treatment schedule considering different factors such as kinetics and levels achieved in stratum corneum, clinically proven efficacy, risk/benefit relationship, duration of treatment, cost, percentage recurrence in long term assessment, individual preference of patients, species of dermatophyte responsible for the infection and underlying conditions of the patient [7,11,12,23,31,32].

Currently, of all the miscellaneous compounds shown in Table 5, only ciclopiroxalamine is widely used. A new topical formulation of griseofulvin was developed a few years ago, and although it is not widely used it has proved to be useful [33]. Most of these miscellaneous compounds were used in the fifties.

Topical azoles (see Table 5) were introduced in the sixties. The first clinical trials showed that they were superior when compared with haloprogin and Whitfield's ointment, although the latter has the distinct advantage of

Table 3. Characteristics of oral antifungal agents for the treatment of dermatophyte infections.

	Griseofulvin	Ketoconazole	Fluconazole	Itraconazole	Voriconazole	Terbinafine
Keratin binding	low	strong	low	strong	*	strong
Excretion by sweat	high	high	high	moderate	*	low
Grease affinity	low	low	low	high	*	high
Mechanism of action	Disrupts micotic spindle/microtubules	Inhibits 14- α demethylation of lanosterol	Inhibits 14- α demethylation of lanosterol	Inhibits 14- α demethylation of lanosterol	Inhibits fungal cytochrome P-450 dependent 14- α lanosterol demethylase	Inhibits squalene epoxidation
Fungicidal	No	No	No	No	*	Yes

Table 5. Topical antifungal agents for the treatment of dermatophytosis (modified from [11]).**Morpholine derivatives**

Amorolfine

Allylamines and benzylamine derivativesNaftifine
Terbinafine
Butenafine**Azole derivatives**

Bifonazole, butoconazole, clotrimazole, croconazole, eberconazole, econazole, fenticonazole, flutrimazole, isoconazole, ketoconazole, miconazole, omoconazole, oxiconazole, sertaconazole, sulconazole, terconazole, tioconazole.

Miscellaneous compounds

Ciclopiroxalamine, griseofulvin, haloprogin, tolnaftate, Whitfield's ointment, undecylenic acid.

lower cost and the disadvantage of being an irritative agent. Allergic contact dermatitis with imidazoles is rare. Irritant effects may occur with any of them.

An interesting feature of topical antifungal preparations is that they possess inherent anti-inflammatory activity, leading to rapid symptomatic relief while also providing mycological cure. Rosen *et al.* [34] using different commercially available antifungal preparations *in vivo* in humans have shown that the allylamine preparations and ciclopiroxalamine were the most anti-inflammatory and ketoconazole had intermediate activity under experimental conditions used by the authors. These agents were superior to oxiconazole, econazole and even 2.5% hydrocortisone. The exact mechanism of this anti-inflammatory activity remains uncertain at present.

The last topical compound introduced in Japan in 1992 and in the U.S.A. in 1997 is butenafine [35-39]. The compound is expected to be launched in 1999 in the European Community. Butenafine binds strongly to keratin and has an *in vitro* spectrum that covers both dermatophytes and *Candida albicans* [35-39]. An important feature of butenafine is that the healing rate increases significantly after treatment is stopped. Butenafine is a fungicidal benzylamine derivative that blocks squalenepoxidase.

Treatment schedules

Dermatophyte infections require different treatment schedules depending on the infected site and species causing ringworm. As has been previously stated, topical therapies are used for localised or mild infections and oral treatment for extensive lesions, *tinea capitis*, *tinea unguium* and moccasin type of *tinea pedis*. Folliculitis is also an indication for oral treatment.

Tinea capitis

Tinea capitis is a childhood disease and can be challenging to treat. In order for therapy to be effective it must penetrate the hair follicles. Topical agents penetrate poorly but may help eradicate surface spores that may be shed into the environment.

Griseofulvin is the gold standard of treatment for *tinea capitis*. The recommendations of the Infectious Disease Committee of the American Academy of Paediatrics during the last decade reflect the increasing dosage and duration that may be required [40]. Dosage of 10 mg/kg/day microsize were previously considered effective, but nowadays most doctors use doses of 20 to

Table 6. Indications of topical treatment for dermatophyte infections.

- Non widespread limited lesions.
- Cases with interactions with oral antifungals.
- Patients non-compliant to systemic treatment.
- As adjunctive for systemic treatment.
- Prophylactic use to avoid recurrences after oral treatment.
- Patients in whom oral treatment is contraindicated.
- Pregnant or breastfeeding women.
- Attempts to shorten, improve or limit systemic antifungal treatment.

25 mg/kg/day for 6 to 8 weeks, and some patients require more prolonged therapy, particularly with *M. canis* [41].

Prolonged therapy increases the risk of non-compliance and some treatment failures may represent poor compliance [41]. Single-dose therapy (2 to 3 g) and intermittent dose schedules (25 mg/kg/twice a week) have also been used, particularly in the third world, in an attempt to reduce cost and increase compliance.

In cases of kerion, oral glucocorticoids may be given in an attempt to reduce scarring. Usually 1 mg/kg/day o.d. of prednisone is given for two weeks.

Terbinafine has been registered worldwide since 1991 [42]. In Europe since 1996 terbinafine has been licensed in several countries for the treatment of children, and most published studies of its use in the paediatric population have concentrated essentially on *tinea capitis* [43]. The dominant dermatophyte species in these studies were *Trichophyton violaceum* and *T. tonsurans*, for which there have been favourable clinical and mycological responses (93%) after the administration of terbinafine for 4 weeks at a daily dose dependent on body weight (62.5 mg for less than 20 kg; 125 mg. for 20-40 kg; 250 mg for more than 40 kg).

In the authors' clinical experience [44] and the published reports of others [45-47] there seems to be a lack of terbinafine efficacy in *M. canis tinea capitis*. This lack of terbinafine efficacy in *M. canis* seems to be neither native [48] nor secondary post-treatment resistance [47]. Other *Microsporium* spp. such as *M. audouinii* and *M. ferrugineum* seem also to be unresponsive clinically to terbinafine [49,50].

Thus, since *M. canis* is the predominant pathogen of scalp ringworm in Europe, North Africa and Middle East [51] we would not, on the basis of our experience and that of others [44-47,49,50,52], advocate the treatment of *Microsporium tinea capitis* with terbinafine. Further controlled studies will be required to confirm this. For young children terbinafine tablets may be split and hidden in food such a peanut butter. Crushing is not recommended because the formulation is not palatable.

Itraconazole is not yet licensed for the treatment of children and in the authors' experience has been found to match griseofulvin in therapeutic efficacy in *M. canis tinea capitis* in daily doses of 100 mg for 6 weeks [53]. Consequently itraconazole seems a reasonable second choice agent for children either not responding to adequate doses of griseofulvin or else showing signs of intolerance to this drug.

Itraconazole dosing recommendations vary. Elewsky [54] recommended 100 mg/day for patients weighting >60 lbs and 100 mg every other day for those weighting <60 lbs Itraconazole is available in capsule form and liquid formulation which contains cyclodextrin, and this last element raises concerns for its use in children because it has been shown to cause pancreatic adenocarcinoma in rats at human doses. Even though the significance of this is uncertain, its use in children still raises

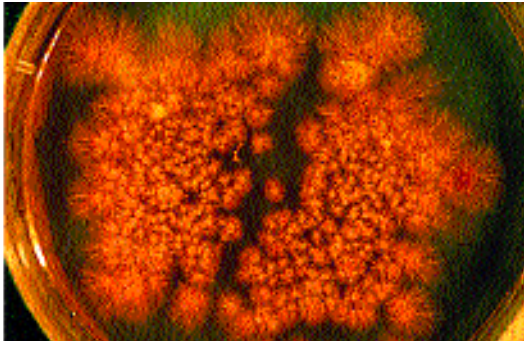


Figure 8. Massive semiquantitative culture from a patient with *T. tonsurans tinea capitis*.

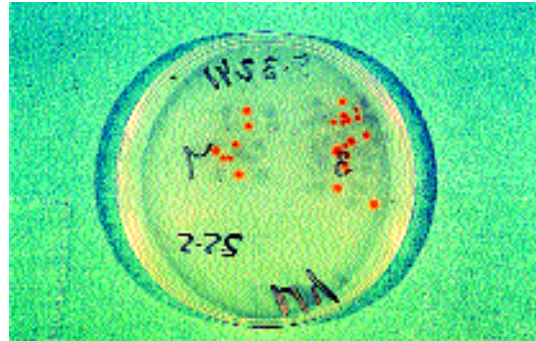


Figure 9. Asymptomatic carriage of *T. tonsurans* after treatment.

carcinogenetic concerns. The capsule formulation may be opened and mixed with food. Elewsky [55] has used itraconazole in 120 children with *T. tonsurans tinea capitis* unresponsive to griseofulvin, achieving in all of them a clinical and mycological cure. Gupta *et al.* [56-58] have investigated the efficacy of pulse therapy with itraconazole and terbinafine in children with *T. tonsurans* infections reporting 100% cure rate when 1 to 3 pulses of itraconazole were used and 92% cure rate with terbinafine. Gupta *et al.* note that the pulse-dosing format is a reasonable option, given pharmacokinetics of both drugs. They also state that pulse regimes allowed the physician to tailor therapy to individual patient response.

Fluconazole is available in both liquid and tablet form. Preliminary results are currently available in *T. tonsurans tinea capitis* [59,60], and there is no standardized dosing recommendation.

Finally a recent trial comparing short course terbinafine and itraconazole therapy has shown that a two week treatment with either drug provides cure rates in *T. tonsurans* infections of 64% and 59% respectively [61].

Controlled trials are warranted to establish the efficacy of the newer antifungal agents compared with griseofulvin, which is still the best. Safety and cost should also be considered as well as the risk and benefits of the new antifungal agents.

Recommendations for school attendance

The issue of keeping children off school remains controversial. Quoting Hay and Moore [62] the value of this measure in limiting spread has to be weighed carefully against its possible effect on compliance with surveillance and treatment, and this issue should be considered in conjunction with the local situation. In an outbreak in London, Hay [63] adopted the policy of advising treatment for all infected children with griseofulvin plus selenium sulphide or ketoconazole shampoo, to allow them to attend school once on treatment and to screen classes with scalp brushes if there were more than two children infected. Hay [62] maintains that with zoonophilic infections such as *M. canis*, children can be allowed to remain at school as infection from human to human is rare, which is in agreement with two published studies we did in Madrid [64,65].

However, the Committee on Infectious Diseases of the American Academy of Paediatric states: "children receiving treatment for *tinea capitis* may attend school. Haircuts, shaving of the head or wearing a cap during treatment is not necessary" [66,67].

Should asymptomatic scalp carriers be treated?

It is a well-known fact that dermatophytes can be cultured from the scalp of asymptomatic individuals follo-

wing oral treatment [44,62-65]. These carriers also appeared in the classes where index cases occur and also in household members [62-66]. Carriage may persist for as long as 8 months [44,63,66]. Carriers are a potential source of infection and play a part in the spread and persistence of *tinea capitis* in the community. According to Greer [68] and in the authors' clinical experience [64,65] quantitative scalp cultures should be done and, in cases with massive colony counts (Figure 8), topical treatment with ketoconazole shampoo should be implemented as well as in cases of carriage of *T. tonsurans* – even with low colony counts – due to the highly infectious nature of these species (Figure 9). Treatment with ketoconazole shampoo has the advantage of depositing itself on the scalp surface and adherence after rinsing, but its role in the eradication of asymptomatic carriage has not yet been addressed [66].

One question that still needs to be answered is the way in which viable spores may be removed from the environment, household and classrooms.

Tinea unguium

Onychomycosis, a fungal infection of the nail, is referred as *tinea unguium* when caused by dermatophytes. Onychomycoses are almost exclusively an adult malady (see Table 7). They require treatment since spontaneous cure is not possible (see Table 8). They represent a therapeutic challenge because they are a chronic condition and recalcitrant to treatment and for the dermatologist they represent the most difficult and problematic therapeutic problem of the superficial fungal infections.

Topical therapy for *tinea unguium* has poor results, except in superficial white onychomycosis due to dermatophytes, where it may be effective. Topical agents – 28% tioconazole, ciclopyroxolamine, amorolfine nail paint, bifonazole 1% in 40% urea cream under occlusive dressing – produce a low cure rate and remission [69,70]. Topical antifungals actually tend to be used in conjunction with oral antifungals, improving the clinical and mycological results of the latter [69-71].

Amorolfine is interesting because it is synergistic *in vitro* and *in vivo* in animal models when combined with oral antifungals (ketoconazole, itraconazole, terconazole and griseofulvin) [72]. This has also been shown in some clinical trials in patients [72].

Either surgical avulsion of nails or clinical removal using different preparations [69-71,73-76] combined with topical and oral antifungal agents, may either increase the cure rate of dermatophyte nail infections or shorten oral treatment.

Griseofulvin was the only oral antifungal available for the treatment of *tinea unguium* before the azole and

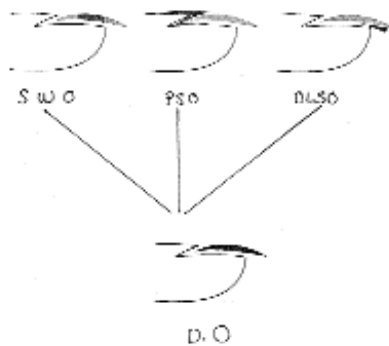


Table 7. Clinical forms of onychomycosis.

1. Superficial white onychomycosis (SWO):

T. mentagrophytes, *T. rubrum*, *Acremonium* spp., *Fusarium* spp., *Aspergillus* spp.

2. Proximal subungueal onychomycosis (PSO):

Candida, rarely dermatophytes, AIDS, recurrences of onychomycosis previously healed.

3. Distal and lateral subungueal onychomycosis (DLSSO):

Dermatophytes (typical), *Hendersonula*, *Scytalidium*, *Scopulariopsis brevicaulis*.

4. Dystrophic onychomycosis (DO):

Final stage of dermatophytes and chronic mucocutaneous candidosis.

allylamines were introduced. It had several drawbacks such as the need for long treatment courses (6 and 18 months for fingernails and toenails respectively), low clinical cure rates (less than 30% response) and high relapse rates (more than 40%) [69,70,77].

The new antifungal agents (itraconazole, fluconazole and terbinafine) possess pharmacokinetic characteristics and efficacy rates that have replaced griseofulvin for the treatment of fungal nail disorders. However, the treatment of onychomycosis is difficult and there is a high incidence of treatment failures and relapses. In a recent report, Roberts and Evans [78] highlight a phenomenon for which they have coined the term "subungueal dermatophytoma". It consists of a hyperkeratotic mass located in toenails. This mass does not adhere to the nail plate or the nail bed and can be readily removed. The histology of this mass shows a clump of dermatophyte hyphae. The consequence of this is that antifungal drug penetration is difficult and impaired and treatment measures should include podiatric removal of the lesion in order to improve drug penetration at the site of infection.

Both itraconazole and terbinafine incorporate in the nails and persist unchanged at a therapeutic level for at least six months after discontinuation of therapy when schedules of 12 weeks of treatment are used [69-71]. Either continuous therapy with itraconazole may be used (200 mg o.d. for three months) or pulse therapy (200 mg bid per month for three or four consecutive months) [79]. With this schedule, at the assessment nine months after treatment, 35% of patients achieved a complete clinical cure that persisted two years later [79]. An interesting conclusion of this report is that patients that have a small residual lesion of their nails nine months after treatment will have relapsed when assessed two years later and therefore the clinical criteria that should be used to assess the efficacy of itraconazole should be a total clinical cure nine months post-treatment [79]. Another report of Svejgaard *et al.* [80] gives a 40% clinical cure rate using continuous

Table 8. Reasons for treating onychomycosis.

- Spontaneous clinical cure is impossible.
- Without treatment onychomycosis worsens and spreads to other nails.
- They represent a fungal infection reservoir (important for epidemiological reasons for the community and for individuals with moccasin *tinea pedis*).
- Onychomycosis due to mycelial fungi (*Fusarium* spp) is a risk in immunocompromised patients and may be the point of entry of disseminated infections.
- They may facilitate episodes of cellulitis and thrombophlebitis.
- They may induce a Koebner response in patients with either lichen or psoriasis.
- In diabetic patients preexisting problems may worsen.
- They impair quality of life in elderly patients.
- A wide range of antifungal treatments are available at present.

itraconazole for three months and if three additional months of itraconazole are administered, the clinical and mycological efficacy does not increase.

Terbinafine schedules used are 250 mg daily given for six weeks for fingernails and 12 weeks for toenails.

A recent paper on a pharmacokinetic comparison of continuous and intermittent pulse itraconazole dosing schedules has two conclusions: intermittent therapy resulted in higher maximum itraconazole plasma concentrations but lower drug exposure, and hence lower itraconazole nail concentrations, than continuous therapy [81]. However, the intermittent schedule was not associated with a lower cure rate, which indicated that concentration of itraconazole in the nail remained within the therapeutic range. The total itraconazole dose given in pulse therapy is half that given in the continuous schedule, and this reduction in total drug intake may be beneficial in reducing any side effects and improving cost-effectiveness as well as in determining patients preference for treatment schedules [82,83].

Fingernail infections may be treated with 250 mg/day of terbinafine for 6 weeks, whilst toenails will require 12 weeks of therapy with the same dose. Using this regime 60% of fingernails and 40% of toenails achieved a clinical cure [84].

One double-blind study comparing the efficacy of continuous treatment with terbinafine and itraconazole in onychomycosis showed little difference in the clinical cure rate: 38% and 40% respectively [85].

Evans *et al.* [86] have shown in another comparative study that terbinafine 250 mg a day over 12 or 16 weeks produces better cure rates than intermittent itraconazole given over the same period. At week 72 the clinical cure was 54% (terbinafine 12 weeks), 60% (terbinafine 16 weeks) and 32% for itraconazole (three pulses and four pulses).

Fluconazole penetrates the nails through the matrix and nail bed and persists after twice-weekly doses for up to 6 months in toenails [87] and fingernails [88].

In a study of fingernail distal subungueal onychomycosis with once-weekly doses of fluconazole (150, 300 or 450 mg) for 2-9 months, there was a clinical response (cures + improvements) in 79%, 90% and 92% respectively [89].

In another study using 450 mg weekly, for the same indication, the clinical response (cures and improvements) was 14%, 23% and 37% when fluconazole was used for 4, 6 and 9 months respectively [90].

So far there have been no comparative studies published with fluconazole and more experience is needed. It is important to consider the pharmacoeconomic

Table 9. Important factors in choosing different treatment schedules in onychomycosis.

- *In vitro* antifungal spectrum.
- Pharmacokinetics and antifungal nail levels.
- Clinical efficacy (fingernails, toenails).
- Ratio risk/benefit.
- Treatment duration.
- Cost.
- Percentage of recurrence.
- Patients' individual preference.
- Infecting fungal species.
- Number of nails infected.
- Clinical nail extension (surface, percentage of nail involvement).
- Possible interactions with other drugs.

costs of oral antifungals [91] and the individual preference of the different treatment schedules by the patients [83].

Table 9 shows some of the factors important in choosing different treatment schedules.

Tinea cruris

Occlusion and moisture should be avoided. This condition occurs most commonly in men and is the second most frequent dermatophytosis.

In most cases, *tinea cruris* can be managed with topical treatment, but long established *T. rubrum* infections or cases in which there is follicular involvement require systemic treatment [92-98]. Relapses are more common with griseofulvin. Topical steroids are not recommended. Topical agents have a soothing effect, which will ease the local symptoms.

Butenafine is one of the latest topical antifungals introduced, and in *tinea cruris* with two weeks of treatment a cure rate around 70% may be expected [38]. Fluconazole (150 mg once weekly) for 4-6 weeks has proved to be effective in the management of *tinea cruris* and *tinea corporis*, since 74% of patients achieved a clinical cure [99]. The advantages of this regime include a potentially better patient compliance and lower costs [100].

Currently, itraconazole may be given as a dose of 400 mg/day given as two daily doses of 200 mg for one week, whilst a few years ago the treatment regime was 100 mg daily for two weeks.

Tinea barbae

Beard infections require oral and topical treatment for four to six weeks. Either itraconazole (100 mg daily) or terbinafine (250 mg) may be used [92-98].

Tinea corporis

For localised lesions of *tinea corporis*, topical treatment may be used; for widespread or inflammatory lesions (kerion) an oral treatment is indicated.

Topical imidazoles appeared to be highly effective, with cure rates of 80% [70,71,94,95]. Amorolfine and allylamines are another alternative [70,71,92,93]. The oral agent of first choice is griseofulvin (10 mg/kg/day) for four weeks [70,71]. Itraconazole and oral terbinafine or fluconazole may be reasonable oral alternatives given for 4-6 weeks [70,71,96,97,99,100]. In endemic areas or when the index case is a pet, reinfection may occur.

Tinea pedis

Treatment of *tinea pedis* varies depending upon the type and severity of the infection. Careful drying of the feet is also important. Occlusive footwear should be avoided and absorbent socks should be used. The patient

should be advised never to go barefoot in public showers, bathing facilities, locker rooms, etc.

Acute and chronic interdigital forms may be treated topically with imidazoles that have the advantage of being active also against resident gram positive bacteria that may cause secondary infections [101]. Imidazoles have to be applied daily for 3-6 weeks [93,95]. When gram negative bacteria are involved in *tinea pedis*, the use of topical imidazoles is generally ineffective [102]. In this case it is advisable to use antiseptics with a drying effect such as potassium permanganate solution or 20-30% aluminium chloride solution twice a day. In case there is microbiological evidence of bacterial cellulitis, an oral antibiotic should be administered. The allylamines (terbinafine and butenafine) may be used topically for shorter periods of time [36,37,39,103].

It is of interest that systemic therapy of interdigital *tinea pedis* with griseofulvin and ketoconazole is extremely disappointing because the mycological cure rate is low and recurrence of infection is common [104,105].

Oral terbinafine (250 mg/day) or itraconazole (100mg/day) used for two weeks may improve cure rates up to approximately 70% [106].

The problem of *tinea pedis interdigitalis* is that the rate of recurrence is extremely high, particularly in cases with *T. rubrum*. Antifungal powders may be used prophylactically in warm or humid weather.

Plantar or moccasin-type *tinea pedis* is a chronic "dry" type of dermatophyte infection, usually caused by *T. rubrum* [107]. Such infections require oral therapy. With griseofulvin long treatment periods are required and relapse rates are also high [107]. With triazoles and allylamines treatment duration has been reduced without compromising efficacy, and consequently has improved compliance of the patients. Hay *et al.* [108] have shown that two weeks treatment with terbinafine 250 mg/day is as effective as four weeks treatment with itraconazole 100 mg/day in patients with plantar *tinea pedis*.

Increasing the daily dose of oral itraconazole, Gupta *et al.* [109] have shown that 85% of patients achieved a clinical cure with 400 mg/day of itraconazole for a week. Another study of Tausch *et al.* [110] compared 400 mg/day of itraconazole for a week with terbinafine 250 mg/day for two weeks. There were no significant differences since 58% and 54% of patients were healed.

Over the last two years other choices for the treatment of this condition have been published. For instance, fluconazole administered for eight weeks with daily doses of 100 mg, produces good clinical results, although more clinical experience is warranted [111]. The problem again of dry type *tinea pedis* is the high relapse rate.

Vesicular forms of *tinea pedis* on the instep should be treated with both an oral and a topical antifungal agent. This form usually requires two weeks of oral treatment and topical medication for 4-6 weeks.

Tinea incognita

Oral therapy is indicated in dermatophyte infection modified by steroids (Figure 10). A weaker steroid than that originally used may be prescribed for two or three weeks in addition to oral antifungal treatment to avoid flare up.

Conclusions

At present the treatment of dermatophyte infections depends on a wide variety of topical and systemic compounds. For topical therapy numerous galenic forms are available, namely creams, tinctures, sprays, powders,

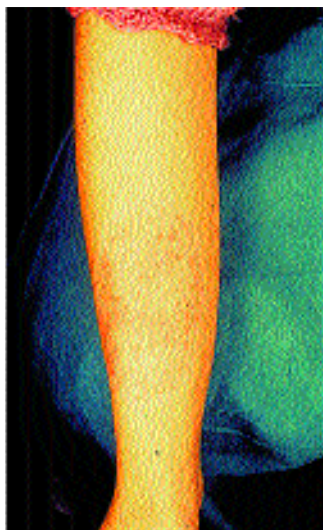


Figure 10. Ringworm modified by steroids (*tinea incognita*).

shampoos, ointments, lotions, nail paints and nail lacquers. The comparison of individual drugs is difficult, and almost 80% of dermatophyte infections will respond to one of the topical compounds, apart from, of course, *tinea unguium*. Few studies have compared the clinical activity of the different compounds and formulations in clinical trials. Topical treatments show a low incidence of adverse events. Often the choice of therapy is determined by the patients' acceptance of a proposed treatment schedule: this will improve patients' adherence to treatment.

The choice is smaller for systemic treatment of dermatophytosis: griseofulvin, itraconazole, terbinafine and fluconazole. Ketoconazole at present is not used due to its adverse effects when administered orally and a promising new drug is emerging: voriconazole.

Nowadays treatment schedules are shorter and easier, particularly with highly keratinophilic drugs such as itraconazole and terbinafine, that persist at therapeutic levels in skin and nails for a long time after therapy ends.

Reasons for failure are multiple and Table 10 shows several points the clinician must consider in coming to an adequate explanation. Clinical observation of each individual case is essential and mycological monitoring should be done before and after treatment.

Most published reports over the last two years on dermatophyte infections are papers on the use of itraconazole with the new formulation on cyclodextrin, treatment of onychomycosis with itraconazole, fluconazole and ter-

Table 10. Possible reasons of treatment failures.

Topical treatment

- Incorrect diagnosis of dermatophytosis. KOH and cultures are always necessary.
- The patient has not applied properly the topical treatment, or for the time prescribed (lack of compliance).
- Is the topical indication correct?

Oral treatment

- Incorrect diagnosis of dermatophytosis. KOH and cultures are always necessary.
- Has the patient been taking the oral treatment as prescribed by the doctor?
- Is the patient taking any competitive drug, or is the patient not absorbing adequately the antifungal?
- Is concomitant bacterial infection likely?
- Is there any underlying skin disease? (lichen, psoriasis, etc...)
- Is reinfection likely to occur?

binafine and studies on the epidemiology and treatment of *tinea capitis*. At present the management of onychomycosis is a challenge for the clinician. However, historically, treatment results have actually improved when they are compared with those achieved with griseofulvin, but are far from being ideal. In patients with all their nails involved, the rate of cure is 40%-60% for itraconazole and terbinafine respectively; fluconazole needs longer treatment periods and has lower rate of clinical success. In almost all published reports long term assessment is lacking and hence the recurrence rate of onychomycosis is not known.

In the management of *tinea capitis* the gold standard is griseofulvin, which is cheaper and has a favourable safety profile. It has a drawback: in some countries, as for instance in Spain, it is not available as a liquid formulation. Currently itraconazole is the choice for the treatment of *M. canis tinea capitis* unresponsive to griseofulvin or in patients with intolerance to the latter. Terbinafine is more expensive than griseofulvin and with the treatment schedule provided by the manufactures does not seem to be active for the management of *M. canis tinea capitis*.

The management of dermatophyte infections either in patients with AIDS or immunosuppression is still a challenge.

References

1. WHO. Guidelines for the diagnosis, prevention and control of dermatophytosis in man and animals. In: Mackenzie DWR, Loeffler W, Mantovani A, Fujikura T (Eds). CDS/VPH. 1986.
2. Elewski BE, Hazen PG. The superficial mycoses and the dermatophytes. *J Am Acad Dermatol* 1989; 21: 655-673.
3. De Vroey C. Epidemiology of ringworm (dermatophytosis). *Sem Dermatol* 1985; 4: 185-200.
4. Philpot CM. Geographic distribution of the dermatophytes: a review. *J Hyg* 1978; 80: 301-313.
5. Gentles JC. Experimental ringworm of guinea pigs: oral treatment with griseofulvin. *Nature* 1958; 182: 476-477.
6. Araujo OE, Flowers FP, King MM. Griseofulvin: a new look at an old drug. *DICP* 1990; 24: 851-854.
7. Gupta AK, Sander DN, Shear NH. Antifungal agents: an overview. Part I. *J Am Acad Dermatol* 1994; 30: 677-698.
8. Hatzis J, Tosca A, Varelzidis A, Stratigos J. The role of sweat in the pharmacokinetics of ketoconazole and griseofulvin. *Br J Dermatol* 1987; 117: 797-800.
9. Lewis JH, Zimmerman HJ, Benson GD, Ishak G. Hepatic injury associated with ketoconazole therapy: analysis of 33 cases. *Gastroenterology* 1984; 86: 503-513.
10. Haria M, Bryson HM, Goa KL. Itraconazole. A reappraisal of its pharmacological properties and therapeutic use in the management of superficial fungal infections. *Drugs* 1996; 51: 585-620.
11. Piérard GE, Arrese JE, Piérard-Frandrion C. Treatment and prophylaxis of tinea infections. *Drugs* 1996; 52: 209-224.
12. Gupta AK, Sander DN, Shear NH. Antifungal agents: an overview. Part II. *J Am Acad Dermatol* 1994; 30: 911-933.
13. Cauwenbergh G, Degreef H, Heykants J, Woestenborghs R, Van Rooy P, Haevarens K. Pharmacokinetic profile of orally administered itraconazole in human skin. *J Am Acad Dermatol* 1988; 18: 263-268.
14. Prentice AG, Warnock DW, Johnson SAN, Phillips MJ, Oliver DA. Multiple dose pharmacokinetics of an oral solution of itraconazole in autologous bone marrow transplant recipients. *J Antimicrob Chemother* 1994; 34: 247-252.
15. Anonymous. Voriconazole, UK-109496. *Drugs future* 1997; 22: 326-327.
16. Radford SA, Johnson EM, Warnock DW. In vitro studies of activity of voriconazole (UK-109496) a new triazole antifungal agent, against emerging and less common mold pathogens. *Antimicrob Ag Chemother* 1998; 41: 841-843.
17. Groll AH, Walsh TJ. Potential new antifungal agents. *Curr Op Infect Dis* 1997; 10: 449-458.
18. Espinel-Ingroff A, del Palacio A, Moore MK. A comparison of the in vitro activity for the new triazole voriconazole with dose of three established agents against dermatophytes and other molds. 38th Interscience Conference on Antimicrobial Agents and Chemotherapy. San Diego, CA 1998. Abstract J19a, pp 456.
19. Wildfeuer A, Seidl HP, Paule I, Haberreter A. In vitro evaluation of voriconazole against clinical isolates of yeasts, moulds and dermatophytes in comparison with itraconazole, ketoconazole, amphotericin B and griseofulvin. *Mycoses* 1997; 20: 309-319.
20. Balfour JA, Faulds D. Terbinafine: a review of its pharmacodynamic and pharmacokinetic properties, and therapeutic potential in superficial mycoses. *Drugs* 1992; 43: 259-284.
21. Leyden J. Pharmacokinetics and pharmacology of terbinafine and itraconazole. *J Am Acad Dermatol* 1998; 38 (Suppl 1): 42-47.
22. Faergemann J, Zehender H, Denoël J, Millerioux L. Levels of terbinafine in plasma, stratum corneum, dermis-epidermis (without stratum corneum), sebum, hair and nails during and after 250 mg terbinafine orally once per day for four weeks. *Acta Dermatol Venereol (Stockh)* 1993; 73: 305-309.
23. Amichai B, Grunwald H. Adverse drug reactions of the new oral antifungal agents-terbinafine, fluconazole and itraconazole. *Int J Dermatol* 1998; 37: 410-415.
24. Gupta AK, Lynde CW, Lauzon GJ, *et al.* Cutaneous adverse effects associated with terbinafine therapy: 10 case reports and a review of the literature. *Br J Dermatol* 1998; 138: 529-532.
25. Bong JL, Lucke TW, Evans CD. Persistent impairment of taste resulting from terbinafine. *Br J Dermatol* 1998; 139: 738-759.
26. Murphy M, Barnes L. Terbinafine-induced lupus erythematosus. *Br J Dermatol* 1998; 138: 706-723.
27. Gupta AK, Del Rosso JQ, Lynde CW, *et al.* Hepatitis associated with terbinafine therapy: three case reports and the review of the literature. *Clin Exp Dermatol* 1998; 23: 64-67.
28. Grunwald H, Amichai B. Thrombocytopenia associated with oral terbinafine. *Int J Dermatol* 1998; 37: 633-640.
29. Gupta AK, Gonder JR, Shear NH, Dilworth G. The development of green vision in association with terbinafine therapy. *Arch Dermatol* 1996; 132: 845-846.
30. Brodell RT, Elewski BE. Clinical pearl: antifungal drugs and drug interactions. *J Am Acad Dermatol* 1995; 33: 259-260.
31. Hay RJ. Risk/benefit ratio of modern antifungal therapy: focus on hepatic reactions. *J Am Acad Dermatol* 1993; 29: 550-554.
32. Chren MM. Cost of therapy for dermatophyte infections. *J Am Acad Dermatol* 1994; 31: 5103-5106.
33. Macasaet EN, Pert P. Topical (1%) solution of griseofulvin in the treatment of tinea corporis. *Br J Dermatol* 1991; 124: 110-111.
34. Rosen T, Schell JB, Orenge I. Anti-inflammatory activity of antifungal preparations. *Int J Dermatol* 1997; 36: 788-792.
35. Brennan BS, Leyden JJ. Overview of topical therapy for common superficial fungal infections and the role of new topical agents. *J Am Acad Dermatol* 1997; 36: S3-S8.
36. Tschen E, Elewski B, Gorserlowsky DC, *et al.* Treatment of interdigital tinea pedis with a 4-week once-daily regimen of butenafine hydrochloride 1% cream. *J Am Acad Dermatol* 1997; 36: S9-S14.
37. Savin R, De Villez RL, Elewski B, *et al.* One-week therapy with twice-daily butenafine 1% cream versus vehicle in the treatment of tinea pedis: A multicenter, double-blind trial. *J Am Acad Dermatol* 1997; 36: S15-S19.
38. Leshner JL, Babel DE, Stewart DE, *et al.* Butenafine 1% cream in the treatment of tinea cruris: a multicenter, vehicle controlled, double-blind trial. *J Am Acad Dermatol* 1997; 36: S20-S24.
39. Reyes BA, Beutner KR, Culler SI, *et al.* Butenafine, a fungicidal benzylamine derivative, used once daily for the treatment of interdigital tinea pedis. *Int J Dermatol* 1997; 37: 433-453.
40. Red Book. Report of the Committee on the Control of Infectious Diseases. Elk Grove Village, IL: American Academy of Pediatrics 1974, 1994, 1997.
41. Friedlander SF. The evolving role of itraconazole, fluconazole and terbinafine in the treatment of tinea capitis. *Pediatr Infect Dis J* 1999; 18: 205-210.
42. Hay RJ, del Palacio-Herranz A (Eds.) First Symposium on Terbinafine. *Clin Exp Dermatol* 1989; 14: 97-127.
43. Jones TC. Overview of the use of terbinafine (Lamisil) in children. *Br J Dermatol* 1995; 132: 683-689.
44. del Palacio A, Cuétara S, Valle A. Terbinafine (Lamisil) therapy for *Microsporum canis* scalp ringworm. *Clin Exp Dermatol* 1998; 23: 138-144.
45. Baudraz-Rosset F, Monod M, Joccoud S, *et al.* Efficacy of terbinafine treatment of tinea capitis varies according to the dermatophyte species. *Br J Dermatol* 1996; 135: 1011-1012.
46. Desgarennes CP, Godoy MR, Palencia AB. Therapeutic efficacy of terbinafine in the treatment of three children with tinea tonsurans. *J Am Acad Dermatol* 1996; 35: 114-116.
47. Bruckbauer HR, Hofman H. Systemic antifungal treatment of children with terbinafine. *Dermatology* 1997; 195: 134-135.
48. Clayton YM. In vitro activity of terbinafine. *Clin Exp Dermatol* 1989; 14: 101-103.
49. Kullavanhiya P, Ungpakorn R, Reangchainaman S. The problem in tinea capitis control in a home for mentally handicapped children. *Pediatr Dermatol* 1995; 1073: 95-97.
50. Kullavanhiya P, Reangchainaman S, Ungpakorn R. Randomized single-blind study of efficacy and tolerability of terbinafine in the treatment of tinea capitis. *J Am Acad Dermatol* 1997; 37: 272-273.
51. Elewski B. Tinea capitis. In: Elgart ML (Ed.) *Dermatol Clin*, Philadelphia, WB Saunders 1996; 14: 23-31.
52. Hamm H, Schwinn A, Bräutigam M, *et al.* Short duration treatment with terbinafine for tinea capitis caused by *Trichophyton* or *Microsporum* species. *Br J Dermatol* 1999; 140: 480-482.
53. López-Gómez S, del Palacio A, Van Cutsem J, *et al.* Itraconazole versus griseofulvin in the treatment of tinea capitis: A double-blind randomized study in children. *Int J Dermatol* 1994; 33: 743-747.
54. Elewski BE. Managing cutaneous mycoses in children. (Abstract Poster). Presented at the American Academy of Dermatology Summer Meeting, Chicago IL, August 1998.
55. Elewski BE. Treatment of tinea capitis with itraconazole. *Int J Dermatol* 1997; 36: 537-541.
56. Gupta AK, Adam P, de Doncker P. Itraconazole pulse therapy for tinea capitis: a novel treatment schedule. *Pediatr Dermatol* 1998; 15: 225-228.
57. Gupta AK, Alexis ME, Raboobee N, *et al.* Itraconazole pulse therapy is effective in the treatment of tinea capitis in children: an open multicenter study. *Br J Dermatol* 1997; 137: 251-254.
58. Gupta AK, Adam P. Terbinafine pulse therapy is effective in tinea capitis. *Pediatr Dermatol* 1998; 15: 56-58.
59. Solomon BA, Collins R, Sharma R, *et al.* Fluconazole for the treatment of tinea capitis in children. *J Am Acad Dermatol* 1997; 37: 274-275.
60. Mercurio MG, Silverman RA, Elewski BE. Tinea capitis: fluconazole in *Trichophyton tonsurans* infection. *Pediatr Dermatol* 1998; 15: 229-232.
61. Jahangir M, Hussain I, Hasan MU, *et al.* A double-blind, randomized, comparative trial of itraconazole versus terbinafine for 2 weeks in tinea capitis. *Br J Dermatol* 1998; 139: 672-674.
62. Hay RJ, Moore M. Therapy and management of ringworm infections. In: Champion RH, Burton JL, Burns DA, Breatnach SM (Eds.) *Textbook of Dermatology* (Rook, Wilkinson, Ebling). Oxford, Blackwell Science Ltd, 1998: 1324-1330.
63. Hay RJ, Clayton YM, De Silva N, *et al.* Tinea capitis in South East London—a new pattern of infection with public health implications. *Br J Dermatol* 1996; 135: 955-958.

64. Cuétara MS, del Palacio A, Pereiro M, *et al.* Prevalence of undetected tinea capitis in a school survey in Spain. *Mycoses* 1997; 40: 131-137.
65. Cuétara MS, del Palacio A, Pereiro M, *et al.* Prevalence of undetected tinea capitis in a prospective school survey in Madrid: emergence of new causative fungi. *Br J Dermatol* 1998; 138: 658-660.
66. Honig PJ. Tinea capitis: recommendations for school attendance. *Pediatr Infect Dis J* 1999; 18: 211-214.
67. Committee on Infectious Diseases. Tinea capitis. In: Peter G (Ed.) *Red Book: Report of the Committee on Infectious Diseases*. 24th ed. Chicago, American Academy of Pediatrics, 1997: 523-525.
68. Greer DL. Treatment of symptom-free carriers in management of tinea capitis. *Lancet* 1996; 348: 350-351.
69. Hay RJ. Onychomycosis. Agents of choice. *Dermat Clin* 1993; 11: 161-169.
70. del Palacio A, Cuétara MS, Castejón A. Avances en el tratamiento de onicomicosis y dermatofitosis. *Medicine* 1994; 6th ed; 24-36.
71. del Palacio A, Garau M, Tena D, Sánchez G. Tratamiento antifúngico: últimos avances en dermatología. *Rev Iberoam Micol* 1999; 16: 86-91.
72. Polak A. Antifungal therapy: an everlasting battle. Basingstoke, ICN Pharmaceuticals Ltd, 1999.
73. Baran R, Hay RJ. Partial surgical avulsion of the nail in onychomycosis. *Clin Exp Dermatol* 1985; 10: 413-418.
74. Dorn M, Kienitz T, Ryckmanns F. Onychomycosis: experience with non-traumatic nail avulsion. *Hautartz* 1980; 31: 30-34.
75. South DA, Farber E. Urea ointment in non-surgical avulsion of nail dystrophies, reappraisal. *Cutis* 1980; 21: 609-612.
76. Buselmeier FJ. Combination urea and salicylic acid ointment nail avulsion in one dystrophic nail: follow-up observation. *Cutis* 1980; 25: 393-396.
77. Korting HC, Schäfer-Korting M. Is tinea unguium still widely incurable? *Arch Dermatol* 1992; 128: 243-248.
78. Roberts DT, Evans EG. Subungueal dermatophytoma complicating dermatophyte onychomycosis. *Lancet* 1998; 138: 188-203.
79. Heikkilä H, Stubb S. Long term results of patients with onychomycosis treated with itraconazole. *Acta Derm Venereol (Stockh)* 1997; 77: 70-71.
80. Svejgaard EL, Brandrup F, Kragballe K, *et al.* Oral terbinafine in toe nail dermatophytosis. A double-blind, placebo controlled multicenter study with 12 months follow-up. *Acta Derm Venereol (Stockh)* 1997; 77: 66-69.
81. Havu V, Brandt H, Heikkilä H, *et al.* Continuous and intermittent itraconazole dosing schedules for the treatment of onychomycosis: a pharmacokinetic comparison. *Br J Dermatol* 1999; 140: 96-101.
82. Van Doorslaer EKA, Tormans G, Gupta AK, *et al.* Economic evaluation of antifungal agents in the treatment of toenail onychomycosis in Germany. *Dermatology* 1996; 193: 239-244.
83. Nolting SK, Sánchez-Carazo J, De Boule K, *et al.* Oral treatment schedules for onychomycosis: a study of patient preference. *Int J Dermatol* 1998; 37: 454-456.
84. de Backer M, de Keyser P, de Vroey, *et al.* A 12-week treatment for dermatophyte toe onychomycosis: terbinafine 250 mg/day vs itraconazole 200 mg/day - a double-blind comparative trial. *Br J Dermatol* 1996; 134 (Supl 46): 16-17.
85. Degreef H, del Palacio A, Myginds, *et al.* Randomized double-blind comparison of short-term itraconazole and terbinafine therapy for toenail onychomycosis. *Acta Dermatol Venereol* 1999; 79: 221-223.
86. Evans EG, Sigurgeirsson B. Double-blind randomised study of continuous terbinafine compared with intermittent itraconazole in treatment of toenail onychomycosis. *Br Med J* 1999; 318: 1031-1035.
87. Rich P, Scher RK, Breneman D, *et al.* Pharmacokinetics of three doses of once weekly fluconazole (150, 300 and 450 mg) in distal subungueal onychomycosis of the toenail. *J Am Acad Dermatol* 1998; 38: S103-S109.
88. Savin RC, Drake L, Babel D, *et al.* Pharmacokinetics of three once-weekly dosages of fluconazole (150, 300, or 450 mg) in distal subungueal onychomycosis of the fingernail. *J Am Acad Dermatol* 1998; 38: S110-S116.
89. Drake L, Babel D, Stewart D, *et al.* Once-weekly fluconazole (150, 300 or 450 mg) in the treatment of distal subungueal onychomycosis. *J Am Acad Dermatol* 1998; 38: S87-S94.
90. Ling MR, Swinyer LJ, Taylor Jarrat M, *et al.* Once weekly fluconazole (450 mg) for 4, 6 or 9 months of treatment for distal subungueal onychomycosis of the toenail. *J Am Acad Dermatol* 1998; 38: S95-S102.
91. Gupta AK. Pharmacoeconomic analysis of oral antifungal therapies used to treat dermatophyte onychomycosis of the toenails. *Pharmacoeconomics* 1998; 13: 1-15.
92. del Palacio A, López S, Gimeno C, *et al.* A randomized comparative study; amorolfine (cream 0.125, 0.25 and 0.5) in dermatomycoses. *J Dermatol Treat* 1991; 1: 299-303.
93. del Palacio-Hernanz A, López-Gómez S, Moreno-Palancar P, *et al.* A clinical double-blind trial comparing amorolfine cream 0.5% (RO-14-4767) with bifonazole cream 1% in the treatment of dermatomycoses. *Clin Exp Dermatol* 1989; 14: 141-144.
94. del Palacio A, Cuétara S, Rodríguez-Noriega A. Topical treatment of tinea corporis and tinea cruris with eberconazole (WAS 2160) cream 1% and 2%: a phase II dose-finding pilot study. *Mycoses* 1995; 38: 317-324.
95. del Palacio-Hernanz A, Cuétara S, Izquierdo I, *et al.* A double-blind, randomized comparative trial: flutrimazole 1% solution versus bifonazole 1% solution once daily in dermatomycoses. *Mycoses* 1995; 38: 395-403.
96. del Palacio-Hernanz A, López-Gómez S, González-Lastra F, *et al.* A comparative double-blind study of terbinafine (Lamisil) and griseofulvin in tinea corporis and tinea cruris. *Clin Exp Dermatol* 1990; 15: 210-216.
97. del Palacio A, Van Cutsem J, López S, *et al.* Estudio doble ciego randomizado comparativo con itraconazol y griseofulvina en tinea corporis y tinea cruris. *Rev Iberoam Micol* 1993; 10: 51-58.
98. del Palacio A, Van Cutsem J, López S, *et al.* Estudio doble ciego aleatorio comparativo con itraconazol y griseofulvina en tinea manuum y tinea pedis. *Actas Dermo-Sif* 1993; 84: 45-53.
99. Faergemann J, Mörk NJ, Haglund A. A multicentre (double-blind) comparative study to assess the safety and efficacy of fluconazole and griseofulvin in the treatment of tinea corporis and tinea cruris. *Br J Dermatol* 1997; 136: 575-577.
100. Nozickova M, Koudelkova V, Kulikova Z, *et al.* A comparison of the efficacy of oral fluconazole, 150 mg/day versus 50 mg/day, in the treatment of tinea corporis, tinea cruris, tinea pedis and cutaneous candidosis. *Int J Dermatol* 1998; 37: 701-708.
101. Kates SG, Myung KB, Mc Ginley KJ, *et al.* The antibacterial efficacy of econazole in interdigital toe web infections. *J Am Acad Dermatol* 1990; 22: 583-586.
102. Leyden JJ, Kligman AM. Interdigital athlete's foot: the interaction of dermatophytes and resident bacteria. *Arch Dermatol* 1978; 114: 1466-1472.
103. Evans EG. The clinical efficacy of terbinafine in the treatment of fungal infections of the skin. *Rev Comtemp Pharmacother* 1997; 8: 325-341.
104. Russell B, Frain Bell W, Stevenson CJ, *et al.* Chronic ringworm infection of the skin and nails treated with griseofulvin. Report of a therapeutic trial. *Lancet* 1960; i: 1141-1147.
105. Roberts DT, Cox NH, Gentles JC, *et al.* Comparison of ketoconazole and griseofulvin in the treatment of tinea pedis. *J Med Vet Mycol* 1987; 25: 347-350.
106. de Keyser P, de Backer M, Massart DL, *et al.* Two-week oral treatment of tinea pedis, comparing terbinafine (250 mg/day) with itraconazole (100 mg/day): a double blind multicenter study. *Br J Dermatol* 1994; 130 (Suppl. 43): 22-25.
107. Hay RJ. Chronic dermatophyte infections. I: Clinical and mycological features. *Br J Dermatol* 1982; 106: 1-7.
108. Hay RJ, Mc Gregor JM, Wuite J, *et al.* A comparison of 2 weeks of terbinafine 250 mg/day with 4 weeks of itraconazole 100 mg/day in plantar-type tinea pedis. *Br J Dermatol* 1995; 132: 604-608.
109. Gupta AK, de Doncker P, Heremans A, *et al.* Itraconazole for the treatment of tinea pedis: a dosage of 400 mg/day given for 1 week is similar in efficacy to 100 or 200 mg/day given for 2 to 4 weeks. *J Am Acad Dermatol* 1997; 36: 789-792.
110. Tausch I, Decroix J, Gwiedzinski Z, *et al.* Short term itraconazole versus terbinafine in the treatment of tinea pedis or manus. *Int J Dermatol* 1998; 37: 128-144.
111. Tanuma H, Doi M, Yaguchi A, *et al.* Efficacy of oral fluconazole in tinea pedis of the hyperkeratotic type. *Stratum corneum levels*. *Mycoses* 1998; 41: 153-162.