

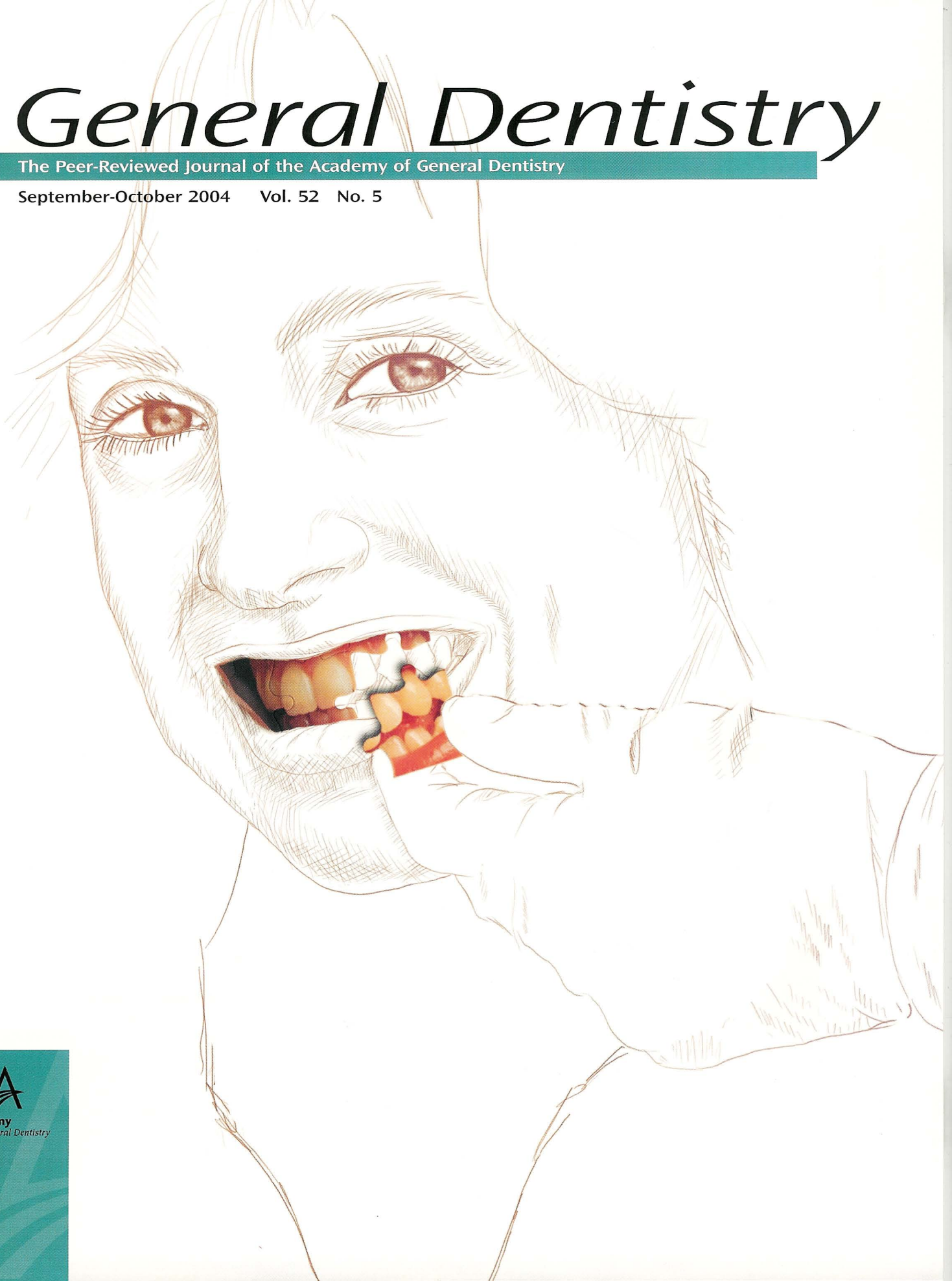
# General Dentistry

The Peer-Reviewed Journal of the Academy of General Dentistry

September-October 2004 Vol. 52 No. 5

Volume 52 Number 5

General Dentistry



[www.agd.org](http://www.agd.org)

Prosthodontics | Dental Materials | Laser Therapy | Oral & Maxillofacial Surgery

# Laser-assisted new attachment procedure in private practice

David M. Harris, PhD | Robert H. Gregg II, DDS | Delwin K. McCarthy, DDS | Leigh E. Colby, DDS | Lloyd V. Tilt, DDS, MS, PC

Three private dental practices conducted a retrospective analysis of patients receiving the laser-assisted new attachment procedure (LANAP). Retrospective results were compared to clinical trial data from the University of Texas Health Sciences Center in San Antonio (UTHSCSA) to determine if outcomes from a controlled clinical trial can be duplicated in private practice. Results also are compared with published results of other surgical and nonsurgical therapies for inflammatory periodontal disease.

Received: March 1, 2004

Accepted: April 19, 2004

It is estimated that approximately 4,500 surgical dental laser systems currently are installed in dental offices in the United States. In other words, approximately 3% of the 140,000 practicing dentists in the U.S. have access to dental laser systems; there may be another 10,000 systems worldwide.<sup>1</sup> The number of dentists who actually use lasers to treat inflammatory periodontal disease is unknown, although the numbers appear to be increasing steadily. This increase is surprising since only one university-based study of controlled clinical trials of laser sulcular debridement has been published.<sup>2,3</sup> That clinical trial, conducted in 1997 at the University of Texas Health Science Center at San Antonio (UTHSCSA), examined the efficacy and safety of using a pulsed Nd:YAG laser in the periodontal sulcus. In 1999, based on results from this study, American Dental Technologies received FDA market clearance to claim that laser sulcular debridement (also known as *laser curettage*) was clinically safe and improved clinical indices of periodontitis, including pocket depth reduction, attachment level gain, improved gingival index, and reduced bleeding index. Since then, several other laser companies have received similar FDA clearances.

The authors have performed laser-assisted new attachment procedures (LANAPs) on a case-by-case basis in private practices and have published four case reports to illustrate a typical range of results.<sup>4,6</sup> Since case reports can be misleading, this article presents a retrospective analysis of 42 patients who received LANAP at three independent private dental practices.

Pre- and post-treatment probing depths (obtained from patient records) were reviewed as the clinical index.

Investigations performed in clinical trials under standardized conditions should reflect optimal outcomes, which may not represent outcomes found in private practice settings. One common debate involves the general dentist's ability to reproduce published results on a predictable basis.<sup>7,8</sup> Unfortunately, there are few systematic studies with results from periodontal procedures performed in a private practice setting.<sup>9</sup> To address this issue, the retrospective results in this article are compared to the prospective clinical trials data collected at UTHSCSA. Results also are compared to published results involving other surgical and nonsurgical therapies.

## Methods and materials

LANAP is a step-by-step procedure developed within a practice setting specifically for treating moderate to advanced periodontitis. Patterned after the Excisional New Attachment Procedure (ENAP), LANAP is designed to remove diseased and necrotic tissue selectively from within the periodontal sulcus. However, the LANAP utilizes a free-running ( $10^{-6}$  seconds) pulsed Nd:YAG laser in place of a scalpel. Originally referred to as *Laser-ENAP*, LANAP has evolved to provide a minimally invasive alternative to flap surgeries.<sup>4,5</sup>

When the technique was developed to the point where positive and consistent results could be obtained, a training program was initiated to instruct other clinicians in the LANAP technique. A general dentist and a periodontist who completed a five-

day training program subsequently contributed patient records to this retrospective study (see Table 1).

## Pretreatment examination, hygienic phase

In keeping with the current standard of care, all patients initially are assessed with a medical history, charting plaque index, tooth mobility, and bleeding index. Probing depths are sampled at selected sites, pretreatment radiographs are evaluated, and indications for LANAP are determined. A periodontal maintenance program is initiated for each patient that includes initial supragingival scaling, instructions in personal oral hygiene, and follow-up hygiene visits scheduled at three-month intervals. Immediately before LANAP is performed, a 12 mm Perio-Probe (Marquis Dental Manufacturing Company, Aurora, CO; 800.359.3206) is used with 12–14 g of pressure to chart probing depths at six sites around all teeth. Treatment may be administered to specific sites, a single quadrant, or split-mouth (that is, right or left/upper or lower quadrants) but a single arch will not be treated in a single visit. The schedule depends on practice style and the severity of the disease. It is customary to allow 7–10 days between split-mouth treatments, although one center completed full-mouth LANAP within three days of starting.

## Dental laser systems

Three centers used the PerioLase free-running pulsed Nd:YAG laser (Millennium Dental Technologies, Inc., Cerritos, CA; 888.495.2737), emitting near-infrared radiation at a wavelength of 1,064 nm. The range of laser parameters available with these systems included two pulse durations: a short pulse of 150  $\mu$ sec and a long pulse of 635  $\mu$ sec. Pulses could be delivered with a repetition rate of 10–50 Hz and pulse amplitudes of 30–400 mJ. These settings are summarized clinically as average power in watts ( $W = J/sec$ ). Combinations of these laser settings produce an average

power range of 0.30–8.00 W. The laser energy is delivered via an optical fiber that is 320  $\mu\text{m}$  in diameter and terminates in a custom-made laser handpiece. Laser energy is emitted from the distal tip of the fiber in contact with the tissue.

Retrospective data of this study were compared with data from a controlled clinical trial in which a similar pulsed Nd:YAG laser (PulseMaster, American Dental Technologies, Inc., Corpus Christi, TX; 800.320.1050) was used. The PulseMaster had a similar fiber-optic delivery system, a single pulse duration of 100  $\mu\text{sec}$ , and maximum average power of 6.0 W.

### Laser-assisted new attachment procedure

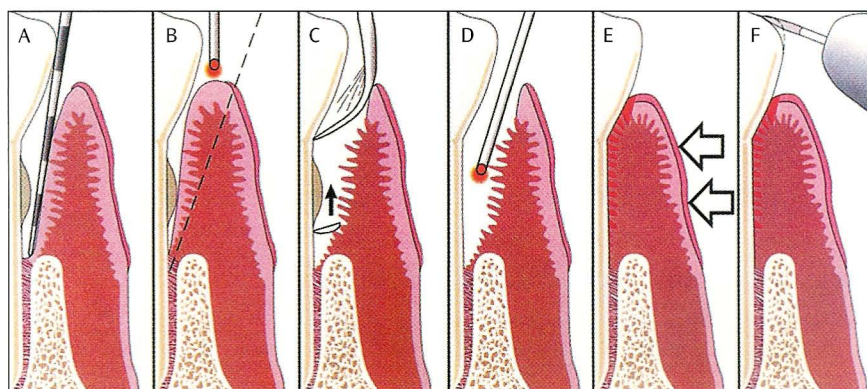
LANAP includes charting probe depths, local anesthesia, antibiotics, subgingival scaling and root planing (SRP), laser treatment, and occlusal adjustment (Fig. 1).<sup>3,5</sup> The first pass with the laser (referred to as *laser troughing*) is accomplished by using the short duration pulse. The laser settings varied among patients and investigators in practice, although a Molecron PM-600 power meter (Coherent Molecron, Portland, OR; 800.343.4912) measured that the PerioLase was within a range of 3.0–4.8 W to the tissue at all three study centers. The approximate lasing time was one minute per tooth and the total energy delivered (that is, the total light dose) was 10–15 J/mm of pocket depth.<sup>11</sup> Exceeding 3.0 W average power is not recommended except among experienced laser users.

Laser troughing affects sulcular debridement and de-epithelialization. It is executed by moving the fiber continuously, beginning at the gingival crest and working back and forth systematically, stepping down to the base of the pocket. As lasing continues, the epithelial lining of the pocket and necrotic debris accumulate on the fiber tip. The fiber is withdrawn from the pocket periodically and the coagulum is removed by wiping the tip with wet gauze. An endpoint is reached when debris no longer accumulates. With experience, the dentist also may notice changes in both the sound quality and the tactile feedback emitted on laser impact when the pocket has been debrided.

Following laser troughing, SRP is accomplished first by using a piezo-electric scalar (Piezon Master 400, Electro Medical Systems, Dallas, TX; 800.367.0367), fol-

**Table 1.** Sites contributing data to this retrospective study.

Center	Investigator(s)	Location	Laser utilized
CA	Gregg and McCarthy	Cerritos, CA	PerioLase
OR	Colby	Eugene, OR	PerioLase
UT	Tilt	Ogden, UT	PerioLase
UTHSCSA	Neill and Mellonig	San Antonio, TX	PulseMaster



**Fig. 1.** The clinical steps of LANAP, beginning with charting probe depths (A). The primary endpoint of LANAP is debridement of inflamed and infected connective tissue within the periodontal sulcus (B) and removal of calcified plaque and calculus adherent to the root surface (C). In addition, the bacteriocidal effects of the FR pulsed Nd:YAG laser plus intraoperative use of topical antibiotics are designed for the reduction of microbiotic pathogens (antiseptis) within the periodontal sulcus and surrounding tissues. A second pass with the 635  $\mu\text{sec}$  “long pulse” laser finishes debriding the pocket (D). Gingival tissue is compressed against the root surface to close the pocket and aid with formation and stabilization of a fibrin clot (E). The wound is stabilized, the teeth are splinted, and occlusal trauma is minimized to promote healing (F). Oral hygiene is stressed and continued periodontal maintenance is scheduled. No probing is performed for at least six months.

lowed by small curettes and root files for removing root surface accretions. Aggressive root planing is minimized. A second pass, using the PerioLase with the 635  $\mu\text{sec}$  “long pulse,” finishes debriding the pocket, completes removal of epithelial tissue, provides hemostasis, and creates a soft clot.

The gingival tissue is compressed against the root surface to close the pocket and to aid with formation and stabilization of a fibrin clot. Occlusal trauma is adjusted with a high-speed handpiece (when appropriate) and mobile teeth are splinted.

The primary goal of LANAP is debridement to remove pocket epithelium and underlying infected tissue within the periodontal pocket completely and to remove calcified plaque and calculus adherent to the root surface. The bacteriocidal effects of the pulsed Nd:YAG laser, the intraoperative use of topical chlorhexidine, and the postoperative use of antibiotic agents reduce microbiotic pathogens with-

in the periodontal sulcus and surrounding tissues.<sup>12-19</sup> At this point, the wound is stabilized and occlusal trauma is minimized to promote healing. Oral hygiene is stressed and continued periodontal maintenance is scheduled. Patients are contacted by phone within 24 hours and recalled for postsurgical evaluation after one week.

Patients are placed on a three-month periodontal maintenance program and a complete follow-up periodontal evaluation with probing is performed 6–12 months after the initial treatment. No periodontal probing was done within the first three months to avoid physically traumatizing nonmatured gingival attachments and disrupting the healing process. Teeth with pockets of 6.0 mm or more that exhibit inflammation (that is, a Gingival Index  $\geq 2.0$ ) may be retreated. Since data analysis for this report is restricted to pocket depth charting at the first follow-up interval, the probing depth changes

**Table 2.** Demographic summary of participants.

Center	CA	OR	UT	UTHSCSA	Total
<i>Sample size</i>					
Patients	8	14	20	10	52
Pockets $\geq$ 4.0 mm	860	702	1,099	171	2,832
<i>Gender</i>					
Male	4	6	5	3	18
Female	4	8	15	7	34
<i>Age</i>					
Mean	57.0	54.1	52.2	44.0	51.9
SD	6.7	7.7	12.7	7.1	10.4
Range	50–67	37–65	31–76	33–53	31–76
<i>Smoking history</i>					
No	6	13	12	—	31
Yes	2	1	8	—	11

**Table 3.** Pocket improvement at six months.

Center	Initial pocket depth (in mm)						Total
	4.0	5.0	6.0	7.0	8.0	9.0	
CA	(n = 237)	(n = 214)	(n = 223)	(n = 108)	(n = 47)	(n = 30)	(n = 860)
Yes	199	175	201	98	44	27	744
No	38	39	23	10	3	3	116
Rate (%)	84	82	90	91	94	90	87
OR	(n = 326)	(n = 185)	(n = 115)	(n = 41)	(n = 17)	(n = 18)	(n = 702)
Yes	276	170	110	41	16	18	631
No	50	15	5	0	1	0	71
Rate (%)	85	92	96	100	94	100	90
UT	(n = 448)	(n = 323)	(n = 239)	(n = 63)	(n = 23)	(n = 3)	(n = 1,099)
Yes	410	317	237	62	23	3	1,052
No	38	6	2	1	0	0	47
Rate (%)	92	98	99	98	100	100	96
UTHSCSA	(n = 50)	(n = 66)	(n = 24)	(n = 15)	(n = 10)	(n = 6)	(n = 171)
Yes	35	46	19	14	10	6	130
No	15	20	5	1	0	0	41
Rate (%)	70	70	79	93	100	100	76
Total	(n = 1,061)	(n = 788)	(n = 602)	(n = 227)	(n = 97)	(n = 57)	(n = 2,832)
Yes	920	708	567	215	93	54	2,557
No	141	80	35	12	4	3	275
Rate (%)	87	90	94	95	96	95	90

reported here are not influenced by the effects of retreatment.

#### UTHSCSA clinical protocol

The 1997 UTHSCSA study reported on 10 patients treated in a randomized, blinded, split-mouth design.<sup>2</sup> Protocol included oral hygiene, SRP, and laser sulcular debridement. Following a hygienic phase applied to all quadrants, three treatment methods—SRP alone, SRP plus laser, and

no treatment—were assigned at random to three quadrants; the fourth quadrant received SRP plus laser. Evaluators were blinded to the treatment method. A technique similar to LANAP was used, although laser parameters were constant: pulse duration was 100  $\mu$ sec, energy per pulse was 80 mJ, repetition rate was 25 Hz, and average power was 2.0 W. A dosimetry table defined a light dose based on pocket depth and ranged from 6.6–10.0 J/mm of

pocket depth. The UTHSCSA study used a lower average power than the LANAP; in addition, UTHSCSA did not utilize the 635  $\mu$ sec long pulse for a second pass.

#### Statistical analysis

In contrast to the UTHSCSA study, these data were collected within the environment of a private clinical practice and not as a controlled prospective study. Medical history, laser settings, laser dosimetry,

anesthesia, and clinical observations were obtained by reviewing patient records and the probing depths were recorded onto periodontal charts by the investigator or a hygienist at chairside.

Patients who had experienced LANAP in addition to at least two complete sets of probing depths (consisting of pretreatment and a first follow-up) were selected. Since retrospective follow-up data were not collected on a rigid schedule, the term *six months* was defined as an interval of more than 90 days but less than 10 months. Probing depth charts were examined by an independent transcriber and entered into an Excel spreadsheet; at that point, probe depth averages were computed per patient and per follow-up interval. Mean probing depth was computed as the arithmetic mean of all probing depths grouped by initial probing depth or by patient. Mean probing depth changes represent the mean of the differences from baseline to follow-up. To ensure consistency among data sets, original data from UTHSCSA data sheets were transcribed into the same spreadsheet program. The UTHSCSA follow-up was controlled at six months ( $\pm$  seven days).

Screening more than 200 patient records for inclusion criteria yielded 42 patients from three study centers with six-month follow-up data. Data from the UTHSCSA study was included for a total of 52 patients with 2,832 pockets with depths of 4.0 mm or more. Approximately one-third of the patients were male and 25% were smokers. Patients ranged in age from 31–76 with an overall mean of 52. Patients at UTHSCSA were approximately 10 years younger than patients from the other three institutions (see Table 2).

Demographic data were compared among centers using ANOVA and chi-square procedures. Data on individual pocket depths were obtained prior to laser treatment and again at the follow-up evaluation. Data were analyzed separately for each initial pocket depth at baseline and separated into two groups of pockets: 4.0–6.0 mm and  $\geq 7.0$  mm.

Data for the baseline pocket depth, follow-up depth, absolute change, and percentage change from baseline were summarized descriptively. For analysis purposes, change in percentage was utilized instead of absolute change due to

**Table 4.** Six-month comparison for 4.0–6.0 mm pockets.

Center	No. of pockets	Prior to treatment (in mm)	Six months (in mm)	Change (in mm)	Change (%)
CA ( <i>n</i> = 8)	626				
Mean (in mm)		4.66	3.19	1.47	30.70
Median (in mm)		4.00	3.00	1.00	25.00
SD		0.77	0.80	0.91	16.90
OR ( <i>n</i> = 14)	675				
Mean (in mm)		4.98	3.27	1.71	33.10
Median (in mm)		5.00	3.00	2.00	40.00
SD		0.83	1.25	1.38	25.10
UT ( <i>n</i> = 20)	1,010				
Mean (in mm)		4.79	3.09	1.47	34.40
Median (in mm)		5.00	3.00	2.00	33.30
SD		0.80	0.61	0.91	16.90
UTHSCSA ( <i>n</i> = 10)	140				
Mean (in mm)		4.81	3.69	1.12	23.20
Median (in mm)		5.00	4.00	1.00	25.00
SD		0.71	1.18	1.09	22.10

**Table 5.** Mean reduction (by percentage) of patients with 4.0–6.0 mm pockets at baseline.

Center	<10	10–19	20–29	30–39	$\geq 40$
CA	1	0	2	1	4
OR	0	2	4	6	2
UT	0	1	5	11	3
UTHSCSA	1	2	3	4	0
Total	2	5	14	22	9

the dependence between the amount of change and baseline value. For the two groups of pockets, study centers, number of patients in the center, and the number of pockets in patients were compared using ANOVA for a nested design. Because the patient was used as the unit of analysis, center differences were compared to the patient in center variation rather than the pocket variation. Center differences include differences between laser procedures (UTHSCSA vs. LANAP).

## Results

As would be expected, the mean pocket depth was reduced as the initial pocket depth increased (see Table 3).<sup>20–22</sup> Improvement rates ranged from 88% (for 4.0–6.0 mm pockets) to 96% (for pockets  $\geq 7.0$  mm).

Overall, 42 patients treated with LANAP had 2,311 pockets with initial probing depths of 4.0–6.0 mm that

showed least squares mean reduction of 32.7% (1.55 mm); at the six-month evaluation, 89.8% of these pockets had improved. There were 350 pockets of 7.0 mm or more among 37 LANAP patients; these pockets showed least squares mean reduction of 45.5% (3.44 mm) and 96.3% of these pockets showed improvement after six months.

All three of the study locations showed a greater mean improvement than UTHSCSA (see Tables 4–7). It appears that the UTHSCSA procedure (involving a single laser pass at lower power settings) might be less efficacious for these pocket depths.

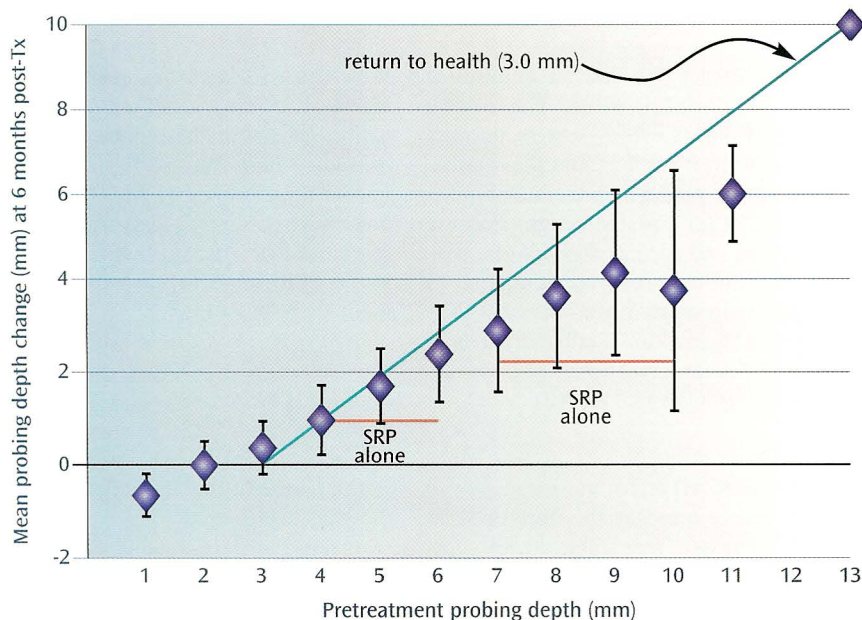
Overall differences among centers were insignificant statistically, among both 4.0–6.0 mm pockets ( $p = 0.601$ ) and pockets of 7.0 mm or more ( $p = 0.946$ ). In addition, the individual contrast comparing the two procedures also was not statistically significant for either the

**Table 6.** Six-month comparison for 7.0–9.0 mm pockets.

Center	No. of pockets	Prior to treatment (in mm)	Six months (in mm)	Change (in mm)	Change (%)
CA ( <i>n</i> = 8)	76				
Mean (in mm)		7.70	4.20	3.50	45.3
Median (in mm)		7.00	4.00	4.00	44.4
SD		0.83	1.33	1.41	17.2
OR ( <i>n</i> = 11)	183				
Mean (in mm)		7.58	4.14	3.44	45.2
Median (in mm)		7.00	4.00	4.00	50.0
SD		0.76	1.88	1.92	24.5
UT ( <i>n</i> = 18)	88				
Mean (in mm)		7.33	3.94	3.39	46.0
Median (in mm)		7.00	4.00	3.00	42.9
SD		0.54	1.08	1.16	14.8
UTHSCSA ( <i>n</i> = 6)	31				
Mean (in mm)		7.71	4.13	3.58	46.6
Median (in mm)		8.00	4.00	4.00	52.8
SD		0.78	1.73	1.65	21.5

**Table 7.** Mean reduction (by percentage) of patients with 7.0–9.0 mm pockets at baseline.

Center	<30	30–39	40–49	50–59	≥60
CA	1	1	1	5	0
OR	2	2	6	0	1
UTHSCSA	1	0	2	1	2
Total	7	6	14	12	7

**Fig. 2.** Mean probing depth changes ( $\pm 1.0$  SD) as a function of pretreatment probing depths.

4.0–6.0 mm group ( $p = 0.219$ ) or the group of 7.0 mm or more ( $p = 0.619$ ). The inability to identify differences between laser treatment protocols is due in part to the wide variability among patients, as seen by the mean improvement distribution among patients.

Only one patient failed to show an overall improvement in mean percentage change from pretreatment ( $-0.3$  mm). The patient's first evaluation was three months post-treatment; at a subsequent 18-month evaluation, the patient's mean probing depth change for all pockets of 4.0 mm or more was  $+1.2$  mm. Although a wide variability in results can be seen among patients, the results from pockets of 7.0 mm or more showed greater reductions (in percentage) than the 4.0–6.0 mm pockets. All patients showed overall mean improvement in measurements for these deep pockets.

At one center (OR), the height of the free gingival margin relative to the cemento-enamel junction (CEJ) was measured carefully to evaluate postoperative recession. No measurable recessions of gingival margins associated with laser-treated pockets were observed, a finding that is consistent with anecdotal observations from investigators at the other centers.

Because no significant differences were observed among centers, probing depths at six months were combined for the three centers that used the identical LANAP procedure (CA, OR, UT). Figure 2 and Table 8 show the average mean probing depths ( $SD \pm 1.0$ ) grouped for each initial pocket depth. The diagonal line in Figure 2 (labeled *return to health*) illustrates an ideal post-treatment pocket depth reduction to 3.0 mm. Figure 2 also includes estimates for pocket depth reductions that are expected following SRP alone in 4.0–6.0 mm and 7.0–9.0 mm pockets. These estimates indicate that LANAP is more efficacious than SRP alone.

## Discussion

In this study, pocket depths following laser treatment showed substantial improvements at follow-up. Mean probing depth is an accepted quantitative measure of a patient's periodontal disease. According to 1985 article by Aepli et al, a probing depth increase of more than 1.0 mm serves as a diagnostic test with high sensitivity and specificity.<sup>23</sup>

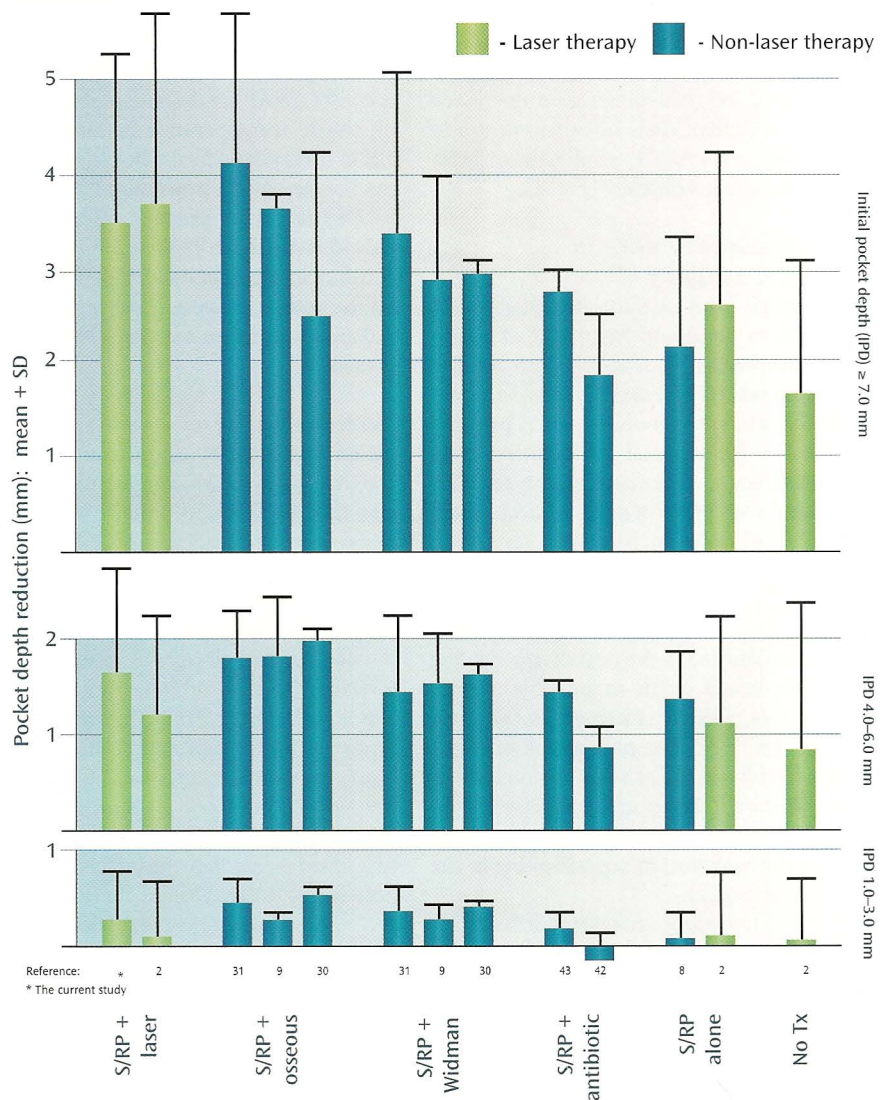
Results from the three independent centers using LANAP were similar. Although the UTHSCSA procedure was slightly less efficacious, there were no statistically significant differences among centers using LANAP compared with those using different laser procedures. Tests to determine significant differences between LANAP and the procedure used at UTHSCSA were limited because of the small sample size in the UTHSCSA study.

It is well-documented that inflammatory periodontal disease that goes untreated will result in a progressive increase in pocket depth, a loss of attachment, and, ultimately, a loss of dentition.<sup>24-27</sup> The mean annual progression rate of attachment loss is estimated to be 0.1–0.2 mm, although patient-to-patient and pocket-to-pocket variance within patients is considerable.<sup>8</sup> In the UTHSCSA study, the control quadrant that received no treatment showed improvement in all clinical indices. Mean pocket depth reductions from the UTHSCSA study for the No Treatment conditions are shown in Figure 3. The authors suggested that the no treatment improvement in a split-mouth experimental design is due to an overall reduction in gingival inflammation and also because of the heightened interest and oral hygiene compliance that results from participating in university-based clinical trials (this is known as the *Hawthorne effect*).<sup>2</sup> This points to another difference between the results obtained from a scientific study and what can be expected in a private practice.

The probing depth reductions computed from this retrospective data likely will be accompanied by attachment gains. Differences among centers were not significant; as a result, equivalent clinical outcomes between the PerioLase centers (CA, OR, UT) and the UTHSCSA study may be inferred. The UTHSCSA study reported statistically significant attachment level gains at six months after laser curettage. Yukna et al reported histologic evidence of reattachment and regeneration in a 2003 study in which six pockets (5.0–8.0 mm) were treated with LANAP and six with SRP alone. Teeth were extracted *en bloc* and examined histologically at three months post-treatment; at that time, all six laser-treated pockets demonstrated new cementum, new bone, and regenerated periodontal ligament, while five of the six

**Table 8.** Combined improvement by initial pocket depth, six months post-LANAP, from three centers utilizing laser periodontal therapy.

Initial pocket depth (in mm)	No. of pockets	Mean	SD	Range
1.0	6	-0.83	0.41	-1.0–0.0
2.0	374	0.03	0.48	-1.0–1.0
3.0	1,722	0.40	0.66	-4.0–2.0
4.0	1,011	1.05	0.67	-3.0–3.0
5.0	722	1.74	0.91	-4.0–4.0
6.0	578	2.56	1.09	-3.0–4.0
7.0	212	3.08	1.45	-2.0–6.0
8.0	87	3.79	1.69	-2.0–6.0
9.0	51	4.33	1.87	-3.0–7.0
10.0	6	3.83	2.64	-1.0–7.0
11.0	6	6.17	1.17	-5.0–8.0
12.0	0	-	-	-
13.0	1	10.00	-	-



**Fig. 3.** Comparison of surgical and nonsurgical modalities for treatment of inflammatory periodontal disease with different initial pocket depths.

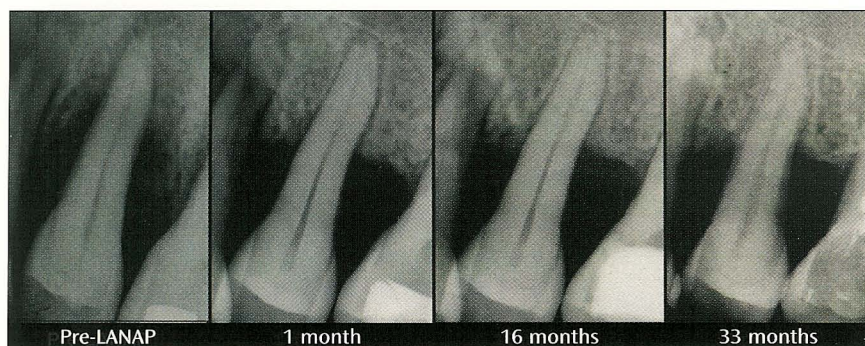

Fig. 4. A patient from the series with a bony defect. Note that resolution of the bony defect occurred at one month.

controls utilizing SRP alone demonstrated long junctional epithelium. Laser sulcular debridement also has been shown to improve clinical outcomes and reduce pocket depth reduction and attachment gain, including improved bleeding index, improved gingival index, and decreased tooth mobility.<sup>2</sup> It is not uncommon to observe post-LANAP resolution of bony defects radiographically (Fig. 4).

#### Laser surgery versus scalpel surgery

Thorough root surface debridement is critical to successful treatment of periodontal disease. It is difficult to remove subgingival plaque and calculus in pockets that are 5.0 mm or deeper. A primary objective for surgical intervention is to provide access and visualization for scaling and root planing of these deep pockets.<sup>29</sup> Traditional incisional surgery (such as a flap with osseous resection) results in reduced pocket depth due to apical repositioning of the gingival margin exposing the root surface to the oral cavity. Scalpel surgery could result in possible attachment loss, gingival cratering, and gingival recession.<sup>9,22,29-31</sup> The pain and discomfort associated with periodontal surgery is well-known.<sup>32</sup> By comparison, laser periodontal surgery eliminates pockets with minimal recession or repositioning of the gingival margin.

Laser troughing makes it possible to visualize and access the root surface by removing necrotic debris, releasing tissue tension, and controlling bleeding. It also defines tissue margins prior to ultrasonic and mechanical instrumentation, preserves the integrity of the mucosa, and aids in maintaining the free gingival crest.<sup>33</sup> This technique allows for selective

removal of sulcular or pocket epithelium while preserving connective fibrous tissues.<sup>33</sup> The hemostatic capability of intraoral laser surgery has been known and utilized for decades; to this end, the 1,064 nm wavelength and 635  $\mu$ sec "long pulse" used in LANAP are designed specifically to maximize intraoperative hemostasis and aid in therapeutic fibrin clot formation as the last step of the procedure.<sup>34,41</sup>

Dentists who practice laser sulcular debridement have reported high patient comfort and acceptance.<sup>33</sup> Neill presented the results of patient surveys and clinician-administered surveys in his 1997 thesis:

"All ten subjects were surveyed by the clinician immediately upon completion of the treatment appointment and then given a take-home questionnaire in order to assess the comfort levels over time. Results of the patient survey indicate that at three hours post-treatment, patients were comfortable, with half of the subjects reporting that they were extremely comfortable. The overall pain rating was 1.9 [on a scale of 0.0–10.0], indicating little to no pain was experienced. After twelve hours post-treatment, subjects reported improved comfort levels and little to no pain rated at 1.2. When asked if in the future they needed to undergo additional non-surgical periodontal therapy, which procedure they preferred, standard scaling and root planing or SRP plus laser, 8 out of 10 responses were in favor of the laser regimen. Subjects included in their written comments a perceived added benefit with the laser and their 'mouth felt cleaner' and less irritation and bleeding after the tooth scraping."<sup>33</sup>

Typically, statistically valid tests regarding differences among various studies are not possible due to differences in study designs; various modalities of periodontal therapy can be used to compare the results of laser procedures with those of clinical trials. Results of probing depth reductions from various studies reporting probing depth changes are plotted in Figure 3; results from clinical trials involving antibiotic therapies and SRP alone also are compared.<sup>8,9,30,31,42,43</sup> It is evident from this comparison that pocket depth reductions from LANAP are similar to those obtained from flap with osseous resection and modified Widman flap surgical procedures.

#### Conclusion

These data confirm the efficacy of laser sulcular debridement previously demonstrated in a university-based study. Post-operative LANAP probing results showed average probing depth reductions of 1.55 mm (32.7%) for 4.0–6.0 mm pockets and 3.44 mm (45.5%) for pockets of 7.0 mm or more. More than 90% of all pockets of 4.0 mm or more showed a decrease in probing depth at six months post-treatment. This retrospective analysis demonstrates that similar results obtained in a controlled randomized trial can be repeated in private practice and that those techniques can be transferred successfully to other dentists through sufficient training.

A common finding in clinical trials is the wide variability among patients in response to a specific therapeutic modality, which points to another major difference between clinical trial results and the application of a technique in private practice. In 1997, Cobb cautioned about extrapolating data from controlled studies for the private practice setting, noting that the choice of treatment modality should be decided on a site-to-site or patient-to-patient basis.<sup>8</sup> This choice is the difference between following a protocol and exercising clinical judgment to choose the appropriate therapeutic modality. Results from this study indicate that LANAP should be included as one of those choices.

#### Author information

Dr. Harris is an adjunct professor, Department of Preventive and Restorative



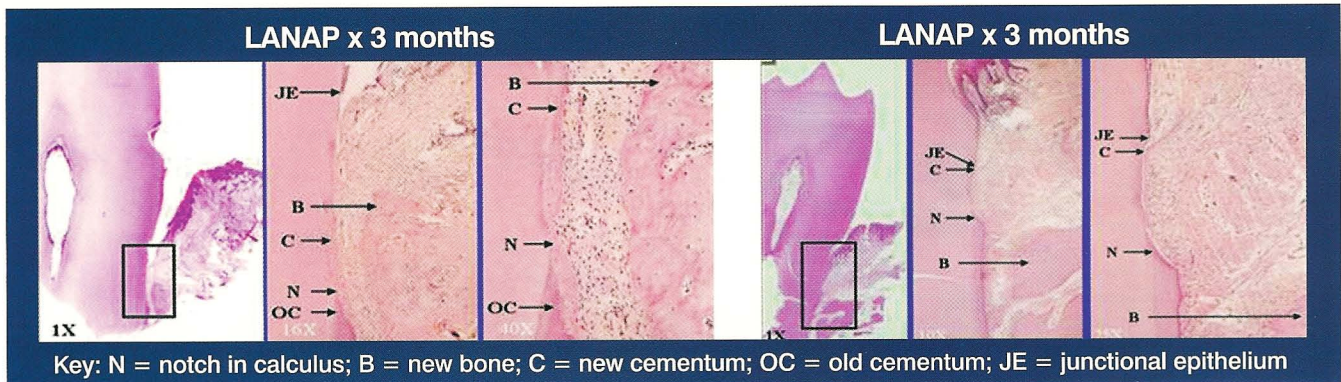
Dental Sciences, School of Dentistry, University of California in San Francisco and Director, Bio-medical Consultants, Inc. in Castro Valley, CA. Drs. Gregg and McCarthy are in private practice in Cerritos, CA. Dr. Colby is in private practice in Eugene, Oregon. Dr. Tilt is in private practice in Ogden, Utah.

## References

1. Personal communication with Terry Myers, DDS; Institute for Advanced Dental Technologies, Bloomfield, MI; October, 2003.
2. Neill ME, Mellonig JT. Clinical efficacy of the Nd:YAG laser for combination periodontitis therapy. *Pract Periodontics Aesthet Dent* 1997;9(6 Suppl):1-5.
3. Neill ME. Sulcular debridement and bacterial reduction with the PulseMaster Dental Laser: Clinical evaluation of the effects of pulsed Nd:YAG laser on periodontitis and periodontal pathogens [master's thesis]. San Antonio, TX: University of Texas Graduate School of Biomedical Sciences at San Antonio; 1997:123-125.
4. Gregg RH, McCarthy DK. Laser ENAP for periodontal ligament regeneration. *Dent Today* 1998;17:86-89.
5. Gregg RH, McCarthy DK. Laser ENAP for periodontal bone regeneration. *Dent Today* 1998;17:88-91.
6. Gregg RH 2nd, McCarthy DK. Laser periodontal therapy: Case reports. *Dent Today* 2001;20:74-81.
7. Greenstein G. Periodontal response to mechanical nonsurgical therapy: A review. *J Periodontol* 1992;63:118-130.
8. Cobb CM. Nonsurgical pocket therapy: Mechanical. *Ann Periodontol* 1996;1:443-490.
9. Becker W, Becker BE, Ochsenein C, Kerry G, Caffesse R, Morrison EC, Prichard J. A longitudinal study comparing scaling, osseous surgery, and modified Widman procedures. Results after one year. *J Periodontol* 1988;59:351-365.
10. Yukna RA, Bowers GM, Lawrence JJ, Fedi PF Jr. A clinical study of healing in humans following the excisional new attachment procedure. *J Periodontol* 1976;47:696-700.
11. Harris DM. Dosimetry for laser sulcular debridement. *Laser Surg Med* 2003;33:217-218.
12. Harris DM, Loomer PM. Ablation of *Porphyromonas gingivalis* *in vitro* with pulsed dental lasers [abstract]. *Am Assoc Dent Res* 2003; Abstract No. 855.
13. Moritz A, Schoop U, Goharkhay K, Jakolitsch S, Kluger W, Wernisch J, Sperr W. The bactericidal effect of Nd:YAG, Ho:YAG, and Er:YAG laser irradiation in the root canal: An *in vitro* comparison. *J Clin Laser Med Surg* 1999;17:161-164.
14. Henry CA, Dyer B, Wagner M, Judy M, Matthews JL. Phototoxicity of argon laser irradiation on biofilms of *Porphyromonas* and *Prevotella* species. *J Photochem Photobiol B* 1996;34:123-128.
15. Whitters CJ, MacFarlane TW, McKenzie D, Strang R, Moseley H. The bactericidal activity of pulsed Nd:YAG laser radiation *in vitro*. *Lasers Med Sci* 1994;9:297-303.
16. Morlock BJ, Pippin DJ, Cobb CM, Killoy WJ, Rapley JW. The effect of Nd:YAG laser exposure on root surfaces when used as an adjunct to root planing: An *in vitro* study. *J Periodontol* 1992;63:637-641.
17. Lin PP, Rosen S, Beck FM, Matsue M, Horton JE. A comparative effect of the Nd:YAG laser with root planing on subgingival anaerobes in periodontal pockets. *J Dent Res* 1992;71:299.
18. White JM, Goodis HE, Rose CL. Use of the pulsed Nd:YAG laser for intraoral soft tissue surgery. *Laser Surg Med* 1991;11:455-461.
19. Schultz RJ, Harvey GP, Fernandez-Beros ME, Krishnamurthy S, Rodriguez JE, Cabello F. Bacteriocidal effects of the Neodymium:YAG laser: *In vitro* study. *Lasers Surg Med* 1986;6:445-448.
20. Knowles JW, Burgett FG, Nissle RR, Shick RA, Morrison EC, Ramfjord SP. Results of periodontal treatment related to pocket depth and attachment level. Eight years. *J Periodontol* 1979;50:225-233.
21. Lindhe J, Socransky S, Nyman S, Haffajee A, Westfelt E. "Critical probing depths" in periodontal therapy. *J Clin Periodontol* 1982;9:323-336.
22. Pihlstrom BL, Ortiz-Campos C, McHugh RB. A randomized four-years study of periodontal therapy. *J Periodontol* 1981;52:227-242.
23. Aepli DM, Boen JR, Bandt CL. Measuring and interpreting increases in probing depth and attachment loss. *J Periodontol* 1985;56:262-264.
24. Lue H, Anerud A, Boysen H, Smith M. The natural history of periodontal disease in man. The rate of periodontal destruction before 40 years of age. *J Periodontol* 1978;49:607-620.
25. Becker W, Berg ML, Becker BE. Untreated periodontal disease: A longitudinal study. *J Periodontol* 1979;50:234-244.
26. Lindhe J, Haffajee AD, Socransky SS. Progression of periodontal disease in adult subjects in the absence of periodontal therapy. *J Clin Periodontol* 1983;10:433-442.
27. Buckley LA, Crowley MJ. A longitudinal study of untreated periodontal disease. *J Clin Periodontol* 1984;11:523-530.
28. Yukna RA, Evans GH, Vastardis S, Carr RF. Human periodontal regeneration laser-assisted new attachment procedure. *Int Assoc Dent Res* 2003; Abstract No. 2411.
29. Isidor F, Karring T, Attstrom R. The effect of root planing as compared to that of surgical treatment. *J Clin Periodontol* 1984;11:669-681.
30. Kaldahl WB, Kalkwarf KL, Patil KD, Dyer JK, Bates RE Jr. Evaluation of four modalities of periodontal therapy. Mean probing depth, probing attachment level, and recession changes. *J Periodontol* 1988;59:783-793.
31. Hill RW, Ramfjord SP, Morrison EC, Appleberry EA, Caffesse RG, Kerry GJ, Nissle RR. Four types of periodontal treatment compared over two years. *J Periodontol* 1981;52:655-662.
32. Curtis JW Jr, McLain JB, Hutchinson RA. The incidence and severity of complications and pain following periodontal surgery. *J Periodontol* 1985;56:597-601.
33. Gold SI, Vilardi MA. Pulsed laser beam effects on gingiva. *J Clin Periodontol* 1994;21:391-396.
34. Miserendino LJ, Pick RM. Lasers in dentistry. Chicago: Quintessence Publishing Co.; 1995.
35. Parrish JA. Photobiology and photomedicine. In: Martellucci S, Chester AN, eds. *Laser photobiology and photomedicine*. New York: Plenum Press; 1985.
36. Fuller T, ed. *Surgical lasers*. New York: Macmillan Publishing Co.; 1987.
37. Walsh JT Jr, Flotte TJ, Anderson RR, Deutsch TF. Pulsed CO<sub>2</sub> laser tissue ablation: Effect of tissue type and pulse duration on thermal damage. *Lasers Surg Med* 1988;8:108-118.
38. Harris DM, Bell TA, From L, Schachter D. Skin resurfacing with a very short pulsed CO<sub>2</sub> laser: Beam characterization and initial histological results. *SPIE Proceedings* 1996;2671:211-218.
39. Hobbs ER, Bailin PL, Wheeland RG, Ratz JL. Superpulsed lasers: Minimizing thermal damage with short duration, high irradiance pulses. *J Dermatol Surg Oncol* 1987;13:955-964.
40. Zweig AD, Meierhofer B, Muller OM, Mischler C, Romano V, Frenz M, Weber HP. Lateral thermal damage along pulsed laser incisions. *Lasers Surg Med* 1990;10:262-274.
41. Lanzafame RJ, Naim JO, Rogers MS, Hinchshaw JR. Comparison of continuous wave, chop-wave, and superpulse laser wounds. *Laser Surg Med* 1988;8:119.
42. Al-Joburi W, Quee TC, Lautar C, Iugovaz I, Bourgouin J, Delorme F, Chan EC. Effects of adjunctive treatment of periodontitis with tetracycline and spiramycin. *J Periodontol* 1989;60:533-539.
43. Loesche WJ, Schmidt E, Smith BA, Morrison EC, Caffesse R, Hujuel PP. Effects of metronidazole on periodontal treatment needs. *J Periodontol* 1991;62:247-257.

# “Cementum-mediated periodontal ligament new-attachment to the root surface in the absence of long junctional epithelium.”

(FDA 510k Clearance K030290)



Whether you look at the histology, or read the FDA Clearance – the clinical result is the same.

**Results beyond belief** - The Laser Assisted New Attachment Procedure (LANAP™), when used with the PerioLase® MVP-7™ dental laser, represents a breakthrough in the treatment of periodontal disease!

**For the General Practitioner** - you can obtain these same results and recapture the thousands of dollars per month you now refer out of your practice.

**For the Periodontist** – reduce double digit periodontal diseased pockets to healthy sulcus levels without the use of scalpel/suture surgery. Experience increased revenue from greater patient acceptance of this minimally invasive procedure.

**Don't wait - Call now:**

**1-888-49-LASER (888-495-2737)**


**or visit us at: [www.millenniumdental.com](http://www.millenniumdental.com).**

**Seeing is believing** – Do your due diligence on this ground breaking discovery.

- Read the Research Study “Laser Assisted New Attachment Procedure in Private Practice” in this publication.<sup>1</sup>
- Download the Clinical Study conducted by Dr. Ray Yukna, International Association for Dental Research, LSU School of Dentistry.<sup>2</sup>
- Attend one of our regularly scheduled Preview Sessions and obtain CE credits at the same time.
- Research Study, Clinical Study and Preview Session schedule can be obtained by accessing:

**[www.millenniumdental.com](http://www.millenniumdental.com)**

Predictable, reproducible, duplicatable, clinical results uniquely available every time using the PerioLase MVP-7.



**MILLENNIUM**  
DENTAL TECHNOLOGIES, INC.

*Millennium Dental Technologies is a company formed by clinicians, for clinicians.*

1. Harris DM, Gregg RH, McCarthy DK, Colby LE, Tilt LV. Laser-assisted new attachment procedure in private practice. J Gen Dent 2004;52:396-403.

2. Yukna RA, Evans GH, Vastardis S, Carr RF. Human periodontal regeneration following the laser-assisted new attachment procedure. Int Assoc Dent Res 2004;Abstract No. 2411.

Millennium, PerioLase®, MVP-7, Laser Assisted New Attachment Procedure, LANAP, are Trademarks of Millennium Dental Technologies, Inc. All Rights Reserved