

SECTION IX: BURN SCAR AND IT'S COMPLICATIONS

A. Overview

During the first 6 days, wound inflammation has begun and the various components of healing have been initiated. In superficial burns, epidermal regeneration will be relatively rapid, if the wound environment is optimized. The injured dermal elements are usually covered by new epithelium within 2 weeks. The hyperplasia of dermal fibroblasts then begins to resolve, and healing is complete with only modest amounts of collagen deposited. The wound usually becomes relative pliable with time and minimal wound contraction is seen. Cosmetically, the superficial second degree burn, which heals in 2 weeks, results in minimal to no long-term scarring.

If the healing takes 3 weeks as would be the case with a mid-dermal burn, scar is likely to be minimal except in higher risk groups, e.g. dark skin.

Post burn scar relative to re-epithelialization

- Healing in 2 weeks – minimal to no scar
- Healing in 3 weeks – minimal to no scar except in high risk scar formers
- Healing in 4 weeks or more – hypertrophic in more than 50% of patients

Post burn scar relative to skin graft

- Early grafting leads to less scar
- The thicker the skin graft, the less the scar
- Sheet grafts have less scar then meshed grafts
- The wider the mesh, the more the scar
- Scar will develop at the edges of a graft in high risk scar formers (dark skinned)

B) Biochemistry of Burn Scar

The biochemistry of the wound changes dramatically if it has not closed by 3 weeks or longer as would be the case of a healing deeper burn or a deep skin graft donor site.

Exaggeration of the inflammatory phase, in an open or infected burn, increases the concentration of growth factors known to produce increased fibroblast numbers and excess amounts of collagen and extracellular matrix.


Increased mast cells leads to increased release of histamine. Histamine is known to stimulate growth of fibrous tissue. Scar shows an increase in the thickness of the new epithelial layer but without rete pegs, making the surface vulnerable to injury. The keratinocytes becomes a factory for fibrotic growth factors. In addition, an excess and prolonged neovascularization is found in both types of scar compared to normal scar. Fibroblasts are also found in increased numbers, leading to increased collagen deposition as well as more matrix. These fibro-blasts are more sensitive to growth factors than normal skin fibroblasts. The released chondroitin develops sulfated side chains, which lead to a more rigid scar. Increased and persistent levels of chondroitin sulfate are present, located in the modular areas of excess collagen. This is characterized by increased water content, which increases scar firmness. A decrease in interferons, cytokines that downregulate collagen and matrix synthesis, is also noted. This abnormality leads to less collagenolysis and matrix degradation with remodeling.

The status of the wound bed will dictate the degree of surface inflammation. Increased surface and matrix metalloproteases oxidants and other mediators of inflammation result in a continued breakdown of new tissue and stimulate fibroplasia.

Causes of Excess Wound Inflammation

- Chronic open Wound
- Surface necrosis of desiccation
- Infection, increased bacterial burden

Excess collagen present in scar



Collagen bundles very dense with minimal matrix and tissue very non-pliable.

C) Hypertrophic Scar: Characteristics

Hypertrophic scar is an aberration of the normal healing process.

Hypertrophic scar occurs only in humans, making the study of pathogenesis and treatment more difficult. It occurs in males and females, being more common in the teenager or younger adult.

Hypertrophic scarring is seen in more than 50% of healed deep burns as just described.

The characteristics of proliferative or hypertrophic scar are shown in the list below. Proliferative scar is characteristically red, raised, rigid and painful. Itching is also universally present.

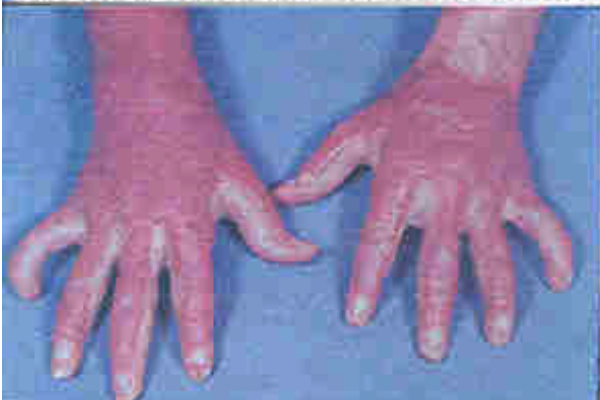Characteristics of Hypertrophic Burn

- Surface erythema
- Raised from wound surface
- Lack of elasticity
- Increased collagen
- Painful and itchy

The increased scar is particularly prominent around joints, where tension is more common.

Hypertrophic Burn Scar

Healed deep burn with hypertrophic scar.



Continued scar deposition in the re-epithelialized wound results in a raised, hyper-pruritic wound that produces functional impairment due to rigidity and pain as well as a severe cosmetic abnormality. Severe discomfort results. Pain with any

scar movement retards activity and continued itching leads to scratching and skin breakdown. Superficial infection of the skin breakdown can then result. The scar often splits with exercise, especially if it becomes dry. Grafted wounds develop much less hypertrophic scarring than the deep dermal burn that heals spontaneously. Both the contracture and hypertrophic scarring process peak between 3 and 6 months after injury, frequently long after the patient has been discharged.

Contracture formation and hypertrophic scarring peak 3 to 6 months after injury and partially resolve at 12 to 18 months.

It is crucial that the care providers recognize the delayed onset so that precautionary measures can be taken. The hypertrophic scar begins to decrease with time as collagen lysis begins to exceed the rate of deposition. The latter begins to decrease as the inflammatory process diminishes. Between 12 and 18 months, a softening and flattening of the scar can be seen along with a loss of scar hyperemia. The presence of a hyperemia indicates that active scar turnover is still present. The lack of hyperemia is a good sign that the scar is now mature and will remain in its present state, although the scar may relax. The underlying tissues can be permanently contracted.

Causes of Proliferative Burn Scar

- Tension on the wound
- Excess inflammation in wound bed
 - inflammatory stimulus
 - infection
- Wound open for more than 3 weeks
- Lack of dermal elements
- Genetic predisposition

D) Scar Assessment

There are a variety of methods to control and decrease scar formation, and in most patients, more than one approach is used. However, the assessment of the response of the scar process to the approach used is problematic as an accurate method for the objective quantitative assessment of scar remains to be developed.

Since scar is the sum of the response to injury repair, and intervention, the scar is not a static process, but rather a dynamic one changing over time, especially during the first 18 months or until healing is complete.

Subjective assessment includes various factors that contribute to the patient's own evaluation (visual and tactile contributions), which includes both perception and attitude (body image). Objective assessment includes the physical characteristics of size, shape, volume, color, texture, and probability. In addition, structural, mechanical and physiologic characteristics are included. The Vancouver Scar Scale is a commonly used method that attempts to quantify most of these parameters. Despite an attempt at objectivity, all objective markers are very much dependent on the examiner's expertise and perceptions, and assessment will vary considerably between different examiners.

Future approaches currently being tested include two-dimensional and three-dimensional imaging techniques and computer vision algorithms. A range scanner is a device that allows acquisition of 3-D data and can accurately estimate scar volume. This approach can also be used to assess pliability.

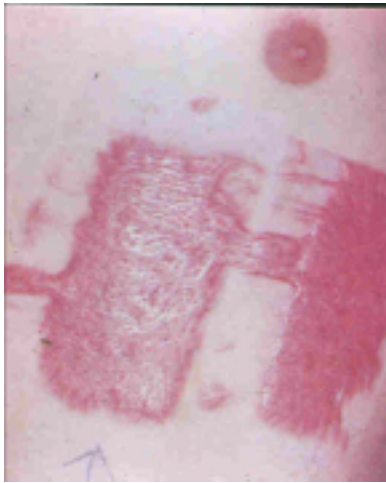Modified Vancouver Scar Scale

Pliability	0	Normal
	1	Supple
	2	Yielding
	3	Firm
	4	Adherent
Height	0	Normal
	1	1-2 mm
	2	3-4 mm
	3	5-6 mm
	4	>6 mm

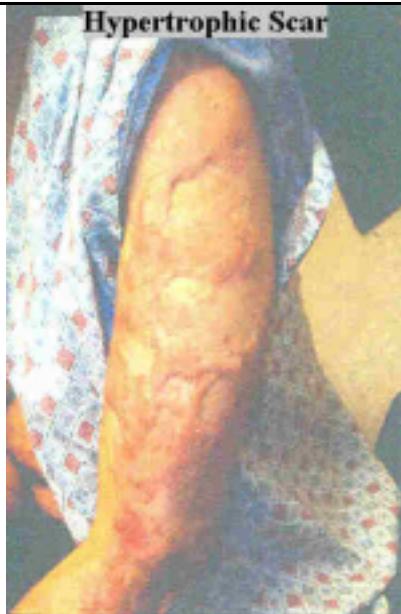Vascularity	0	Normal
	1	Pink
	2	Red
	3	Purple
Pigmentation	0	Normal
	1	Slightly _ / _
	2	Moderately _ /
	3	Severely _ / _

*Pain and itching are also assessed and documented usually using the 0-10 scale

Hypertrophic Scar on Donor Site

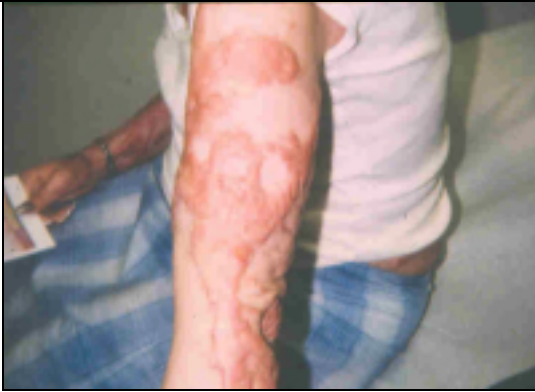

Delayed healing of donor site led to scar



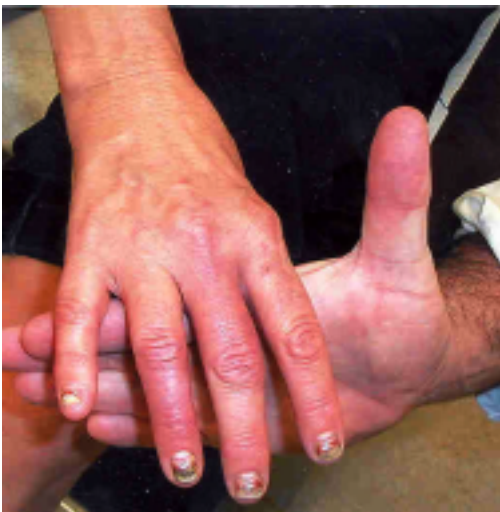Red and Raised

Maturing Scar (12 months)



Note scar is less red

Early Scar Formation (2 months)



Hand burn which healed in just over 3 weeks

Note beginning of red raised scar

E) Prevention of Hypertrophic Scar

Prevention is best achieved by early wound closure. Skin grafting should be the approach to a burn expected to take more than 3 weeks (high risk scar formers or 4 weeks to re-epithelialize). Temporary skin substitutes may be of benefit for decreasing scar in the partial thickness wound by increasing healing rate while protecting the wound. Permanent skin substitutes with a dermal component may be advantageous in the full thickness wound.

- Early wound closure
 - temporary skin substitutes
 - skin grafting
 - permanent skin substitutes
 - wound protection

It has been well established that a dermis containing active dermal elements is critical for the orchestration of a normal healing process, and the absence of dermal elements will lead to excess scar. The role of the dermis can be divided into its structural component and its biological messenger component.

The scaffolding or structure of the matrix, mainly collagen type I, is made up of the collagen fibres. The collagen lattice provides contact orientation for dividing and migrating cells (30-35). This cell-guidance system allows for a more organized, less abundant scar. Providing a collagen lattice onto the wound surface prior to scar formation allows for the ingrowth of a new matrix over time. The matrix orchestration system is composed of dermal proteins like fibronectin and growth factors, Hyaluronic acid, a complex carbohydrate and the glycosaminoglycan content.

A deep partial-thickness or full-thickness burn no longer has these key dermal elements. However, there are a number of collagen-matrix products now available which are designed to restore some of the dermal-like properties when placed on a clean full-thickness wound bed. The addition of these dermal-like properties should allow for a more normal healing process, thereby potentially decreasing scar. Providing a dermal-like layer to a full-thickness wound especially a wound, which is closing by secondary intent, should help to control scarring in cutaneous wounds, especially if the components maintain the biological activity of normal dermal elements. Several studies have demonstrated decreased scarring using some of the more novel matrix dressings.

F) Treatment of Hypertrophic Scar

1) Excisional Approaches

Excision is only feasible for a small scar. A simple excision of either an established hypertrophic scar or keloid has a very high recurrence rate (over 50%). The exception for hypertrophic scar appears to be tension-releasing procedures, e.g. z-plasties to release burn contractures of burn scar removal with tension-free closure where results are much better. Keloid recurrence also remains a major problem, although the addition of corticosteroids to the edges of the excision decreases recurrence. Therefore, surgical approaches to late scar need to be combined with other approaches.

Laser Surgery. This promising approach to both hypertrophic scar and keloids uses a laser beam to cause a thermal tissue reaction, which can heat the injury or coagulate specific tissues. The CO² and argon lasers are ineffective. However, the newer flash lamp-pumped pulse dye laser selectively decreases scar blood flow with a demonstrated improvement of more than 50% in over 50% of cases. A more pliable, less pruritic, and less erythematous scar results.

Cryotherapy. Comparable to laser therapy, cryotherapy results in microcirculatory disturbances leading to tissue damage, especially fibroblasts. Positive response is seen in 50% to 70% of patients, which is comparable to laser therapy. Treating early hypertrophic scars has the best results.

Typically, these surgical approaches are combined with other modalities, such as corticosteroids and other pharmacologic approaches and biophysical therapies like pressure, to optimize results.

2) Biophysical Therapeutics

The biophysical basis for therapeutic efficacy in scar management remains controversial, especially the relevance of abnormal biochemical pathways, and their pharmacologic modifications. However, these approaches have become the standard of care for hypertrophic scar control – both prevention and treatment. Keloids in general respond minimally to these approaches.

Compression

The use of fitted elastic garments to generate about 24 mm Hg on the hypertrophic scar was popularized more than 20 years ago, especially for burn scar. Pressure, if used 18-24 hours a day for at least 6 months, appears to have at least partial success in producing a thinner, more mature, and more pliable scar in over 50% of patients. The garments should be used as soon as the wound is closed. The pressure decreases scar blood flow, decreasing protein deposition, increasing lysis, decreasing edema and chondroitin sulfate. However, it is clear that the initial measured pressure lasts only for a very short time as tissue edema decreases, lessening the pressure. Yet a positive effect may persist. Recent theories include an increase in scar tissue temperature due to the tight garment weave. Increased temperature, even by 1°C, will significantly increase collagenolysis and scar maturation, thus the use of heating as a treatment modality.

Treatment Modalities
<ul style="list-style-type: none"> • Surgery Therapies <ul style="list-style-type: none"> -excision -laser -cryotherapy
<ul style="list-style-type: none"> • Biophysical Therapies <ul style="list-style-type: none"> -compression -ultrasonic, microwave heating -gel sheeting -scar massage
<ul style="list-style-type: none"> • Pharmacologic Therapy

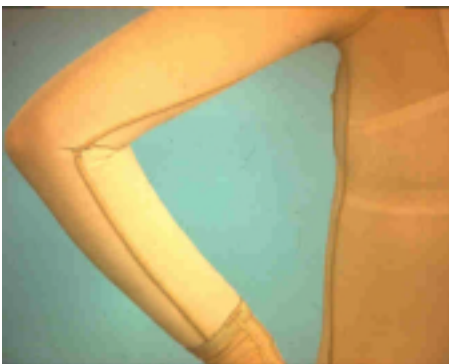-corticosteroids
-interferon
-protein kinase C
inhibitors

Measurements for Pressure Garments



Careful fitting is done to obtain correct pressure

Fitted Pressure Garment



To be worn 23 out of 24 hours a day

Ultrasonic or microwave heating

Used to soften scar and loosen still-stiff joints, ultrasonic or microwave heating decreases the tensile strength of a scar, and appears to reduce collagen content possibly by increasing collagenase activity; some benefit is seen in at least half the patients.

Gel Sheeting

Form-fitted silicone gel sheets held in place by elastics and worn at least 28 hours a day for several months also appear to increase scar maturation and decrease hypertrophy. Although the mechanism was initially thought to be due to pressure or increased temperature, neither appears to occur. Silicone itself is not playing a role as the same results occur with the use of a hydrogel. Current evidence suggests that maintaining scar hydration is the common element, although the effect of hydration on decreasing scar is unclear. However, the fitted sheet also takes tension off the wound, a known stimulant of scar. Early use has the best results.

Scar massage

This approach is usually combined with several other modalities. Deep massage reportedly stretches fresh scar and breaks down the cement or matrix holding the scar contracted. Massage therapy appears most beneficial in preventing contractures. However, massage also mechanically stimulates fibroblast synthesis of collagen. Therefore, this approach must be combined with an anticollagen synthesis approach to be of significant benefit.

Pharmacologic Therapy

Nonsteroidal anti-inflammatory agents have been shown to decrease fibrosis through inhibition of IL-1 and prostanoids, known to stimulate fibrosis. However, data verifying clinical efficacy in controlling excess scar are lacking.

Antihistamines have been shown to be effective not only in controlling pruritus, but also suppressing histamine-induced tissue proliferatives. Topical agents such as doxepin cream would likely be more effective as the concentration in the scar would be greater. In addition, doxepin (Prudoxin) is 800 times more potent than diphenhydramine as an antihistamine.

Some newer antiallergic drugs also inhibit the release of histamine and prostanoids from wound mast cells. These agents, except for some mild sedation, are very safe. Corticosteroids are, of course, used to control hypertrophic scar and keloids by injection into the scar itself. However, the corticosteroids, except for stabilizing mast cells, are not acting as an anti-inflammatory agent, but rather by inhibiting protein synthesis.

Corticosteroids are the main agent in the protein synthesis inhibitors category. These agents, when injected into scar, decrease fibroblast proliferation, decrease angiogenesis, and inhibit collagen synthesis and also extracellular matrix protein synthesis. Complications include pain on injection, thinning of surrounding skin if the steroid spreads to normal tissue, systemic absorption, and recurrence of scar at a later date.

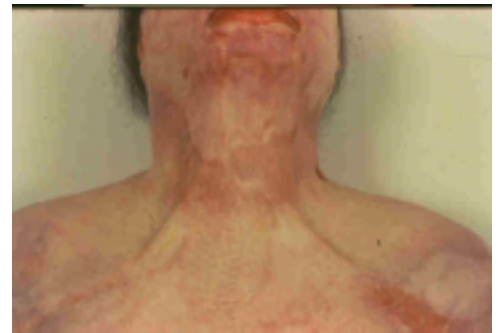Interferons are known to reduce the production of major scar forming growth factor TGF- β . Both intravenous and intralesion injections of interferon have shown significant clinical benefits on reducing hypertrophic scar and keloid. Popularity to date is hampered by high cost and unfamiliarity with this approach. Agents that inhibit collagen cross-linking would decrease scar rigidity and collagen deposition. The most promising agent in this category is topical putrescine, which has been reported to decrease hypertrophic scars with no side effects.

Stimulation of proteolytic enzyme synthesis works by increasing the degradation rate of collagen and matrix proteins. Calmodulin and protein kinase C inhibitors have been shown to be somewhat effective, but further data are needed. Calcium channel blockers inhibit the incorporation of protein into extracellular matrix protein. Several studies have reported an increased rate of scar degradation.

G) Burn Wound Contracture

Hypertrophic scar can lead to wound contracture if the scar crosses a joint. Contracture is the result of shortening of the hypertrophic scar with time.

Neck contracture



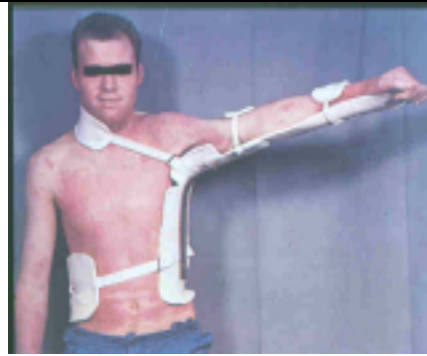Wound contraction develops. This is produced by the contractile myofibroblasts and the deposition of ground substance and collagen—end result is a shortened noncompliant wound that, if it crosses a joint, will result in contracture. The most common contractures are essentially identical to the most common position abnormalities produced with inadequate motion:

- Flexion: elbows, wrists, neck, interphalangeal joints
- Adduction: shoulder
- Extension: feet, metacarpophalangeal joints

Treatment

Active and Passive Exercise

- resistive
- stretching
- endurance
- ambulation



Splinting to maintain position of function

Positioning

-maintain position of function

Splinting

-maintain position

1. Su C, Aladeh K, Lee R. The problem scar. *Clin Plast Surg* 1998;25; 451.
2. Ladin DA, Garner WL, Smith DJ, jr. Excessive scarring as a consequence of healing. *Wound Repair Regener* 1994;3; 6-14.
3. Powers P, Sarkar S, Goldgaf D, et al. Scar assessment: current problems and future solutions. *J Burn Care Rehabil* 1999;20; 54-60.
4. Nessen F, Spauven P, Schalkwyk J, Kon M. On the nature of hypertrophic scars and keloids: a review. *Plast Reconstr Surg* 1999;104; 1440-1454.
5. Scott P, Ghahary A, Chambers M, et al. Biological basis of hypertrophic scarring. *Adv Structural Biol* 1994;3; 157-65.
6. Clark J, Cheng J, Leung F. Mechanical properties of normal skin and hypertrophic scars. *Burns* 1996;22; 443-446.
7. Ehrlich P, Desmouliere A, Diegelmann R, et al. Morphological and immunochemical differences between keloid and hypertrophic scar. *Am J Pathol* 1994;145; 105-113.
8. Nedelce B, Shankowsky, H, Tredget F. Rating the resolving hypertrophic scar; comparison of the Vancouver Scar Scale and Scar Volume. *J Burn Care Rehabil* 2000;21; 205-212.
9. Larabee W, Sutton D. A finite element model of skin deformity. *Laryngoscope* 1986; 96; 406-419.
10. Berman B, Bielek N. Adjunct therapies to surgical management of keloids. *Dermatol Surg* 1996;22; 126-130.
11. Car-Collins J. Pressure techniques for the prevention of hypertrophic scar. *Clin Plast Surg* 1992;19; 733-740.
12. Fulton J. Silicone gel sheeting for the prevention and management of evolving hypertrophic and keloid scars. *Dermatol Surg* 1995;21; 945-51.
13. Sawadow Y, Soni K. Hydration and occlusive therapy for hypertrophic scars and keloids. *Brit J Plast Surg* 1992;45; 599-603.
14. Shamberger R, Tabbot T, Tyripton H, et al. The effect of ultrasonic and thermal treatment on wounds. *Plast Reconstr Surg* 1981;68; 860-870.
15. Cohen J., Dregelmann R. The biology of keloid and hypertrophic scar and the influence of corticosteroids. *Clin Plast Surg* 1977;9;297-99.
16. Border WA, Noble NA. Mechanisms of disease: transforming growth factor β in tissue fibrosis. *N Engl J Med* 1993;331; 1286-1292.
17. Erlich HP, Krummel TM. Regulation of wound healing from a connective tissue perspective. *Wound Repair Regener* 1996;4; 203-210.
18. Farguhar K. Silicone gel and hypertrophic scar formation: a literature review. *Can J Occup Ther* 1992;59; 78-84.
19. Drake L, Fallon J, Sober A. Relief of pruritus in patients with atopic dermatitis after treatment with topical Doxepin. *J Am Acad Dermatol* 1994;31; 613-616.
20. Granstein R, Flotte T, Armento F. Interferons and collagen production. *J Invest Dermatol* 1990;95; 75-80.