

Review Articles

Differential Diagnosis and Management of Hallucinations

Leo P.W. Chiu

ABSTRACT

Hallucination is a common and serious symptom. It can be caused by many different physical and psychiatric disorders. This paper uses an algorithm to discuss how to distinguish hallucination from illusion, dream, pseudohallucination, and imagery. Then three algorithms for approaching patients with various types of hallucinations are described. Finally, a step-by-step strategy to manage hallucinations is discussed.

Keywords: Hallucination - Definition - Differential Diagnosis - Management

INTRODUCTION

Hallucination is a common symptom in both medicine and psychiatry. For example, the frequencies of auditory hallucinations in schizophrenia and acute organic brain syndrome are about 50% (1) and 15% (2) respectively, while the frequencies of visual hallucinations in these two disorders are about 10% (1) and 30% (2) respectively. Thus doctors of any specialty are likely to encounter some patients presenting with hallucinations in their practice.

Hallucination can be caused by many different physical and psychiatric disorders. Hence it is important to make an accurate diagnosis of the underlying disorders causing the hallucinations because different disorders may require very different managements.

Hallucination is also a serious symptom because it often signifies the presence of potentially fatal medical diseases like delirium tremens (3). More tragically, hallucinations themselves may kill patients directly by instructing patients to commit suicide. In a recent study of psychopathology of Chinese patients, the author (4) found that non-depressed psychiatric patients had suicidal ideas mostly because they were instructed by hallucinatory voices to kill themselves. Therefore, doctors should know how to manage hallucinations promptly and effectively.

The present paper reviews the definitions of hallucinations, discusses their differential diagnoses, and describes how to manage these phenomena.

DEFINITIONS

After teaching medical students as a university lecturer for some years, the author found that most medical students had difficulties in distinguishing among illusion, dream, imagery, hallucination, and pseudohallucination. Hence the author devised the algorithm shown in Fig. 1 to help students approach patients with perceptual disorders.

An illusion is a real (i.e. having actual external stimulus) perception distorted in some way (5). It can be a normal (e.g. misperceiving the outline of a bush as that of a man at dusk) or a morbid (e.g. delirious patient mistaking in-

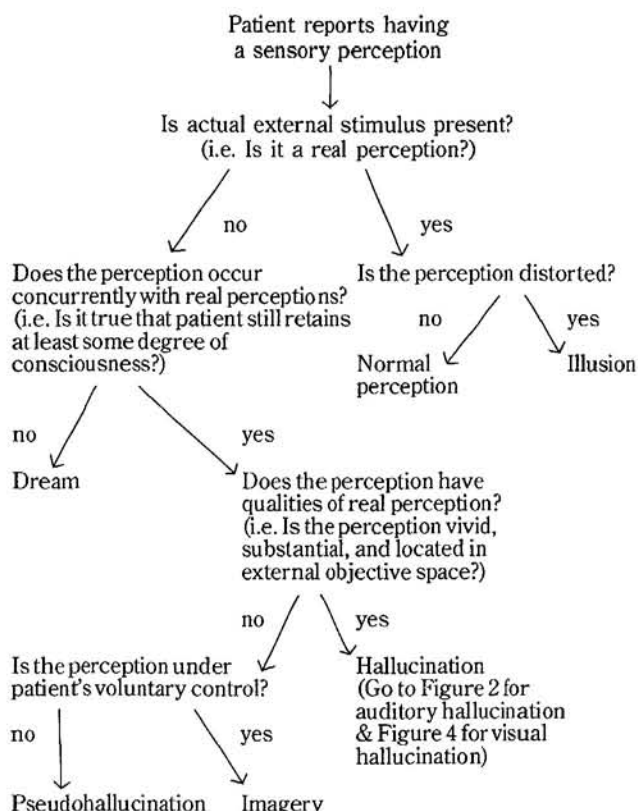


Fig. 1 Algorithm for approaching patients with perceptual disorders

Room 1406A, Sino Centre, 582-592 Nathan Road, Kowloon, Hong Kong
Leo P.W. Chiu, M.B.B.S. (H.K.), M.R.C.Psych. (U.K.), Psychiatrist in private practice
Correspondence to: Dr. Leo P.W. Chiu

animate objects for people) phenomenon. In the latter case, it frequently co-exists with hallucinations.

It is difficult to define hallucination in a satisfactory way. The American Psychiatric Association's Psychiatric Glossary (6) describes it simply as "a sensory perception in the absence of an actual external stimulus". Such a description can include dreams! If we exclude dreams by specifying that clear consciousness must be present, then hallucinations of delirious patients are left out! The author finds that the best definition was given by Mullen (7), who argued that hallucinations are involuntary false perceptions occurring concurrently with real perceptions (thus excluding dreams), and having qualities of real perceptions, i.e. vividness, substantiality, and location in external objective space. The commonest examples of hallucinations are hypnagogic and hypnopompic hallucinations, which occur at the onset of sleep or on waking respectively. They are usually normal phenomena but can occur in neuropsychiatric disorders like narcolepsy syndrome (8), chronic alcoholism, delirium (9), etc.

Pseudohallucination differs from true hallucination in that the former lacks the vivid, substantial qualities of a normal perception and occurs in internal subjective space. Hare (10) felt that the most important distinguishing point between true hallucinations and pseudohallucinations is the fact that only in the former is the patient convinced of the reality of his perceptions and expects other people present to be having the same experience. An example of pseudohallucination can be seen in the normal course of a bereavement reaction, when the bereaved person seems to see the deceased person or hear him talking.

Imagery differs from pseudohallucination in that the former is under voluntary control. Imagery is simply the recollection or conjuring up of a previous perceptual experience (11). It is a perfectly normal phenomenon. In fact, visual imagery can be used psychotherapeutically to recall repressed memories and affects. The author (12) has reported using visual imagery to successfully treat a patient with hysterical conversion disorder in a single session.

Hallucination can occur in each of our five senses (13) - auditory, visual, tactile, olfactory, and gustatory. The differential diagnoses of these five types of hallucinations are discussed in turn below, with emphasis on auditory and visual hallucinations because they are much more common (14).

DIFFERENTIAL DIAGNOSIS OF AUDITORY HALLUCINATIONS

The approach to patients with auditory hallucinations can be depicted by an algorithm as in Fig. 2.

Delirium is defined by the American Psychiatric Association's Psychiatric Glossary (6) as "an acute organic mental disorder characterised by confusion and altered, possibly fluctuating consciousness due to an alteration of cerebral metabolism". Auditory hallucinations in delirium are often combined with visual hallucinations. Cutting (2) found that common causes of delirium amongst general hospital in-patients in descending order of frequency were drugs, alcohol, carcinoma, pneumonia, epilepsy, heart failure, cerebrovascular accident, surgical operation,

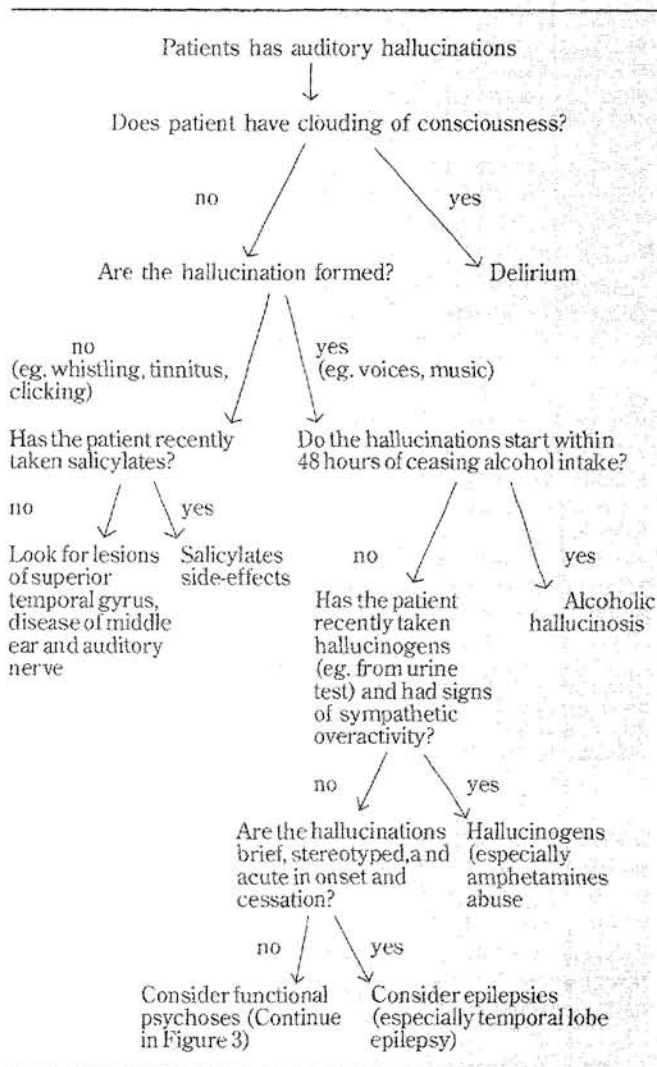


Fig. 2 Algorithm for approaching patients with auditory hallucinations

electrolyte imbalance, head injury, dementia, other causes. For any delirious patient, all of these possible causes should be thoroughly investigated and treated.

Simple (unformed) auditory hallucinations are usually caused by salicylates, lesions of the middle ear, auditory nerve, or superior temporal gyrus (primary auditory area). More complex (formed) hallucinations suggest involvement of the association areas of the temporal lobe.

Alcoholic hallucinosis is an organic hallucinosis in a clear sensorium with auditory hallucinations developing within 48 hours of ceasing alcohol intake (6). In 90% of cases, they stop within a week, but they continue as a chronic phenomenon in about 5%. These patients with chronic hallucinosis can be distinguished from chronic schizophrenics by having no schizoid premorbid personality and no family history of schizophrenia (15).

Hallucinogen-induced hallucinations are usually associated with signs of sympathetic overactivity (mydriasis, hypertension, tachycardia, sweating, and tremor) and remit within a week (14). Most hallucinogens or their metabolites can be detected in urine within 2 to 3 days after intake (16).

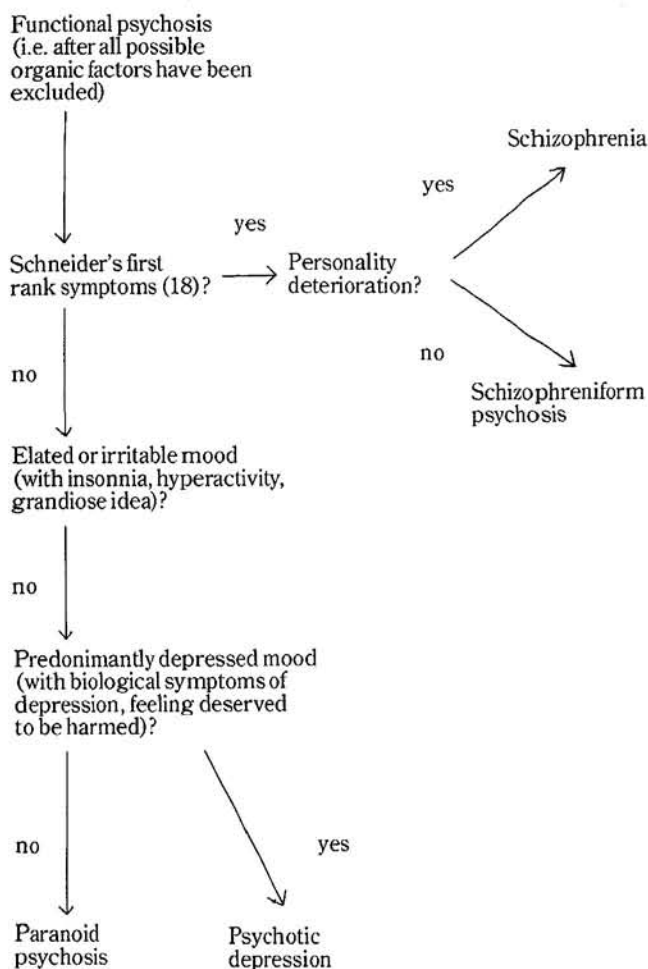


Fig. 3. Algorithm for diagnosing functional psychoses

If hallucinations are brief, stereotyped, and acute in onset and cessation, epilepsy should be suspected. When routine 20-minute electroencephalograms are inconclusive, 24-hour and/or sphenoidal electroencephalograms should be done.

How to diagnose psychiatric disorders in general has been discussed in detail by the author in another paper (17). Fig. 3 describes how to diagnose functional psychoses after all possible organic factors have been excluded. The diagnosis of schizophrenia and Schneider's first rank symptoms have been reviewed by the author in an earlier paper (18).

DIFFERENTIAL DIAGNOSIS OF VISUAL HALLUCINATIONS

The approach to patients with visual hallucinations can be depicted by another algorithm as in Fig. 4.

Delirium, hallucinogens, epilepsies, and functional psychoses have been discussed with reference to auditory hallucinations above.

A special type of delirium is delirium tremens, which is an acute and sometimes fatal brain disorder (in about one-fifth of untreated cases) developing in 24-96 hours after ceasing alcohol intake (6). In the early stages of delirium tremens,

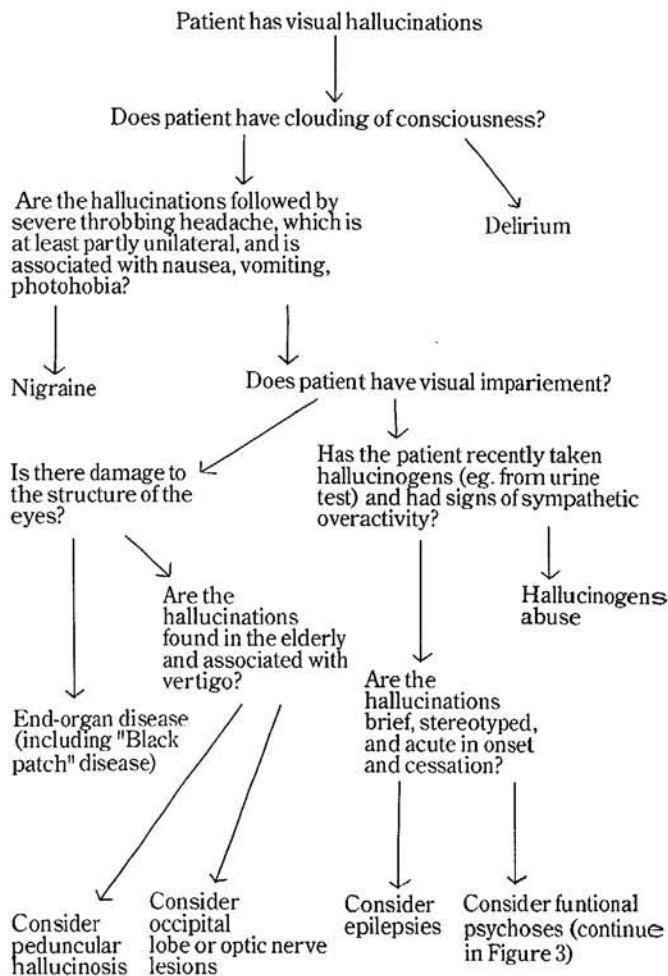


Fig. 4 Algorithm for approaching with visual hallucinations

the patient may experience an increase in dreaming, with nightmares and hypnagogic phenomena. The hallucinations vary in their content and may include complex scenes or Lilliputian hallucinations. Visions of rapidly moving small animals are particularly characteristic. Alcohol suppresses REM sleep and withdrawal leads to a rebound increase of REM activity. It is probably the intrusion of this REM activity into non-sleep periods that causes these perceptual abnormalities. The patient is usually frightened, agitated, ataxic, and grossly tremulous (hence the name "tremens"). The condition is often accompanied by nutritional deficiencies. It is a medical emergency that requires immediate treatment. The author has devised a mnemonic from A to I to memorise the management of delirium tremens: Anticonvulsants (only if the patient is having convulsions), vitamin B supplement, Chlordiazepoxide, Daily monitoring of vital signs, correction of Electrolyte imbalance, Fluid replacement, Glucose replacement, exclusion of Head trauma and Infection (3).

In migraine, the initial visual "aura" is due to cerebral vasoconstriction and the subsequent headache is due to vasodilation. The most typical aura, when the vasospasm involves branches of the internal carotid artery, is the fortification spectra. This is an irregular coloured crescent of light with multi-coloured edges, which develops close to

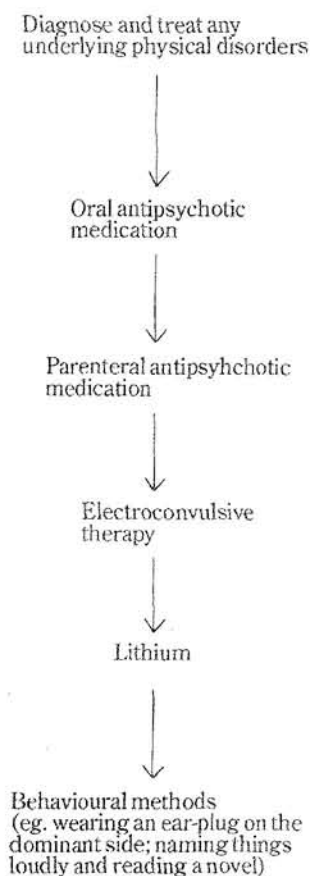


Fig. 5 A step-by-step strategy to manager hallucinations

the centre of the visual field, leaving an area of darkness in its wake. The progression lasts 15 to 30 minutes. Other visual phenomena in migraine include small bright dots (teichopsia) or large scotomata with scintillating edges (19).

Visual impairment suggests damage to the visual pathway. Damage to the structure of the eye (e.g. because of disease or surgery) can lead to simple or complex visual hallucinations. It is not clear how important a role cerebral impairment may play in predisposing the patient to hallucinate in many of these cases. However, in "black-patch" disease (post-operative delirium following cataract surgery), organic brain disease often appears to be present (20).

Occipital lobe or optic nerve lesions are often associated with a visual field defect and the hallucinations are "seen" in the "blind" area of vision. The hallucinations may be multiple, can last from seconds to hours, are recurrent, and may resemble "after-images" (persistence of an image after the responsible stimulus is no longer present) (21).

Lesions of the mid-brain tegmentum or in the region of the diencephalon can lead to peduncular hallucinosis. This condition typically involves vivid and complex hallucinations, e.g. detailed visions of people, animals, or landscapes, which are often "Lilliputian" in type. The hallucinations may last for years, are particularly found in the elderly, and are as-

sociated with vertigo and visual impairment. The cause of the latter symptom is not clear (22).

TACTILE, OLFATORY AND GUSTATORY HALLUCINATIONS

The commonest tactile hallucination is formication, a sensation that insects are crawling on the skin. It is usually associated with cocaine intoxication, especially after prolonged (over 6 months) intravenous use of cocaine, and typically occurs in clear consciousness. Other causes of tactile hallucinations include the belladonna alkaloids, choral, amphetamines, diabetes mellitus, hypophyseal tumour, brain damage, dementia, and hyperventilation (23).

Olfactory and gustatory hallucinations are common ictal phenomena in temporal lobe epilepsy and are usually experienced as unpleasant, unrecognisable.

Functional psychotic patients may experience bizarre tactile, olfactory, and/or gustatory hallucinations. Such hallucinations are usually related to patients' delusional thinkings. For example, a paranoid patient who deluded that neighbours were harming him with poisonous gas might actually experience olfactory hallucination of the gas.

MANAGEMENTS OF HALLUCINATIONS

The author proposes a step-by-step strategy to manage hallucinations as shown in Fig. 5.

The first step in the management of hallucinations should be to diagnose and treat any underlying physical disorders. Space does not permit discussion of managements of the various physical disorders mentioned in the present paper. Anyway, these managements have been detailed in any standard medicine or surgery textbooks. Hence the present paper concentrates on the management of hallucinations in functional psychoses.

Being psychotic symptoms, hallucinations should, of course, be treated with antipsychotic medication. It should be noted that all psychotropic medications are merely symptomatic treatment methods, i.e. aiming to remove only the symptoms but not the aetiologies of psychiatric disorders (17). Hence a depressed psychotic patient may need both antipsychotic drug for his psychotic symptoms and antidepressant drug for his depressive symptoms, regardless of whether the patient is given the label of schizophrenic, affective, or paranoid psychosis. In fact, review of the literature (24) confirms that patients with psychotic depression respond well to antipsychotic-antidepressant combination or electroconvulsive therapy but poorly to antidepressant alone. After patients' psychotic and affective symptoms have been controlled by medication, doctors should proceed to deal with the aetiological factors of patients' psychiatric disorders and rehabilitate patients' disabilities, as described by the author in another paper (17).

If patients' hallucinations do not respond to oral antipsychotic drugs, parenteral (including long-acting depot) antipsychotics should be tried. The latter have two advantages over the former: Firstly, from a recent study of Chinese schizophrenics, the author (25) found that over 80% of relapses of patients' illnesses were related to their poor drug compliance. Parenteral administration can minimize this compliance problem. Secondly, about three-quarters of an orally-administered dose of antipsychotic drugs are meta-

bolised by the liver (the so-called "first-pass effect") before the drugs can get into the systemic circulation. Parenteral administration can increase the bioavailability of medication by bypassing the liver (26).

The author (27) recently reports that acute dystonic side-effect of antipsychotic medication can actually aggravate patients' hallucinations. Hence it is advisable to start patients on a low initial dose of antipsychotics or a test dose of depot injection.

If patients' hallucinations do not respond to oral or parenteral antipsychotic medication, then we can proceed to electroconvulsive therapy (ECT). ECT-medication combination can cause faster recovery than medication alone not only in psychotic depression, but also in acute schizophrenia (28). The mechanism is not definitely known but a commonly held hypothesis is that ECT increases the permeability of the blood-brain barrier (28), enabling medication to enter the brain more easily.

When ECT-medication combination also fails, the remaining strategies are more controversial. The author found that lithium-antipsychotic combination is useful not only in manic patients, but also in some definitely schizophrenic patients. The use of lithium in schizophrenia has been reviewed by Delva and Letemendia (29). The mechanism of lithium-antipsychotic combination is not known. In treatment-resistant depression, the author (30) postulated that lithium may act by correcting a genetically-determined defect in cell-membrane enzyme activity. It is likely that similar mechanism may explain the effectiveness of lithium-antipsychotic combination in schizophrenics who are resistant to antipsychotics alone. One should be careful not to combine lithium concentrations greater than 1 mmol/litre with doses of haloperidol above 40 mg/day to avoid possible toxic encephalopathy (31).

Finally, when all physical treatment methods have failed, we can resort to psychological methods of treatment. The author (32) has recently reported successfully treating the auditory and visual hallucinations of an antipsychotic-resistant schizophrenic with two behavioural techniques: (a) asking the patient to wear a sound-occluding ear plug on the dominant side; (b) asking the patient to name things in her immediate environment loudly and to read a novel. The rationale is based on Green's theory (33), which suggests that schizophrenic hallucinations originate from mental activity in the non-dominant hemisphere and that the dominant hemisphere perceives this activity as alien due to a primary dissociation of the interhemispheric function. Hence if sensory input to the non-dominant hemisphere is reduced by an ear plug in the opposite ear, and activity of the dominant hemisphere is increased by naming things loudly and reading a novel, hallucinations can be disrupted.

CONCLUSION

For centuries, hallucinations have intrigued theologians, philosophers, and scientists. These phenomena have been thought to have magic power, partly because patients often die of underlying fatal diseases or kill themselves under the instruction of hallucinatory voices.

Today, we are still far from understanding the mechanisms of hallucinations. More importantly, we should continue to treat these phenomena with respect - by diagnosing the

underlying disorders correctly and by managing them promptly.

REFERENCES

1. World Health Organization. Report of the International Pilot Study of Schizophrenia. Vol.1, WHO, Geneva, 1973.
2. Cutting J. Physical illness and psychosis. *Br J Psych*, 1980; 136:109-119.
3. Lishman WA. *Organic psychiatry*. Blackwell, Oxford, 1978; 707.
4. Chiu LPW, Rimon R. Interrelationship of hypochondriacal, paranoid, depressive, and suicidal symptoms in Chinese psychiatric patients. *Psychopathology*, 1988; 21:38-43.
5. Jaspers K. *General psychopathology*. Translated by Hoening J and Hamilton MW. University Press, Manchester, 1963.
6. The American Psychiatric Association's Psychiatric Glossary. American Psychiatric Press, Washington, 1984.
7. Mullen P. The phenomenology of disordered mental function. In: Hill P, Murray R, Thorley A eds. *Essentials of postgraduate psychiatry*. Academic Press, London, 1979; 25-54.
8. Parkes JD. Narcolepsy. In: Riley TL, Roy A ed. *Pseudoseizures*. William and Wilkins, Baltimore, 1982; 62-82.
9. Lipowski ZJ. *Delirium*. Charles C. Thomas, Illinois, 1980.
10. Hare EH. A short note on pseudohallucinations. *Br J Psych*, 1973; 122:469-476.
11. Critchley EMR, Rossall CJ. Hallucinations. In: Crown S ed. *Practical psychiatry*. Vol. 1. Northwood, London, 1981; 21-25.
12. Chiu LPW, Yung CY. A single-session encounter with a patient with a conversion disorder. *Journal of Hong Kong Psychiatric Association*, 1986; 6:52-54.
13. Taylor K. Descriptive and developmental phenomena. In: Shepherd M, Zangwill OL ed. *Handbook of psychiatry*, Vol. 1. Cambridge University Press, Cambridge, 1983; 59-94.
14. Cavenar JO, Brodie HKH. *Signs and symptoms in psychiatry*. Lippincott, Philadelphia, 1983.
15. Victor M, Hope JM. The phenomenon of auditory hallucinations in chronic alcoholism. *Journal of Nervous and Mental Disorders*, 1958; 126:451-481.
16. Hyman SE. *Manual of psychiatric emergencies*. 2nd ed. Little Brown, Boston; 284.
17. Chiu LPW. A systematic approach to psychiatric patients. *The Hong Kong Practitioner*, 1989; 11(2):71-78.
18. Chiu LPW. Diagnosis and aetiology of schizophrenia: a synthesized view with implications for management and patient education. *J Hong Kong Med Assoc*, 1988; 40(2):145-150.
19. Gawel MJ. Migraine and cluster headaches. *Medicine North America*, 1983; 1:3007-3010.
20. Hamilton M. *Fish's clinical psychopathology*. Wright, Bristol, 1974.
21. Feldman M, Bender MB. Visual illusion and hallucinations in parieto-occipital lesions of the brain. In: Kemp K ed. *Origins and mechanisms of hallucinations*. Plenum Press, New York, 1970; 23-35.
22. Benson DF, Geschwind N. Psychiatric conditions associated with focal lesions of the central nervous system. In: Reiser MF ed. *American Handbook of psychiatry*, Vol. 4. Basic Books, New York, 1975; 208-243.
23. Berrios GE. Tactile hallucinations: conceptual and historical aspects. *Journal of Neurology, Neurosurgery and Psychiatry*, 1982; 45:285-293.
24. Leonard BE. Biochemical aspects of therapy-resistant depression. *Br J Psych*, 1988; 152:453-459.
25. Chiu LPW. Educating Chinese schizophrenic patients about their illness. *Hong Kong Journal of Mental Health*, 1987; 16(1):6-13.
26. Johnson DAW. The long-acting depot neuroleptics. In: Granville-Grossman K ed. *Advances in clinical psychiatry*, Vol. 4. Churchill Livingstone, Edinburgh, 1982; 243-260.
27. Chiu LPW. Transient recurrence of auditory hallucinations during acute dystonia: a report of three cases. *Br J Psych*, 1989; 55:110-113.
28. Palmer RL. *Electroconvulsive therapy: an appraisal*. Oxford University Press, Oxford, 1981.
29. Delva NJ, Letemendia FJJ. Lithium treatment in schizophrenia and schizoaffective disorders. In: Kerr A, Snaith P ed. *Contemporary issues in schizophrenia*. Gaskell, London, 1986; 381-396.

Review Articles : Differential Diagnosis and Management of Hallucinations

30. Chui LPW. Response to clomipramine after short course of lithium in treatment-resistant depression: does lithium have a "priming" effect? *Human Psychopharmacology*, 1987; 2:191-193.
31. Loudon JB, Waring H. Toxic reactions to lithium and haloperidol. *Lancet*, 1976; 11:1088.
32. Chiu LPW, Putkonen AR, Rimón R. Control of auditory and visual hallucinations using two behavioural techniques: a case report. *Psychiatria Fennica*, Vol. 19, 1988; 75-85.
33. Green WP. Defective interhemispheric transfer in schizophrenia. *Journal of Abnormal Psychology*, 1978; 87:472-480.