

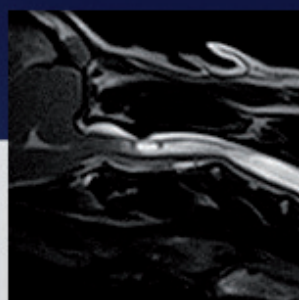
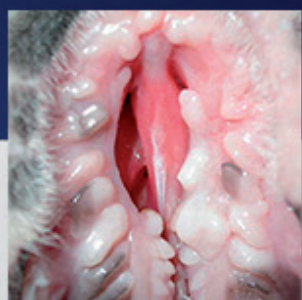
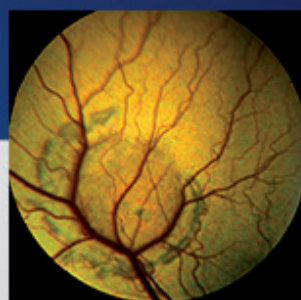


**Hereditary ocular disease  
in the dog**

**Hereditary oral disorders  
in pedigree dogs**



**Chiari-like malformation  
and syringomyelia**

**Breeding healthier  
dogs: the vet's role**



**Breeding healthier dogs: the breeders' role; Hereditary heart disorders; Screening for orthopaedic genetic defects; Prevalence, grading and genetics of hemivertebrae in dogs ... and more...**

## Contents

		The role of the FCI, national kennel clubs and breeders regarding the functional health of pedigree dogs <i>Astrid Indrebø</i>	4-11
		Canine Genetic Health - Roles and Responsibilities of the Veterinary Profession <i>Ake Hedhammar</i>	12-22
		Hereditary Ocular Disease in the dog <i>Peter G C Bedford</i>	23-41
		Hereditary oral disorders in pedigree dogs. Proposals for their evidence and assessment <i>J.Gawor</i>	42-54
		Genetic background of acquired cardiac disease in dogs <i>Jens Häggström, Katja Höglund, Ingrid Ljungvall</i>	55-69
		Chiari-like malformation and syringomyelia <i>Clare Rusbridge</i>	70-89
		Screening for Orthopaedic Genetic defects Part 1 Patella Luxation in dogs <i>Herman Hazewinkel, Bernd Tellhelm, Peter Leegwater</i> Part 2 Elbow Dysplasia <i>Herman Hazewinkel, Bernd Tellhelm, Peter Leegwater</i> Part 3 Spondylosis in dogs <i>Herman Hazewinkel, Silke Viefhues, Bernd Tellhelm</i>	90-98 99-113 114-118
		Prevalence, grading and genetics of hemivertebrae in dogs <i>E. Schlensker, O. Distl</i>	119-123

# Icons

Each scientific article is classified with one or more icons.

These refer to the species (in green) of animal or the veterinary discipline (in blue) relevant for the article.



Dogs



Cats



Dogs and Cats/Small animals



Rabbits



Less common pets



Anaesthesia



Cardiovascular



Dental



Dermatology



Diagnostic imaging



Digestive System



Ear Nose Throat



Genetics



Internal Medicine



Neurology



Ophthalmology



Orthopaedics



Practice Management



Urogenital



## COMMISSIONED PAPER (N)

# The role of the FCI, national kennel clubs and breeders regarding the functional health of pedigree dogs

Astrid Indrebø<sup>1,2</sup>

### SUMMARY

The role of the world wide organisation FCI is to make overall goals and strategies on how to breed healthy dogs, conduct education programmes for breeders and show judges, and assure that the breed standards describe healthy dogs. The awareness to recognize the responsibility concerning health issues both when selecting dogs for breeding as well as awarding functionally healthy dogs in the show ring must be highlighted in education programmes. The roles of the national kennel clubs are to work out and control the national rules and regulations, screening programmes and breeding values and make the results available for the breeders, as well as draw up general and breed specific health programmes and education programmes both for breeders and show judges. The final responsibility for healthy dog breeding will, however, always be that of the breeder. Animal welfare must be the most important goal in any dog breeding.

This paper was commissioned by FECAVA for the special issue of EJCAP, Genetic/Hereditary Disease and Breeding.

*be encouraged to emphasize the importance of the combination of dogs as well as selection of the individual dog to be used for breeding.*

### Introduction

The FCI Breeding Strategies, approved by the FCI General Committee, February 2010 <sup>[1]</sup>, states in its introduction: *The goal in dog breeding is functionally healthy dogs with a construction and mentality typical to the breed, dogs that can live a long and happy life for the benefit and pleasure of the owner and the society as well as the dog itself. Breeding should be carried out in such a manner that it promotes the health and wellbeing of the progeny, as well as the welfare of the bitch. Knowledge, honesty and cooperation, both on national and international level, is basic in healthy dog breeding. Breeders should*

There has been a growing public focus on dog breeding during the last decade, and the BBC programmes *Pedigree dogs exposed* sent out strong warning signals of what is going on in parts of the organized dog world. Although the situation in many countries is not comparable to what was shown in the programme, programmes like this are important wake-up calls for all of us. Both as veterinarians and dog breeders many of us have dedicated lots of years of our life to animal welfare, which is the fundament for healthy dog breeding. There is no doubt that heavy inbreeding through generations and breeding for unhealthy exaggerations has a major impact on animal welfare!

1 Norwegian Kennel Club, PO Box 163 Bryn, N-0611 Oslo, Norway

2 Norwegian School of Veterinary Science, Department of Companion Animal Clinical Sciences, PO Box 8146 Dep., N-0033 Oslo, Norway



To ensure the health and well-being of pedigree dogs, genetic diversity needs to be preserved, or preferably extended, the selection of unhealthy genotypes should be discouraged and exaggeration leading to health problems should be avoided. All kennel clubs and breeders must be willing to accept their responsibility for the existing problems, and work together in cooperation to improve or maintain the health of pedigree dogs. It must be basic in every breeding program that only functionally and clinically healthy dogs should be used for breeding.

## Fédération Cynologique Internationale (FCI)

The FCI is a worldwide international federation of national kennel clubs, established in 1911. The federation includes 86 member countries and contract partners, and there are more than 2 million individual members in the participating countries. More than 2.2 million puppies are registered each year by the national kennel clubs within the FCI. The FCI cover large parts of the world, but some major kennel clubs, like the Kennel Club (UK), the American Kennel Club and the Canadian Kennel Club are not FCI members. There is, however, mutual recognition of stud books and collaborations regarding health issues connected with the breed standards [2].

The aims of the FCI are given in the statutes: *The aims of the FCI are to encourage and promote the breeding and use of purebred dogs whose functional health and physical features meet the standard set for each respective breed and which are able to work and to carry out different functions in accordance with the specific characteristics of their breed; to protect the use, the keeping and the breeding of purebred dogs in the member countries; to support the non-profit exchange of dogs and cynological information between the members and initiate the organization of shows, tests, trials and other activities like sport events, the use of dogs in rescue operations, etc.; to promote and support canine issues and dog welfare worldwide.* By issuing special regulations, the FCI shall in particular ensure: *the promotion of ethics and scientific research, which is of fundamental importance in cynology, and the free exchange of scientific information between the member countries and contract partners* [3].

The large number of member countries world wide gives the FCI the potential to have great impact on dog

breeding. But, on the other hand, the large cultural, political, economic and educational differences between the countries are major challenges for the FCI. Lots of the member countries are far apart concerning means to control animal health, screening programmes, education of breeders as well as open databases with pedigree and health results. It is almost impossible to impose strict, specific rules and regulations on specific health issues to be valid for all the member countries. The FCI has instead made overall strategies and general rules and recommendations on how to take care of, and improve, the welfare aspect of breeding pedigree dogs. It is the responsibility of the national kennel clubs and breed clubs to make both general and breed specific health programmes and regulations in accordance to the main rules and strategies of the FCI. The final responsibility, however, always lies with the breeder.

It is important to focus that the FCI and the national kennel clubs only have influence to control pedigree dogs. If the rules and regulations are too strict, there will be a growing number of non-pedigree purebred dogs which will be out of control for health programmes, like screening programmes, breeding values, health registries and prevention of intensive inbreeding. This is not beneficial for animal welfare.

Also, too strict breeding regulations will be a danger to the gene pool in pedigree dogs, as too few dogs may be used for breeding. This might encourage the over-use of popular stud dogs, which will reduce the genetic diversity and increase the risk of serious health problems.

## FCI Code of Breeding Ethics

The main objectives with strong focus on animal welfare is given in the Code of Breeding Ethics, stated in Standing Orders of the FCI, Art 12: *Breeding and the development of dog breeds must be based on long-term objectives and sound principles so that the breeding does not result in diseases, bad temperament or lack of working skills. Breeding must serve the objective of preserving and preferably extending the genetic diversity (polygenicity) of the breed. Only functionally healthy dogs are to be used for breeding. It is incumbent on all breeders selecting dogs for breeding to determine whether such breeding animals are mentally and physically suitable for reproduction. The breeder must ensure that the animals he intends to use for breeding have a stable temperament and are in good*

*physical condition. As long as a puppy is in the breeder's custody, he must ensure a physically and mentally beneficial environment for the puppy to guarantee proper socialisation* <sup>[3]</sup>.

The basis for action to enhance canine genetic health should be an integrated consideration of severity, prevalence, inheritance and detection (e.g. ability to identify diseased/affected/carriers) of disorders, along with the availability of effective control or prevention programmes that can be monitored <sup>[4,5]</sup>.

## FCI Breeding Strategies

As a world wide organisation, the FCI has focused on the responsibilities and the possibilities to improve the functional health of pedigree dogs in large parts of the world. In February 2010, the FCI General Committee approved the Breeding Strategies (Table 1) as proposed by the FCI Breeding Commission in cooperation with the Scientific Commission <sup>[1]</sup>. The main points of the Breeding Strategies are discussed below.

## Education of dog breeders

Information and education of breeders are probably the most powerful tools to influence dog breeding <sup>[5]</sup>, and are strongly recommended by the FCI rather than strict breeding regulations and stringent demands in breeding programmes, which can easily result in reduced genetic diversity in the breed as well as exclusion of excellent breed representatives and reduced cooperation with conscientious breeders. The national kennel clubs are encouraged to conduct education programmes for breeders, preferably on an annual basis.

The Breeders' School of the Norwegian Kennel Club (NKK) was established 20 years ago, and consists of two week-end courses, arranged in the 11 national regions. There is no obligation for breeders to attend as it is all done on voluntary basis. The idea is to make the seminars so attractive that both experienced breeders as well as people who want to start breeding will attend the seminars because they want to learn, not because they are forced to come. This has been a great success, with 100-200 participants in each course. The main subjects are genetics, inheritance, health, selection and combination of breeding dogs as well as reproduction, obstetrics, paediatrics, responsibilities, rules and

regulations, all with a strong focus on animal welfare. It is our belief that no breeders really want to breed diseased puppies. It's up to the kennel clubs and breed clubs to give the breeders education and support to help them reach their goal of breeding healthy dogs.

## Selection and combination

*Only functionally and clinically healthy dogs, with breed typical conformation, should be used for breeding* (Art 2). This is the most important guideline in dog breeding. If this was the only rule for selection of dogs for breeding, pedigree dogs would probably be healthier than many breeds are today. It is, however, not enough that the dog is functionally and clinically healthy, although this is fundamental for every dog used for breeding. It does not help that a dog is free from hip dysplasia (HD), elbow dysplasia (ED), inherited eye diseases or other screening diagnoses; if the dog is not functionally and clinically healthy and without need of medication it should not be considered bred from.

*If close relatives of a dog suffering from an inherited disease or functional disability are used for breeding, they should only be mated to dogs from bloodlines with low or no occurrence of the same disease or disability* (Art 2.1). In order to fulfil this, it is of uttermost importance that the breeders and dog owners send veterinary reports to the breed club and/or kennel club to identify dogs and blood lines which have been diagnosed with inherited diseases. The combination of dogs for breeding is just as important as the selection of the individual dog. If there was a rule that close relatives of the sick dogs should be excluded from breeding, both breeders and owners might avoid reporting diagnoses of diseased dogs, because reporting would result in elimination of a lot of healthy dogs from breeding. This will not improve the health of the dog population, but might instead give more problems because of unsuccessful selection and combination of dogs. The FCI encourages focusing on the selection of functionally and clinically healthy dogs for breeding; don't exclude too many healthy dogs, but make combinations to avoid unhealthy offspring.

*Mating combinations which from available information increase the risk of serious diseases or functional disabilities or impairment of the progeny should be avoided* (Art 2.2). For a lot of diseases this is impossible without cooperation and honesty among breeders.

**Table 1: FCI INTERNATIONAL BREEDING STRATEGIES<sup>1</sup>**

Approved by FCI Breeding Commission Naples, May 2009; the document was approved by FCI General Committee in Madrid, February 2010

#### 1. Introduction

The goal in dog breeding is functionally healthy dogs with a construction and mentality typical to the breed, dogs that can live a long and happy life for the benefit and pleasure of the owner and the society as well as the dog itself. Breeding should be carried out in such a manner that it promotes the health and wellbeing of the progeny, as well as the welfare of the bitch. Knowledge, honesty and cooperation, both on national and international level, is basic in healthy dog breeding. Breeders should be encouraged to emphasize the importance of the combination of dogs as well as selection of the individual dog to be used for breeding.

The FCI members and contract partners should conduct education programmes for breeders, preferably on annual basis. Education of breeders is to be recommended prior to strict breeding regulation and stringent demands in breeding programmes, which can easily result in reduced genetic diversity in the breed as well as exclusion of excellent breed representatives and reduced cooperation with conscientious breeders. Breeders and breed clubs should be encouraged to cooperate with scientists in genetic health issues, to prevent combination of dogs from lines that will result in unhealthy offspring. Any dog used for breeding or screened for inherited diseases, must have identification (chip or tattoo).

The breeders should keep the breed standard as the guideline for the breed specific features; any exaggerations should be avoided.

#### 2. Only functionally and clinically healthy dogs, with breed typical conformation, should be used for breeding; i.e. to only use dogs that do not suffer from any serious disease or functional disabilities.

2.1 If close relatives of a dog suffering from an inherited disease or functional disability are used for breeding, they should only be mated to dogs from bloodlines with low or no occurrence of the same disease or disabilities. If a DNA-test for the disease/functional disability is available, the breeding stock should be tested in order avoid mating of two carriers (see point 5).

2.2 Mating combinations which from available information increase the risk of serious diseases or functional disabilities or impairment in the progeny, should be avoided.

2.3 Only dogs having a sound temperament, typical for the breed, should be used for breeding. That is to only use dogs that do not show signs of behavioural disturbance in the form of excessive fear reactions or aggressive behaviour in unprovoked situations or situations that can be considered as everyday situations for the dog.

#### 3. To preserve, or preferably extend, the genetic diversity of the breed, matador breeding and heavy inbreeding should be avoided. Mating between siblings, mother to son or father to daughter should never be performed. As a general recommendation no dog should have more offspring than equivalent to 5% of the number of puppies registered in the breed population during a five year period. The size of the breed population should be looked upon not only on national but also on international level, especially in breeds with few individuals.

#### 4. Screening results (positive or negative) for phenotypic appearance of polygenetic diseases should be available in open registries. The results should be used to aid the selection and combination of breeding dogs.

4.1 Breeding values based on screening results should when possible be computerised to facilitate selection of the breeding stock not only on the phenotypic appearance but also by indicated genotype. As a general rule the estimated breeding value for a combination should be better than average for the breed.

4.2 Screening should only be recommended for diseases and breeds where the disease has major impact on the dogs' functional health.

#### 5. Results from DNA tests for inherited diseases should be used to avoid breeding diseased dogs, not necessarily to eradicate the disease. Dogs shown to be carriers (heterozygote) for a recessive inherited disease should only be bred to a dog that is proven not to carry the allele for the same disease.

#### 6. Any dog should be able to mate naturally. Artificial insemination should not be used to overcome physical inabilities of the dog. A bitch should be excluded from further breeding if she is unable to give natural birth, due to anatomy or inherited inertia, or if she is unable to take care of the newborn puppies, due to mentality or related to agalactia (no milk production).

#### 7. Health issues that cannot be diagnosed by DNA-tests or screening programmes, should have equal impact in the breed specific breeding programmes.

#### 8. As a general rule, a breeding programme should not exclude more than 50% of the breed; the breeding stock should be selected from the best half of the breed population.

#### 9. The raising of puppies, with correct feeding, environmental exposure, stimulation by their mother, breeder and others to develop social sense and response, must be basic in every breeding.

More specific details about healthy dog breeding are given in FCI International Breeding Rules and FCI Standing Orders (Article 12 - Code of Breeding Ethics).

The FCI focuses strongly on temperament: *Only dogs having a sound temperament, typical for the breed, should be used for breeding. That is only to use dogs that do not show signs of behavioural disturbances in the form of excessive fear reactions or aggressive behaviour in unprovoked situations that can be considered everyday situations for the dog* (Art 2.3). The most important task of the dog today is to be a companion dog, which can adjust and function in the modern society. In a growing number of countries breeds are banned as “dangerous breeds”. There might be dangerous individuals in many breeds, and instead of banning breeds, the FCI encourages every member country to ban dangerous dogs, or dogs with an unsound temperament, from breeding. No breed accepted by the FCI should be dangerous as a breed; it is never normal for a breed to be dangerous in unprovoked everyday situations!

## Genetic diversity

To preserve, or preferably extend, the genetic diversity of the breed, matador breeding and heavy inbreeding should be avoided. Mating between siblings, mother to son or father to daughter should never be performed (Art 3).

There has been much focus on inbreeding in pedigree dogs during recent years. There is absolutely no doubt that heavy inbreeding increases the risk of sick offspring and also the risk of losing genetic diversity within the breed. The FCI states that mating between siblings, mother to son or father to daughter should never be performed. But mating of half-siblings or even cousins might in some cases be heavier inbreeding than between siblings, because inbreeding might have been performed through generations. The Norwegian Kennel Club forbids any combination with an inbreeding coefficient  $\geq 25\%$ , calculated from a pedigree of six generations.

*To avoid matador breeding, the FCI recommends that no dog should have more offspring than equivalent to 5% of the number of puppies registered in the breed population during a five year period* (Art 3). If too many dams are mated to a single stud dog, the gene pool will drift in that dog's direction, and the result will be a loss in genetic diversity in the breed. Strict rules in breeding programmes might easily encourage matador breeding. Loss of genetic diversity results in a dramatic reduction in the possibility of progress in breeding and increase the risk of concentrating undesirable genes in the population.

Popular sire syndrome is probably one of the most serious “diseases” in modern dog breeding and a threat to animal welfare.

More than 350 different breeds are recognised by the FCI. This large number implies breeding in many small populations, where each breed constitutes a relatively closed genetic pool<sup>[6]</sup>. The selection for specific characteristics, working abilities and other behaviour traits has resulted in reduced genetic variation within the breeds. Many of the breeds originate from a small number of founder dogs, resulting in an effective population size which is much smaller than the census population size<sup>[7]</sup>. In addition, many breeds are divided into sub types or varieties due to coat colour, hair length, size etc, which are kept as separate breeds without allowing interbreeding the varieties, resulting in even smaller gene pools.

To reverse this negative effect, the FCI in 2011 approved a proposal from a joint meeting of the Standard, Scientific and Breeding Commissions: FCI General and breed specific guidelines about crosses of breeds and breed varieties. This document states that the FCI encourages crosses between breed varieties in order to increase the gene pool and improve dog health; it is not beneficial for health in dog breeding to have too small populations. In general it should be possible to cross closely related breeds or breed varieties in order to avoid or reduce health problems or problems caused by unhealthy conformation (FCI Circular 04/2012)<sup>[8]</sup>.

To reduce the number of new breeds, the FCI has strict procedures for the recognition of new breeds. For example, the national kennel clubs must provide proof of a sufficiently large population of unrelated dogs by verification of the existence of a minimum of eight independent lines, show an appreciation of the health status of the breed and also ensure that breed standards do not interfere with health<sup>[2]</sup>. There are, however, additional aspects of the breed concept to be considered. Prerequisites and procedures for recognition of breeds and varieties was an important issue at the 1st International Workshop on Enhancement of Genetic Health in Purebred Dogs arranged by the Swedish Kennel Club in Stockholm in 2012. The workshop concluded that improvement of health and diversity can be obtained by crossing varieties and potentially by combining breeds that are genetically related. No new breed should be created from already



existing breeds. New varieties may be accepted, but should not be encouraged. Molecular tools can be used to characterize breeds and varieties and genotypes gathered in a common databank <sup>[9]</sup>.

## Screening results – open databases

*Screening results (positive or negative) for phenotypic appearance of polygenetic diseases should be available in open registries. The results should be used to aid the selection and combination of breeding dogs (Art 4).*

The FCI emphasizes that screening should only be recommended for diseases and breeds where the disease has major impact on the dogs' functional health. Screening should be performed because there is a problem in the breed, not just because a test is available. A growing number of breeds are screened for hip dysplasia through recent decades, even miniature breeds. If some of these breeds actually have a clinical HD-problem, they should be screened and the result used in selection and combination of dogs. But if they do not have a clinical problem, selection against HD might reduce the effect of selection of other more important health issues in the breed.

Selection of dogs for breeding based on individual screening result for polygenetic diseases, where also non-genetic factors have major impact on the screening result, like HD and ED, has limited effect in reducing the frequency of the disease in the population <sup>[10,11,12,13]</sup>. Calculated breeding values, based on all available pedigree and screening information, would be a far better tool, provided that a sufficient part of the population is screened. The FCI recommends that breeding values based on screening results should be computerised to facilitate selection of the breeding stock not only on the phenotypic appearance, but also by indicated genotype. As a general rule the estimated breeding value for a combination should be better than the average for the breed. Some kennel clubs started this process years ago, and computerised estimated breeding values for HD for several breeds are available in open databases in the Nordic kennel clubs <sup>[14,15,16]</sup>.

Screening for inherited eye diseases has been performed in a lot of countries for decades. The education of panellists as well as the routines and certificates for diagnosis should be comparable world wide. In Europe

most countries are now using the international scheme and certificate of the European College of Veterinary Ophthalmologists (ECVO) <sup>[17]</sup>. All the results, positive and negative, should be open to the public in the database of the national kennel clubs.

During the last decade, a rapidly growing number of DNA-tests for inherited diseases are becoming available for dog breeders. These are of great value for healthy dog breeding if they are used correctly. The results should be used to prevent diseased offspring being born, not necessarily to eradicate the disease. Eradication of an autosomal recessive gene from the population might have a strong impact on the breed population, resulting in reduced genetic diversity. It is stated in the FCI Breeding Strategies that dogs shown to be carriers (heterozygote) for a recessive inherited disease should only be bred to a dog proven not to carry the allele for the same disease. The results should be available in an open database, and dogs from parents proven to be free from the specific gene should be automatically be diagnosed as genetically free in the database.

It is of uttermost importance to consider the total picture of health status and other characteristics of the dog, both for selection and for combination of dogs for breeding. There are a lot of health issues that cannot be diagnosed by DNA-tests or screening programmes. Nevertheless, these should have equal impact in the breed specific breeding programmes (Art 7).

## Natural mating – natural birth

*Any dog should be able to mate naturally. Artificial insemination should not be used to overcome physical inabilities of the dog. A bitch should be excluded from further breeding if she is unable to give natural birth, due to anatomy or inherited inertia, or if she is unable to take care of the newborn puppies, due to mentality or inherited agalactia (Art 6).* In some breeds, both breeders and veterinarians seem to accept that a bitch is unable to give natural birth, blaming the breed standard. Caesarean section is performed shortly prior to the time of natural birth; the bitch is not given the opportunity to prove if she is actually capable of giving natural birth. This is definitely wrong! There is no description in any breed standard that supports this. If the anatomy of the bitch makes it impossible to give natural birth, it is most often due to unhealthy exaggerations, selected for by the

breeders despite the breed standard. The veterinarians should strongly advise against such unhealthy breeding, and not perform a caesarean section unless it is absolutely necessary.

### **Do not exclude too many dogs from breeding**

*As a general rule, a breeding programme should not exclude more than 50% of the breed; the breeding stock should be selected from the best half of the breed population (Art 8).*

In most populations only a small percentage of the dogs are used for breeding. The selection is too strict, leading to limited gene pools. In Sweden, on average only 5% of male dogs and 10-20% of bitches that are potentially available are currently used in breeding (S. Malm et al., unpublished data). The situation is about the same in Norway and probably in most other countries<sup>[18]</sup>. The kennel clubs should encourage using more dogs for breeding, instead of using fewer dogs too often.

### **The raising of puppies**

*The raising of puppies, with correct feeding, environmental exposure, stimulation by their mother, breeder and others to develop social sense and response, must be basic in every breeding (Art 9).* The final responsibility lies with the breeder, and the kennel clubs should provide education to all breeders to fulfil this arguably most important issue for the welfare of the dog.

### **Breed standards**

The FCI Standard Commission, in cooperation with the national kennel clubs that are responsible for their own national breeds, has done a lot of work during the last 20-30 years to promote health in the breed standards. In addition to altering the breed standards towards the description of a healthier and more anatomically functional dog, the following sentence has been

introduced in all the FCI breed standards since 2003: "Any dog clearly showing physical or behaviour abnormalities shall be disqualified." Some kennel clubs within the FCI have implemented strict guidelines for judges in how to interpret breed standards with reference to health<sup>[2]</sup>. The main point is to avoid exaggerations that have, or might have, negative impact on the dogs' health and welfare. There is no doubt that the show judges have a large responsibility for the health of pedigree dogs.

The Swedish Kennel Club has been pioneers in systemizing the work concerning the responsibility of show judges regarding unhealthy exaggerations<sup>[19]</sup>. Based on the extensive Swedish material, an ad hoc committee from the FCI Scientific and Standard Commissions is currently working on how to implement the training of judges in their task in accordance with general, as well as breed-specific, guidelines within all the FCI member countries. In addition to breed-specific advice for several breeds, the following general statements apply to dogs of all breeds<sup>[2,19]</sup>:

- All dogs should be able to breathe normally at rest and when moving.
- All dogs should have clear eyes, without any sign of discomfort.
- All dogs should have healthy skin, without any sign of discomfort.
- The coat should not be so extensive as to impede movement.
- All dogs should be able to move naturally without visible effort or pain.
- All dogs should have good temperament suitable for life in present society. Breed-specific behaviour must be noted and allowed, but excessive shyness or sharpness of temperament is not desirable. Aggressive dogs and dogs showing signs of panic and/or fear should always be disqualified.

## References

- [1] <http://www.fci.be/commissions.aspx> (April, 2013)
- [2] Hedhammar ÅA, Indrebø A. Rules, regulations, strategies and activities within the Fédération Cynologique Internationale (FCI) to promote canine genetic health. *The Veterinary Journal* 2011; 189: 141-146.
- [3] <http://www.fci.be/reglements.aspx> (April, 2013)
- [4] Bonnet BN. Companion animal health and longevity: Interplay with human-animal interaction. In: *Small Animal and Exotics Proceedings; North American Veterinary Conference, Orlando, Florida, USA 2011*; 175-177.
- [5] Hedhammar ÅA, Malm S, Bonnet B. International and collaborative strategies to enhance genetic health in purebred dogs. *The Veterinary Journal* 2011; 189: 189-196.
- [6] Parker HG, Kim LV, Sutter NB, Carlson S, Lorentzen TD, Malek TB, Johnson GS, DeFrance HB, Ostrander EA, Kruglyak L. Genetic structure of the purebred domestic dog. *Science* 2004; 304: 1160-1164.
- [7] Karlsson EK, Lindblad-Toh K. Leader of the pack: Gene mapping in dogs and other model organisms. *Nature Reviews Genetics* 2008; 9: 713-725.
- [8] <http://www.fci.be/circulaires2012.aspx> (April, 2013)
- [9] <http://www.skk.se/in-english/dog-health-workshop-2012/key-issues/recognition-of-breeds/workshop-materials/> (April, 2013)
- [10] Swenson L, Audell L, Hedhammar Å. Prevalence and inheritance of and selection for hip dysplasia in seven breeds of dogs in Sweden and benefit:cost analysis of a screening and control program. *Journal of the American Veterinary Medical Association* 1997; 210: 207-214.
- [11] Mäki K, Groen AF, Liinamo A-E, Ojala M. Genetic variances, trends and mode of inheritance for hip and elbow dysplasia in Finnish dog population. *Animal Science* 2002; 75: 197-207.
- [12] Indrebø A. Breeding healthy dogs – a breeders perspective. *The European Journal of Companion Animal Practice* 2005; 15(1): 17-21.
- [13] Malm K, Strandberg E, Fikse WF, Danell B. Genetic variation and genetic trends in hip and elbow dysplasia in Swedish Rottweilers and Bernese Mountain Dogs. *Journal of Animal Breeding Genetics* 2008; 125: 403-412.
- [14] Mäki K. Breeding against hip and elbow dysplasia in dogs. PhD Dissertation. University of Helsinki, Finland, 2004.
- [15] Madsen P, Indrebø A, Lingaas F. BLUP Animal Model for prediction of breeding values for hip dysplasia in Norwegian dog breeds. Abstract. EAAP Annual meeting 2009, Barcelona, Spain.
- [16] Malm S, Sørensen AC, Fikse WF, Strandberg E. Efficient selection against categorically scored hip dysplasia in dogs is possible using best linear unbiased prediction and optimum contribution selection: a simulation study. *Journal of Animal Breeding Genetics* 2013; 130: 154-164.
- [17] <http://www.ecvo.org> (April, 2013)
- [18] Calboli FCF, Sampson J, Fretwell N, Balding DJ. Populations structure and inbreeding from pedigree analysis of purebred dogs. *Genetics* 2008; 179, 593-601.
- [19] Svenska Kennelklubben. Special Breed Specific Instructions (BSI) regarding exaggerations in pedigree dogs. 2009.



## COMMISSIONED PAPER (SE)

# Canine Genetic Health - Roles and Responsibilities of the Veterinary Profession

Åke Hedhammar<sup>1</sup>

### SUMMARY

Small animal veterinarians are commonly faced with health problems in dogs that have a strong genetic background. Breeders and cynological organisations have been, and continue to be blamed, for this poor genetic situation. This paper takes a critical look at the roles and responsibilities of the veterinary profession and reviews the past, current, and future involvement of small animal veterinarians in the enhancement of canine genetic health.

Keywords: dogs, breeding, health, veterinarians

This paper was commissioned by FECAVA for the special issue of EJCAP, Genetic/Hereditary Disease and Breeding.

### Introduction

Since their domestication from the wolf, dogs have been selected and bred by humans to suit their personal tastes. However this selection has not been applied equally to all dog populations and the focus has changed over time. Recently there has been an intense and predominantly justified focus on the genetic health of pedigree dogs.

Pedigree dogs account for less than 10% of the global canine population <sup>[1]</sup>. Free-ranging dogs, including wild, feral, stray, street, and village dogs make up a large proportion of the world's dog population; these dogs have been less influenced by human breeding decisions however many diseases, defined as genetic conditions of pedigree dogs, also exist in non-pedigree populations <sup>[2]</sup>. This paper addresses how we, as small animal veterinarians, are able to promote and enhance the genetic health of dogs with or without a known pedigree.

### Background

Through evolution and domestication dogs have evolved as the most varied of all domesticated species, ranging dramatically in behavioural characteristics as well as in size, colour, coat, and body conformation. This variation is not only seen in what have been defined as pedigree or purebred dogs, but it is also seen in wild, stray, and village dog populations <sup>[3]</sup>. Some conformational defects such as acromegaly, brachycephaly and chondrodystrophy were documented in canine populations before the invention of formal breed classifications <sup>[4]</sup>.

Whilst originally selected for their actual performance of various tasks such as hunting, guarding, and herding, for a long time dogs have also been bred for their appearance; often for an appearance with a supposed or hypothesised correlation to desired functional capabilities (e.g. as hunters, herders or protectors). Human perceptions and preferences (e.g. cuteness / anthropomorphic ideas, size, hair coat, etc.) have also played a role, especially since the Victorian era. Selection has also, particularly in recent times, been focused on

1 Åke Hedhammar, DVM, PhD, Professor Internal Medicine – small animals, Dipl. ECVIM (CA), Department of Clinical Sciences, Swedish University of Agricultural Sciences, Uppsala, Sweden



the appearance and success of the breeding stock, with less emphasis placed on the health or performance of the progeny.

Both Darwin and Linnaeus described less than 20 types of dogs. Since the mid-19th century and the establishment of Kennel Clubs, pedigree dog registries and so-called breed standards, the number of populations defined as breeds have increased dramatically. The international organisation Federation Cynologique Internationale (FCI) today recognises more than 350 breeds. Often, varieties just based on size, colour, coats and geographical location have now been classified as breeds.

Introduction of breed standards and closed stud books have encouraged the so-called 'line breeding' and even inbreeding to an extent very much like that seen in geographically isolated populations of various species, including humans. As a consequence of these breeding practices the phenotype of many breeds has become almost fixed, sometimes including breed-specific disease risks and a very high within-breed prevalence of certain hereditary disorders. Breed standards and dog shows, without malicious intent, also have encouraged selection for exaggerated anatomical features.

The cynological organisations and breeders of the past probably bear a substantial responsibility for the current situation in those breeds where a high proportion suffer from disorders related to their (extreme) anatomical features and/or other hereditary disorders. Individual veterinarians and veterinary associations over the same period however have, in various capacities, been serving and supporting breeders as well as individual dog owners and dogs.

We must therefore, also share some of the responsibility for the current situation, even if it is only mainly related to inaction and silence. We must also share the responsibility to make changes for future improvement. These changes should be made in collaboration with other stakeholders including the cynological organisations, geneticists, authorities and welfare organisations as well as individual breeders and dog owners to make them more effective. <sup>[5,6,7]</sup>

## Classification of genetic disease

Genetic disease is a broad terminology that has been applied to anything from monogenetic conditions caused by specific genes and mutation, e.g., CLAD in Irish setters <sup>[8]</sup> and numerous PRA variants <sup>[i.e. 9]</sup>, to those simply

indicated to have a genetic component in their aetiology based on breed predisposition or a familiar pattern of segregation, e.g., complex diseases like lymphocytic thyroiditis, atopic dermatitis and diabetes mellitus in many breeds <sup>[10,11,12]</sup>.

Genetic diseases are commonly described by organ system, i.e. locomotor, ocular, cutaneous, endocrine etc. Attempts have also been made to classify them by prevalence <sup>[13,14,15]</sup> and severity. Data on prevalence and severity are of outmost importance to help make priorities for control measures <sup>[16]</sup>.

## Changing knowledge about genetic diseases

The role played by genes in disease is becoming better understood. Genetic factors are involved to a greater or lesser extent in congenital malformations, metabolic disorders, disorders of immune function, and disorders associated with aging or cancer. These categories of disease have become relatively more important as infectious, parasitic, and nutritional diseases have become less common due to vaccination programmes and advancing knowledge regarding nutrition, treatments, and diagnostic methods <sup>[17]</sup>.

With this change in the pattern of disease, issues related to inherited disease comprise an increasing proportion of the workload of veterinary practitioners both in terms of time and economics. It is worth noting and considering that veterinarians may experience a degree of conflict of interest when trying to balance concerns of their livelihood whilst at the same time guarding the well-being of the dog.

This conflict of interest was described by Sir Patrick Bateson in his report commissioned in 2010<sup>[18]</sup>. The challenges faced are multiplied when one considers health and welfare from a population perspective. In addition to the challenges of examining the impact and occurrence of genetic or inherited disorders in dogs, defining and classifying the conditions is also problematic. Veterinarians have been of utmost importance in defining genetic disease including the more precise phenotypic classification of diseases defined as heritable. Unfortunately, the scientific definition of disease does not always reflect or mirror the clinical presentations or provide the required information for counselling about breeding decisions.

As a consequence not only of breeding practices, but also due to increased awareness and knowledge, the number of canine diseases classified as genetic have increased dramatically - currently almost 600<sup>[19]</sup>. It is worth noting that this is minimal when compared to known human genetic conditions - more than 20 000<sup>[20]</sup>.

The prevalence of canine inherited diseases is more difficult to evaluate due to lack of population-based data and the compounding effect of increased attention given to newly-recognised conditions. When the entire canine genome was revealed<sup>[21]</sup> - the seventh to be revealed after man<sup>[22]</sup> - knowledge regarding canine genetic disease was boosted.

The sources of information about genetic diseases for the veterinary community are now numerous compared to those that were available in the 60's in, e.g. the textbooks like *Current Veterinary Therapy*<sup>[23]</sup>. Don Paterson at Pen. State Vet College was one of the pioneers in assembling the information available on what then was known about so called hereditary diseases in Dogs. At the time of the 5th edition of that textbook hereditary diseases numbered only about 100. This kind of information is now available online (see Table 1)<sup>[24]</sup>, and possibilities for molecular genetic testing are also available on a website recently launched by WSAVA<sup>[25]</sup>. Unfortunately, many of these resources are to a great extent merely lists of diseases with no measure of risk, incidence or even prevalence of disease. Many extremely rare conditions are listed equally with more common conditions.

Adding to the confusion in the literature, it is not uncommon that the proportional morbidity or mortality estimates available from studies citing occurrence of diseases in dogs attending one or more veterinary hospitals (e.g., those from the VMDB in the US) to be sometimes mistakenly quoted as prevalence or risk<sup>[26]</sup>. This makes it difficult for breeders or veterinarians to

prioritise the importance of various conditions within a breed. In addition, many veterinarians are not appropriately trained in genetic counselling for breeding within changing developments in canine molecular and population genetics.

## Sources of population-based data

Population-based data on the prevalence of various diseases are available in health surveys<sup>[27]</sup>, registered results from screening programmes<sup>[28]</sup>, from hospital records<sup>[21]</sup> and insurance data<sup>[13, 14, 29]</sup>.

Health surveys are commonly performed by national breed clubs and based on owner-reported data, with its inherent strengths and weaknesses. Survey data are only representative of a larger population if there is good sampling methodology, an adequate sample size and high response rate. Unfortunately, these criteria are rarely fulfilled by breed club surveys. Of course hospital and insurance data also have benefits and limitations, i.e. perhaps a more valid determination of disease status, but, in the case of hospital data generally, the lack of a reference population. Depending on the source, insurance data may or may not be representative of a larger population. Comparing and contrasting results from various sources must be done although actual prevalence and incidence numbers may not be entirely valid for many breeds. For many conditions a remarkably consistent pattern of breed predilections may emerge, indicating a much stronger breed than geographic isolation.

Insurance data has the benefit of being larger and broader than most health surveys and hospital data. Unlike in most countries where comprehensive insurance data is not available, Swedish insurance data has underpinned an effective collaboration between veterinarians, researchers, dog breeders, the Kennel Club

Table 1 Web based sources of genetic disease information on dogs

OMIA	University of Sydney	<a href="http://omia.angis.org.au/home">http://omia.angis.org.au/home</a>
CIDD	University of Prince Edward Island	<a href="http://www.upei.ca/cidd">www.upei.ca/cidd</a>
LIDA	University of Sydney	<a href="http://www.sydney.edu.au/vetscience/lida">www.sydney.edu.au/vetscience/lida</a>
IDID	Cambridge University	<a href="http://server.vet.cam.ac.uk">http://server.vet.cam.ac.uk</a>
OFA	Orthopedic Foundation of America	<a href="http://www.offa.org">http://www.offa.org</a>
CHF	Canine Health Foundation	<a href="http://www.akcchf.org">http://www.akcchf.org</a>
WSAVA/VIN	World Small Animal Vet Ass.	<a href="http://research.vet.upenn.edu/WSAVA-LabSearch">http://research.vet.upenn.edu/WSAVA-LabSearch</a>

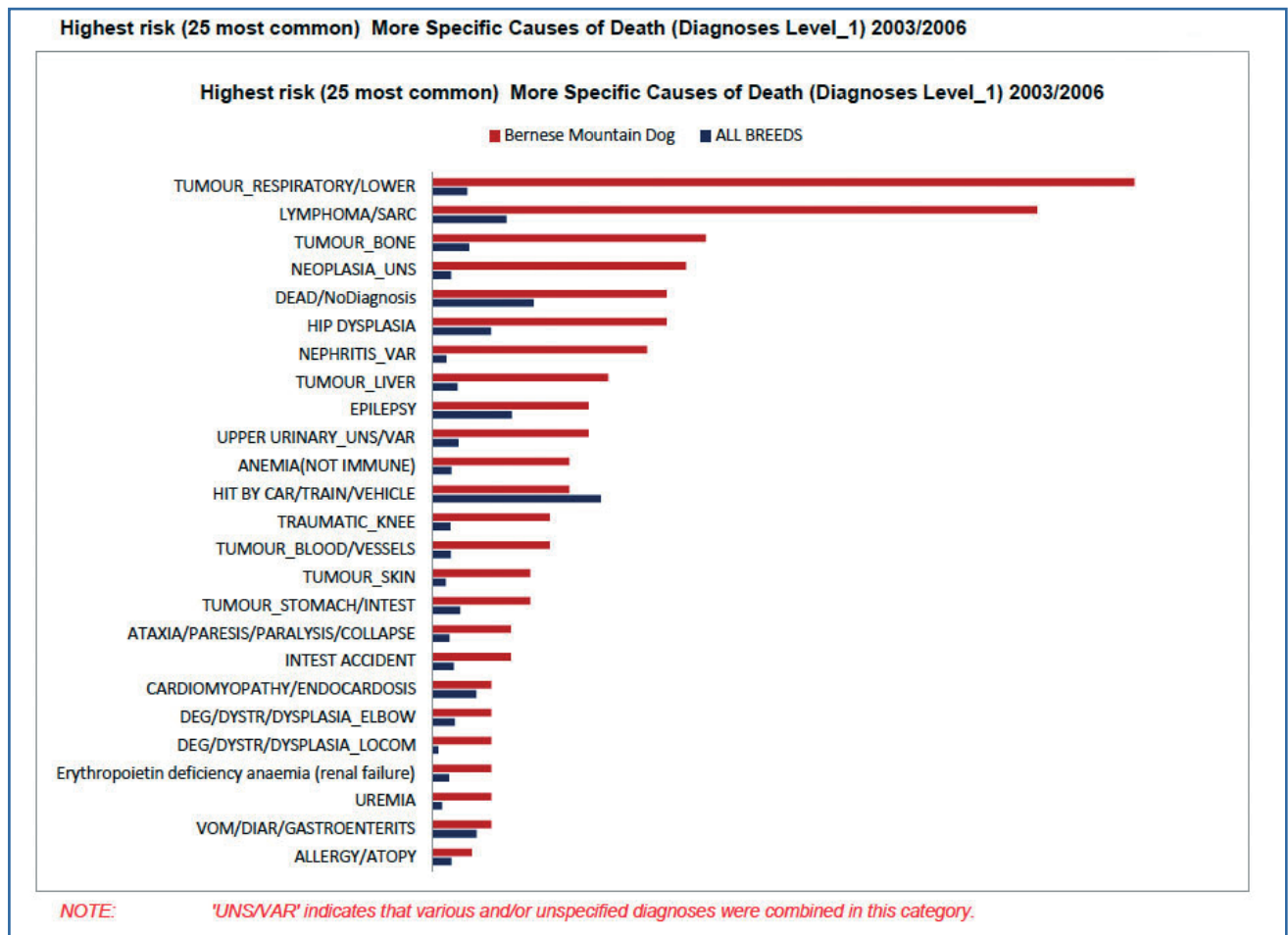


Fig 1 An example of an Agria breed profile

and the insurance companies. Figure 1 shows an example of the pattern of morbidity and mortality in one breed as revealed by insurance data. A recent paper describes a specific disease pattern that has been derived from a large insurance database in German shepherd dogs [30]. More data from Agria Insurance on various breed disease profiles is shown in Fig 1 and more are available at <http://www.agria.se/agria/artikel/agria-dog-breed-profiles-1> [31].

In Britain, a practice-based data collection system has recently been put in place and is being further developed to measure and characterise disease issues in dogs e.g. epilepsy.[31]

## The role of our profession

In our professional duties as small animal veterinarians preventive measures to control the spread of genetic disorders as described above are gaining increasing attention and importance. We are able assist in the selection of breeding stock by diagnosing clinical entities and screening for early signs. To reveal their inherited

nature we are collaborating with geneticists and breeders. To arrange for screening programmes and certification we need to ideally work together with the national cynological organisations. An increasing interest in preventive measures and animal welfare calls for a closer tie with other stakeholders in these measures.

As an example of earlier collaborations between the veterinary and the cynological organisations it should be noted that as early as 1967, at the WSAVA congress in Paris, the late Professor Saki Patsaama reported on the breed standards that encouraged exaggerated anatomical features and an increased risk of various health problems [33]. The report was prepared for WSAVA in close collaboration with veterinarians serving European Kennel Clubs.

The long-time work on hip dysplasia in many countries [i.e. 34,35] and the work of The International Elbow Working Group [36] are other good examples of how the veterinary profession, in collaboration with geneticists and breeders, have contributed to enhanced genetic health by the launching of a screening programme.

In Europe several Kennel Clubs also have arranged for various screening programmes in collaboration with the veterinary profession. However, the extent to which and to who is in charge of the registries does vary. Most commonly liaison committees are formed as i.e. the British BVA/KC Health Schemes for hip dysplasia, elbow dysplasia, and inherited eye diseases. These schemes have been developed over more than 30 years, and aim to provide scientifically based expert opinion on these inherited conditions <sup>[37]</sup>.

In the USA the OFA registry (funded by the late John M Ohlin and designed by veterinarians) was originally intended to register just hip scoring results in USA, but has now developed into a registry for various hereditary diseases and is partly accessible by the public. Dogs can be linked by their registration number in the American Kennel Club (AKC) <sup>[38]</sup>.

In the USA a Canine Health Information Centre (CHIC) has also been formed as a centralised canine health database jointly sponsored by the AKC Canine Health Foundation (CHF) and the Orthopaedic Foundation for Animals (OFA). CHIC, working with participating parent associations, provides a resource for breeders and owners of purebred dogs to research and maintain information on the health issues prevalent in specific breeds <sup>[39]</sup>.

A special issue of the Veterinary Journal (formerly British Veterinary Journal) on hereditary defects in dogs features several review articles on issues related to control measures against hereditary disorders in dogs <sup>[40]</sup>.

The veterinarian's role should also include providing information and education on health issues. Within the framework of the Advisory Council on the Welfare of Dog Breeding [www.apgaw.org/images/](http://www.apgaw.org/images/) <sup>[41]</sup>, Sheila Crispin as chairman, has produced educational material on ocular conditions which are linked to head conformation <sup>[42]</sup>.

With active participation and by supplying background information on diseases, veterinarians have been involved in producing resources such as the DVD produced by the Swedish Kennel Club describing how show judges can evaluate features of brachycephaly. This video, Making assessments of dogs' respiration, can be accessed on [http://www.youtube.com/watch?v=kQ\\_3f4bLkME&feature=youtu.be](http://www.youtube.com/watch?v=kQ_3f4bLkME&feature=youtu.be) <sup>[43]</sup>.

Veterinarians from all parts of the world with an interest

in canine genetics and breeding actively participated in the 1st International Workshop on Enhancement of Genetic Health in Pedigree Dogs arranged in Stockholm in 2012.

*Further information on this event is detailed in the box below*

#### **The 1st International Workshop on Enhancement of Genetic Health in Pedigree Dogs**

In June 2012 an international Workshop on issues related to canine genetic health was arranged by the Swedish Kennel Club in conjunction with the 6th international conference on "Advances in Canine and Feline Genomics and Inherited Diseases". About 150 stakeholders from 20 countries that share a responsibility for dog health gathered in Stockholm to discuss key issues with relevance to canine genetic health. More than 30 veterinarians participated to discuss with geneticists and representatives of cynological and welfare organisations and governmental bodies to work collaboratively on seven key issues for the enhancement of canine genetic health.

Seven key issues were discussed at the Dog health workshop. The issues discussed were:

- Prerequisites and procedures for international recognition of breeds and varieties
- Harmonisation of screening procedures and certifications
- Validation and utilisation of genetic tests in dog breeding
- Interventions for anatomical soundness and avoidance of extreme phenotypes
- Development of breed-specific breeding programs on national and international levels
- Selection for behavioural traits
- Formation of national and international platforms for collaborative efforts

Based on presentations and the more extensive notes on the discussions of each issue, a proposed list of actions has been prepared. The background information as well as the proposals for each issue can be accessed at <http://www.skk.se/in-english/dog-health-workshop-2012/dog-health-workshop/>

It was concluded that all issues should be addressed by more than one stakeholder but specific leaders were proposed for further development. While the cynological organisations were proposed to be in charge of matters related to the international recognition of breeds and measures to counteract exaggerations of anatomical



features, the veterinary profession was elected to take the lead in the validation of screening programmes and the appointment of a group to propose validation of molecular genetic testing. For further information on the development regarding each issue please follow the links indicated above. Hopefully much of this will have happened before the 2nd International Workshop on Enhancement of Genetic Health in Purebred Dogs that is arranged in Düsseldorf by the German Kennel Club on May 31st to June 1st, 2014.

## Our prime responsibilities as vets

Much of the work that is needed must come from, or at least be supported by, veterinary professionals in their various roles. The following section of this paper outlines specific needs or areas of development and how veterinarians might support them.

### We have a responsibility to:

- **Diagnose and treat**

As practicing veterinarians our prime responsibility is to cure whenever possible and at least to give symptomatic relief. For hereditary diseases, which most commonly are congenital and/ or developmental or metabolic and/ or degenerative, it is usually not possible to cure. It is however equally important to come up with an aetiology based diagnosis. Even if it is not possible to permanently cure these conditions, it is of upmost importance for any breeding advice to be given for the benefit of future generations.

- **Assist in control and prevention**

As small animal practitioners we are becoming more and more involved in preventive measures. In the case of hereditary diseases this is mainly to assist in the performance of various screening programmes and in the registration of verified cases of genetically defined diseases. Specialists in various sub-disciplines are also involved in the introduction and design of screening procedures and health programmes. It is crucial to establish such programmes in close collaboration with geneticists as well as with kennel and breed clubs. Geneticists must ensure that what is screened for must have a reasonably well-known and strong enough genetic background to enable the Kennel Club and breed societies to ensure its proper registration and use.

A breed club that collaborates well is the key both for success and a balance against other health problems within the breed. We as veterinarians should guarantee that proper inclusion/ diagnostic criteria are used for screening procedures as well as for the inclusion in the registers of identified cases.

Much of our involvement in the past has been in various screening programmes to detect heritable phenotypes that may result in clinical problems such as hip dysplasia and elbow dysplasia, blindness, or heart failure. Based on the assembly of phenotypic data for potential breeding stock, progeny can be selected to reduce the indicated phenotype as well as resulting clinical problems. Lately our profession, more secondarily, has been involved in genotypic screening programmes based on molecular genetic testing which enables selection not only by avoiding indicated or clinically affected phenotypes but also by identifying individuals carrying unfavourable genotypes.

By using screening programmes it is often possible to identify and register affected as well as non-affected individuals. Besides registries for formal screening programmes there are registries that just contain information on verified clinical cases. To identify some hereditary eye defects we need to look somewhere in between these two types of registries. For example, screening for glaucoma and lens luxation is included in screening programmes for hereditary eye defects but most cases are identified just by their clinical onset.

There is a difference between registries where "affected" as well as "non-affected" individuals are identified compared to those which only identify either affected or non-affected individuals. Many registries, for good reasons, contain only identified cases with certain diagnostic criteria but with lack of the potential to identify the status in the rest of an affected population, i.e. renal dysplasia which requires a post mortem examination. Registries of just unaffected /clear individuals that have been common in the past have a much more limited value as have the ones which are not open to the public.

To be effective, results from screening programmes have to be registered in a fashion that enables their practical usage. That is, linked to ancestral background and open to the public regarding positive as well as negative results.

Some of the hereditary eye defects have to be screened for repeatedly over time to make sure that they haven't become evident at a later stage of life. Screening for hip and elbow dysplasia rests on the prediction of clinical status based on a standardised procedure early in life that only has to be performed once.

*Further information on the difference between screening for compared with diagnosing inherited disorders is detailed in the box below.*

### Screening for versus diagnosing inherited disorders

Most phenotypic screening programmes are based on an ability to predict at an early age if a dog is going to develop an inherited disorder. Hip dysplasia is a typical example, where initially early palpation and later a standardised radiograph has been proven to indicate if a dog will develop clinical signs by a deviation from normality regarding laxity and form of the hip joint. It was originally used primarily to predict the clinical outcome for dogs to be used for military service. Since the result from this screening procedure was shown to be heritable it is nowadays mostly seen as a tool to select the breeding stock. The breeding stock is selected to decrease the prevalence of hip dysplasia; dogs with clinically evident as well as milder forms that might not cause clinical problems are deemed to be less suitable for breeding due to the potential for inheritance<sup>[44]</sup>.

Ideally a screening procedure should be easy and inexpensive to perform and thereby widely used in the selection of breeding stock. Ideally it should also be possible to predict at an early age – before breeding – if a dog ever is going to develop the entity selected for.

Phenotypic screening and breeding indexes are based on the possibility to evaluate “affected” as well as “non-affected” individuals and thereby depict the population. Some registries on inherited disorders are not really based on a screening procedure but rather just on diagnosed cases. For example, based on histopathological features, it is not possible to screen for the absence of renal dysplasia in the rest of the population.

Even if screening procedures are primarily intended for a prediction of clinical outcome it is not uncommon that specific clinical entities are revealed. Screening for elbow dysplasia may reveal a fragmented coronoid process causing arthrosis. To reveal as much as possible from a diagnostic procedure more and more sophisticated procedures have been developed to diagnose hip as well as elbow dysplasia. Whether or not these procedures should also be performed in a screening program is a balance between accuracy and cost.

By extensive screening not only of potential breeding stock but also of as many relatives as possible it is possible by performing a calculation of breeding indexes to reveal the genotype of an individual intended for breeding much more accurately than by any more sophisticated phenotypic screening procedures.

- **Investigate and reveal the aetiology**

It is the prime responsibility of researchers within the field of small animal medicine to reveal the aetiology of a conditions, and bearing this in mind, to evaluate regimes for their treatment. With the recent resolution of the entire canine genome an extra dimension has been added to research on canine genetic diseases as has been the case in human health following the discovery of the human genome. To take full advantage of the knowledge about the canine genome, reliable validated case reports and Controls for various inherited diseases have to be assembled with the support and assistance from

veterinary practitioners in general and referral practice alike.

Numerous veterinarians in Europe, both researchers and practicing veterinarians, have been involved in an extensive search for the molecular genetic background of several diseases seen in dogs as well as in man within the framework of a EU project named LUPA after the wolf that nourished Romulus and Remus<sup>[45]</sup>.

*For more details on the LUPA project see the box on the following page*

**LUPA – a European veterinary challenge**

This is an extensive collaboration of canine genetic-scientists from 20 academic institutions in 12 European countries and numerous European veterinarians who are unravelling the molecular basis for common human diseases using information gained from studying a large number of hereditary conditions in Dogs. With EU funding from the FP 7 health call, cases of cancer, heart disease, neurological, immunological, and endocrine disorders have been thoroughly investigated and compared with healthy controls to reveal the molecular genetic basis of the (mostly complex) diseases seen in large numbers in dogs as well as in man.

Table 2 Examples of Diseases studied in the LUPA project

Mammary tumour
Soft Tissue Sarcoma
Diabetes Mellitus
Atopic dermatitis (eczema-skin disease)
Hypothyroid disease
Resistance or sensitivity to Leishmaniosis
Dilated cardiomyopathy
Myxomatous mitral valve disease
Cardio-vascular physiologic parameters
Epilepsy in numerous breeds
Aggressive behaviour
Meningoencephalitis in the Greyhound
Exocrine pancreas insufficiency
Keratitis punctata
Copper-associated disease
Extra-hepatic porto systemic shunt
Idiopathic pulmonary fibrosis
Glomerulopathy
Naso-digital keratosis

- **Share our experience and knowledge**

It is of great importance for the enhancement of canine genetic health for general practitioners, clinical specialists and researchers to share their experiences and knowledge regarding canine diseases and the factors that may influence their occurrence and severity.

Our contribution could be through presentations at meetings organised by breed clubs in addition to our assistance in the preparation of educational material for breeders, judges, and officers at various levels within the cynological organisations. Veterinary contributions in breed magazines are usually highly appreciated.

## Tasks depending on our different backgrounds and function

Due to our different training and the positions in which we work, our roles and responsibilities for canine genetic health may vary. However, it is becoming evident that we all can contribute with our special skills and experiences.

- General Practitioners are the veterinarians with the greatest exposure to various health problems with a genetic background. Those in general practice are seeing a wide variety of cases and those specialising in a discipline often see a large number within their field of specialisation. Regular contact with the owners of affected dogs should be used not only to relieve suffering in the individual animal but also to inform owners and breeders about an animal's suitability for breeding, thereby avoiding causing more animals to suffer from the same condition. To have such a discussion is of course most appropriate with dog owners who are also breeders. However, in many European countries it is common that "ordinary dog owners" occasionally allow their pets to produce litters of puppies. In fact in many countries and breeds these owners make a big contribution to the number of litters produced each year.
- Practicing specialists are commonly involved in various screening programmes for hereditary disorders and thereby play a very important role as the "launcher" of these programmes.

As sampling for molecular genetic testing can be performed by any practicing veterinarian we should all be

more aware these screening programmes. However, the rapid development in this field makes this difficult and almost impossible. Cynological organisations as well as professional bodies should try to persuade and help vets in practice to gather and provide relevant information.

- Practicing veterinarians involved in reproduction and paediatrics also have a special exposure to breeders – both to those with experience as well as to others with very little experience. At whelping it is appropriate to discuss whether or not a bitch is suitable for further breeding. Neonatal puppy inspections might also reveal inherited conditions to be considered with reference to further breeding.

In some countries including Sweden it is already common practice to have all puppies “inspected” before delivery to their new home. In UK special puppy contracts have recently been launched.

*More details of these are given in the box below*

#### **Vet checks -Inspection of puppies before delivery to the owner**

In a couple of European countries, including Sweden, it is already a mandatory requirement of the national Kennel Clubs that puppies should have a veterinary certificate proving their health status at the time of sale. The primary focus of these certificates has been to avoid the spread of infectious diseases. With increasing attention to exaggerated anatomical features it is logical to extend these examinations to include an inspection of clinical signs that can be related to adverse anatomical features. However, dentition, bite, length of skull etc change rapidly in the growing animal and therefore it is difficult to evaluate these in an 8 week old puppy. The veterinary evaluation might therefore preferentially be limited to clinical signs of discomfort.

- Veterinarians at academic institutions and other vets involved in research are playing an increasingly important role by applying their results to practical dog breeding and promoting the notable value of canine research in comparative studies for the benefit of humans.

Nowadays, some kennel clubs have veterinarians and / or geneticists employed full-time to assist in matters related to health and breeding. When considering specific areas, others have veterinary and genetic consultants employed on a part time basis for assistance in breeding e.g. on hip, elbow and eye panels.

- Veterinarians with dual roles.

As a result of their involvement in breeding, breed clubs, dog “sports” including showing, and as consultants, many veterinarians are strongly involved in the cynological organisation in various functions. Veterinarians commonly serve on health committees and not uncommonly as presidents of breed clubs and even the national Kennel Clubs. Veterinarians involved in breed clubs have a responsibility to act as a bridge between the profession and the “cynological” world.

- The Professional organisations
  - At an international and regional level WSAVA and FECAVA and at national levels the national FECAVA member organisations should promote collaborative efforts, i.e. to work together with the cynological organisations in the set- up of screening programmes and registries.
  - As specialist organisations the European colleges should serve as authorities to validate diagnostic criteria and procedures in their special area of competence.
  - The WSAVA Hereditary Disease Committee has just launched a web tool to provide information on molecular genetic testing in dogs and cats. It contains Contact information about the laboratories performing these tests and outlines the specific tests available and the breeds affected. It can be searched by laboratory, test or breed <http://wsava.org/educational/hereditary-diseases-committee> <sup>[25]</sup>.
  - Specific information about the genetic test including the mutation, gene and chromosome involved is also provided when available, as are links or citations to available research and references to the Online Mendelian Inheritance in Animals (OMIA)<sup>[19]</sup> and Online Inheritance in Man (OMIM)<sup>[20]</sup> numbers if appropriate.



## Conclusion

Proposed stronger involvement by the veterinary profession

1. That the veterinary profession takes a more active part in pre-breeding inspections and advice regarding potential breeding stock.
2. That the veterinary profession is involved in the launching of puppy health certificates.
3. That veterinarians as well as discussing routine procedures for individuals such as microchipping, vaccinations, flea control and de-worming, also communicate as to whether an individual is suitable for breeding or not.
4. That the veterinary profession, by introduction in the curriculum, is better prepared to take a more active part in providing breeding advice related to screening procedures they are involved in.
5. That the profession nationally and internationally takes an active role in collaborative efforts with other stakeholders for the enhancement of canine genetic health.

## References

- [1] Hagman F. Pure breed dogs worldwide. *Veterinary Focus*. 2007; 17:2
- [2] Bellumori T.P., Famula T.R., Bannasch D.L., Belanger J.M., Oberbauer A.M. Prevalence of inherited disorders among mixed-breed and purebred dogs: 27,254 cases (1995-2010). *J Am Vet Med Assoc*. 2013; 242(11):1549-55
- [3] de Caprona M.D.C., Savolainen P. Extensive phenotypic diversity among South Chinese dogs. *ISRN Evolutionary Biology*. 2012; Article ID 621836.
- [4] Stockard C.R., Andersson O.D., James W.T. The genetic and endocrine basis for differences in form and behavior, as elucidated by studies of contrasted pure-line dog breeds and their hybrids. The Wistar Institute of Anatomy and Biology, PA, Pennsylvania. 1941.
- [5] Hedhammar, Å. European strategies to enhance canine genetic health. *European Journal of Companion Animal Practice*. 1999; 9:93.
- [6] Hedhammar, Å. Actions by FCI and WSAVA to promote canine genetic health. *European Journal of Companion Animal Practice*. 2005; 15:22-25.
- [7] Hedhammar Å., Malm S., Bonnett B. International and collaborative strategies to enhance genetic health in purebred dogs. *Vet J*. 2011; 189(2):189-96
- [8] Kijas J.M., Bauer T.R. Jr, Gáfvert S., Marklund S., Trowald-Wigh G., Johannisson A., Hedhammar A., Binns M., Juneja R.K., Hickstein D.D., Andersson L. A missense mutation in the beta-2 integrin gene (ITGB2) causes canine leukocyte adhesion deficiency. *Genomics*. 1999; 61(1):101-7
- [9] Downs L.M., Wallin-Håkansson B., Boursnell M., Marklund S., Hedhammar Å., Truvé K., Hübner L., Lindblad-Toh K., Bergström T., Mellersh C.S. A Frameshift Mutation in Golden Retriever Dogs with Progressive Retinal Atrophy Endorses SLC4A3 as a Candidate Gene for Human Retinal Degenerations. *PLoS One*. 2011;6:6
- [10] Ferm K., Björnerfeldt S., Karlsson Å., Andersson G., Nachreiner R. and Hedhammar Å. Prevalence of diagnostic characteristics indicating canine autoimmune lymphocytic thyroiditis in giant schnauzer and hovawart dogs. *Journal of Small Animal Practice*. 2009; 50(4):176-179
- [11] Nødtvedt A., Egenvall A., Bergvall K., Hedhammar Å. Incidence of and risk factors for atopic dermatitis in a Swedish population of insured dogs. *Vet Rec*. 2006;159:241-246.
- [12] Fall T., Hamlin Hansson H., Hedhammar Å., Kämpe O., Egenvall A. Diabetes mellitus in a population of 10,000 insured dogs 2007 incidence, survival and breed distribution. *J Vet Intern Med*. 2007; 21(6):1209-16
- [13] Bonnett, B.N., Egenvall, A., Olson, P., Hedhammar, Å. Mortality in insured Swedish dogs: Rates and causes of death in various breeds. *Veterinary Record*. 1997; 141:40-44.
- [14] Bonnett, B.N., Egenvall, A., Hedhammar, Å., Olson, P. Mortality in over 350,000 insured Swedish dogs from 1995-2000: I. Breed-, gender-, age- and cause-specific rates. *Acta Veterinaria Scandinavica*. 2005; 46:105-120.
- [15] Fleming J.M., Creevy K.E., Promislow D.E. L. Mortality in North American Dogs from 1984 to 2004. An Investigation into Age-, Size-, and Breed-Related Causes of Death *J Vet Intern Med*. 2011; 25:187-198
- [16] Collins, L.M., Asher, L., Summers, J., McGreevy, P. Getting priorities straight: Risk assessment and decision-making in the improvement of inherited disorders in pedigree dogs. *The Veterinary Journal*. 2011; 189(2):147-54.
- [17] CIDD (2011) Canine Inherited Disorders Database. [www.upei.ca/cidd](http://www.upei.ca/cidd)
- [18] Bateson, P. Independent Inquiry into Dog Breeding. Micropress, Halesworth, Suffolk, UK, 64 pp. [www.breedinginquiry.files.wordpress.com/2010/01/finaldog-Inquiry-120110.pdf](http://www.breedinginquiry.files.wordpress.com/2010/01/finaldog-Inquiry-120110.pdf). 2010
- [19] OMIA 2013 Online Mendelian Inheritance in Animals. [omia.angis.org.au](http://omia.angis.org.au)
- [20] OMIM 2013 Online Mendelian Inheritance in Man. <http://www.ncbi.nlm.nih.gov/omim>
- [21] Karlsson, E.K., Baranowska, I., Wade, C.M., Salmon Hillbertz, N.H.C., Zody, M.C., Anderson, N., Biagi, T.M., Patterson, N., Pielberg, G.R., Kulbokas, E.J., Comstock, K.E., Keller, E.T., Mesirov, J.P., von Euler, H., Kämpe, O., Hedhammar, Å., Lander, E.S., Andersson, G., Andersson, L., Lindblad-Toh, K. Efficient mapping of Mendelian traits in dogs through genome-wide association. *Nature Genetics*. 2007;

- 39:1321–1328.
- [22] Lander E.S. et al. Initial sequencing and analysis of the human genome. *International Nature*. 2001; 409(6822):860–921.
- [23] Patersson A Catalogue of hereditary diseases of the dog. In *Current Veterinary Therapy*. V ed. 1975. p 61
- [24] Nicholas, F.W., Crook, A., Sargan, D.R. Internet resources cataloguing inherited disorders in dogs. *Vet J*. 2011; 189(2):132–5
- [25] Slutsky J, Raj K, Yuhnke S, Bell J, Fretwell N, Hedhammar A, Wade C, Giger U. (2013) A web resource on DNA tests for canine and feline hereditary diseases. *Vet J*. 2013 Apr 10. pii: S1090-0233(13)00083-X. doi: 10.1016/j.tvjl.2013.02.021. [Epub ahead of print]
- [26] Butler L.M., Bonnett B.N. and Page R.L., Chapter 4 Epidemiology and the Evidence-Based Approach, in *Withrow and MacEwen's Small Animal Clinical Oncology*. Elsevier Saunders, 3251 Riverport Lane, St. Louis, Missouri 63043. 2011. p 71–72,
- [27] Dodds W.J. Estimating disease prevalence with health surveys and genetic screening. *Adv Vet Sci Comp Med*. 1995; 39:29–96
- [28] Swenson L., Audell L., Hedhammar A. Prevalence and inheritance of and selection for hip dysplasia in seven breeds of dogs in Sweden and benefit: cost analysis of a screening and control program. *J Am Vet Med Assoc*. 1997; 210(2):207–14.
- [29] Dobson J.M., Milstein S.S., Rogers K., Wood J.L. Canine neoplasia in the UK: estimates of incidence rates from a population of insured dogs. *J Small Anim Pract*. 2002; 43:240–246.
- [30] Vilson A., Bonnett B., Hamlin H., Hedhammar A. Disease patterns in 32,486 insured German Shepherd Dogs in Sweden: 1995–2006. *Vet. Rec*. 2013; 29.
- [31] Agria Dog Breed Profiles (ADBP) 2011 <http://www.agria.se/agria/artikel/agria-dog-breed-profiles-1>
- [32] Kearsley-Fleet L., O'Neill D.G., Volk H.A., Church D.B., Brodbelt D.C. Prevalence and risk factors for canine epilepsy of unknown origin in the UK. *Vet Rec*. 2013; 172(13):338.
- [33] Anonymous Report of the World Small Animal Veterinary Association Committee appointed to consider breed standards in relation to the health and Welfare of dogs. *Journal of Small Animal Practice*. 1969; 10:135–141
- [34] Lewis, T.W., Blott, S.C., Woolliams, J.A. Genetic evaluation of hip score in UK Labrador retrievers. *PLoS one*; 2010; 5
- [35] Anutta V., Hamann H., Distl O. Genetic and phenotypic trends in canine hip dysplasia in the German population of German shepherd dogs. *Berl Munch Tierarztl Wochenschr*. 2008; 121(3–4):102–9
- [36] IEWG 2013. International Elbow Working Group. [www.iewg-vet.org](http://www.iewg-vet.org)
- [37] Changes to the BVA/KC Canine Health Schemes [www.bva.co.uk/chs](http://www.bva.co.uk/chs)
- [38] OFA 2011 Orthopedic Foundation for Animals. [www.offa.org](http://www.offa.org)
- [39] CHIC 2013 Canine Health Information Centre <http://www.caninehealthinfo.org/>
- [40] Nicholas F.W., Wade C.M. Canine genetics: A very Special Issue. *The Veterinary Journal*. 2011;189 (2):123–125
- [41] APGAW, 2009 A Healthier Future for Pedigree Dogs. [www.apgaw.org/images/stories/PDFs/a-healthier-future-for-pedigree-dogs.pdf](http://www.apgaw.org/images/stories/PDFs/a-healthier-future-for-pedigree-dogs.pdf)
- [42] Crispin S. Ocular problems linked to head conformation The Advisory Council on the Welfare Issues of Dog Breeding. 2012; May 8th
- [43] Breathing DVD Making assessments of dogs' respiration. Accessible at [http://www.youtube.com/watch?v=kQ\\_3f4bLkME&feature=youtu.be](http://www.youtube.com/watch?v=kQ_3f4bLkME&feature=youtu.be)
- [44] Malm, S., Fikse, W.F., Egenvall, A., Bonnett, B.N., Gunnarsson, L., Hedhammar, Å., Strandberg, E. Association between radiographic assessments of hip status and subsequent incidence of veterinary care and mortality related to hip dysplasia in insured Swedish dogs. *Preventive Veterinary Medicine*. 2010; 93:222–232
- [45] Lequarré A.S., Andersson L., André C., Fredholm M., Hitte C., Leeb T., Lohi H., Lindblad-Toh K., Georges M. LUPA: a European initiative taking advantage of the canine genome architecture for unravelling complex disorders in both human and dogs. *Vet J*. 2011; 189(2):155–9.
- [46] IDID (2013) Inherited Diseases in Dogs. [www.vet.cam.ac.uk/idid](http://www.vet.cam.ac.uk/idid)

## Additional web resources

Proceedings of the 35th World Small Animal Veterinary Congress WSAVA 2010 Geneva, Switzerland – 2010

Reprinted in IVIS with the permission of WSAVA

B17 BREED, SEX AND AGE AS RISK FACTORS FOR VARIOUS DISEASES IN DOGS

<http://www.ivis.org/proceedings/wsava/2010/b17.pdf>

B20 CANINE BREED RELATED DISEASES AS A RESOURCE FOR COMPARATIVE STUDIES

<http://www.ivis.org/proceedings/wsava/2010/b20.pdf>

SPECIAL BREED SPECIFIC INSTRUCTIONS (BSI) REGARDING EXAGGERATIONS IN PEDIGREE DOGS

<http://www.skk.se/Global/Dokument/Utstallning/special-breed-specific-instructions-A8.pdf>



## COMMISSIONED PAPER (UK)

# Hereditary Ocular Disease in the dog

Peter G C Bedford<sup>1</sup>

## SUMMARY

The spectrum of inherited ocular disease in today's pedigree dog population is a relatively complex one with many breeds and all parts of the eye being involved. Fortunately most of the diseases are well recognized clinically and the appearance of new genetically determined disease is unusual in today's world. It is the emergence of known disease in new breeds that evokes the additional concern. The overall picture tends to vary from country to country, to some extent reflecting variable levels of awareness and concern within individual states. In the United Kingdom, for example, fifty eight of the two hundred and ten breeds currently Kennel Club registered are involved in fourteen primary ocular disease conditions. Unfortunately accurate incidence figures for most of these diseases are rarely available due to an insufficiency of breeder subscription to both official and breed club examination schemes, together with a lack of feedback from veterinary clinical practice. Another forty nine breeds are potentially involved where the incidence of an ocular defect of possible hereditary nature is greater than random selection would allow. The avoidance of genetically determined disease should be of high priority in the production of sound dogs of good temperament. It is difficult to prescribe the panacea that would eradicate this category of disease, but there is no doubt that the rapid appearance of DNA based tests together with routine eye examination as part of any kennel club registration policy will help effect positive change. It is undoubtedly the responsibility of breeders and the breed societies to ensure that their breed enjoys a normal healthy existence and the fact that the vast majority of pedigree dogs do is considerable tribute to those concerned breeders who have gone before."

Inherited disease may be congenitally present or develop clinically at any age, but the dye is cast at the time of organogenesis. However distinction has to be drawn between the terms "congenital" and "inherited". The former refers to defect which is present clinically at the time of birth and the latter to any defect which is determined genetically. Thus inherited defects may be present congenitally whilst others do not express themselves clinically until early adolescence or even later in life. It follows that many congenital defects are not inherited but simply occur as the result of the aberrant differentiation of foetal tissue. Although many inherited defects demonstrate clear breed predisposition in the world of the pedigree dog, the exact mode of inheritance for others remains undetermined. The congenital ocular defects which display breed predisposition in the dog are the various types of retinal dysplasia (RD), cataract, the persistence of elements of the primary vitreous (PHPV), the persistence of remnant pupillary membrane (PPM) and the various lesions of the Collie Eye Anomaly (CEA). Inherited disease which develops clinically some time after birth may be referred to as developmental disease, although, strictly speaking, the term "developmental" refers to the process of organogenesis. There are several such developmental ocular diseases in the pedigree dog and these include the various eyelid and other adnexal abnormalities, hereditary cataract (HC), lens luxation (PLL), primary glaucoma, progressive retinal atrophy (PRA) and retinal pigment epithelial dystrophy (RPED). It is obvious that within this group the conformational abnormalities that are responsible for anomalies of the palpebral fissure are there by design based on desire to reproduce an appearance specific to the breed and that revised breed standards are required to effect correction. The other diseases in this group have been unwittingly co-selected as breeders have concentrated within certain lines to select for various desired features. For example, PRA in the Miniature and Toy Poodle breeds may have appeared initially as the result of selection for, say, a particular desired anatomical feature or for good temperament. Sadly the PRA mutation was unwittingly co-selected in those lines together with the desired feature. There are clear indications that several other ocular abnormalities may also prove to be inherited and this group includes corneal lipidosis, the uveo-dermatological syndrome and the pigment dispersal syndrome.

This paper was commissioned by FECAVA for  
The Special issue of EJCAP, Genetic/Hereditary  
Disease and Breeding.

1 Emeritus Professor of Veterinary Ophthalmology, Royal Veterinary College Hawkshead Lane, North Mymms, Hatfield, Hertfordshire, GB-AL9 7T  
E-mail: ispec@btinternet.com

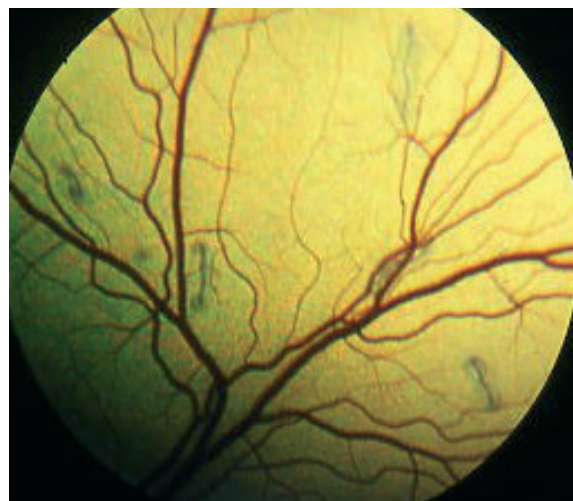


## Congenital inherited disease

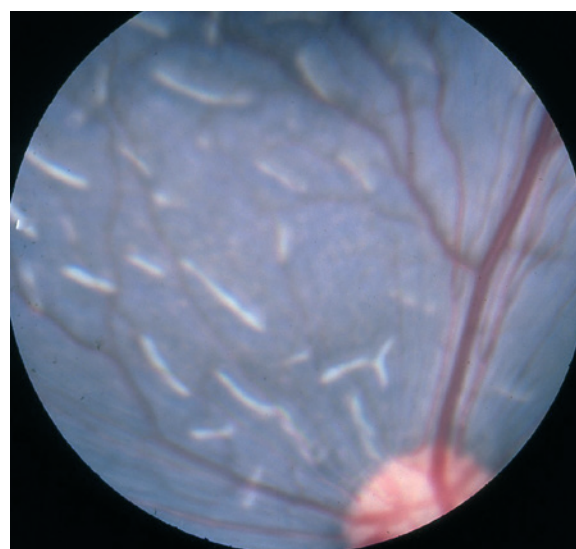
### Retinal Dysplasia

The term retinal dysplasia (RD) is commonly used to describe those inherited retinal conditions which are seen clinically as either neuroretinal folds or neuroretinal non-attachment [1-4]. It should be remembered however that within the progressive retinal atrophy complex (PRA) there are both rod and cone photoreceptor dysplasias in the Irish Setter, Rough Collie and Sloughi and a rod dysplasia accompanied by cone degeneration has been recorded in the Norwegian Elkhound. For continuity reasons these conditions are discussed under PRA later in this paper.

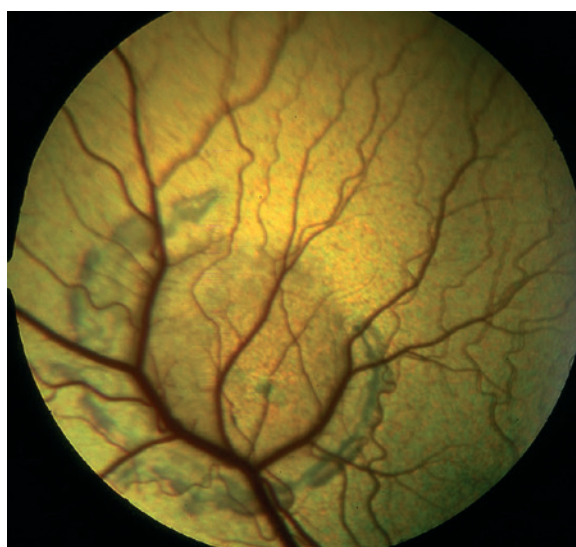
The simplest manifestation of R.D. is seen as neuroretinal folds, the affected tissue being separated from the underlying retinal pigment epithelium (RPE) (Fig.1). Within a fold there should be abnormal proliferation of photoreceptor elements to justify the term dysplasia and differentiate this disease from the simple neuroretinal folds classically seen in the Shetland Sheepdog which disappear during early post natal development. In the puppy with RD the whole of the fundus may be involved (Fig.2), but in the affected adult the folds are normally restricted to the tapetal fundus. With the passage of time some folds may be rendered ophthalmoscopically inapparent, their presence being eventually replaced in later life by patches of retinal degeneration. The disappearance of folds from both the puppy and adult fundus can lead to difficulties in the explanation of a diagnosis on occasion and the development of a DNA test would be most helpful. This form of R.D. is referred to as multifocal retinal dysplasia (MRD) and is inherited in the Cavalier King Charles Spaniel (CKCS), the Hungarian Puli, the Golden Retriever (GR), the Labrador Retriever (LR) and the Rottweiler as a recessive trait. In some of the affected in the CKCS, the GR and the LR breeds the folds may be concentrated within a single circular locus in the tapetal fundus. Unilateral involvement is more commonly seen and here the disease is referred to as geographic retinal dysplasia (GRD)(Fig.3). In MRD seen in the English Springer Spaniel the neuroretinal folds may be accompanied by retinal degeneration, these lesions taking on the appearance of classical post-inflammatory retinopathy due to their increased tapetal reflectivity and the presence of melanin pigmentation (Fig.4). Occasionally retinal detachment complicates this clinical picture in this breed and both intraocular haemorrhage



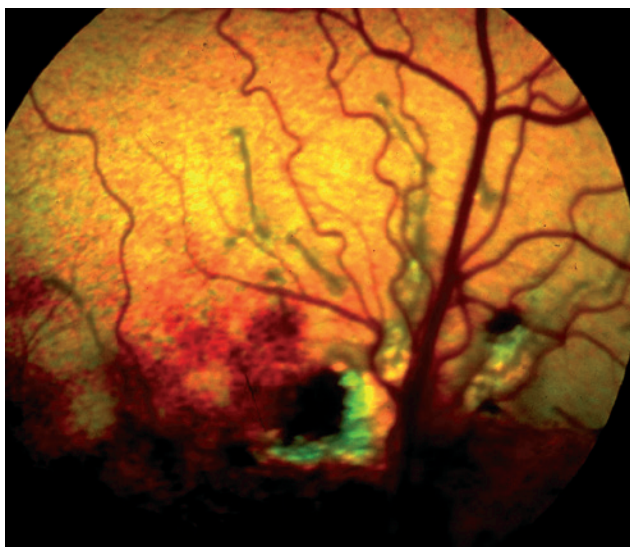
*Fig. 1 Multifocal retinal dysplasia (MRD). Right eye. Golden Retriever. 4 years. Both linear and round neuroretinal folds are seen.*



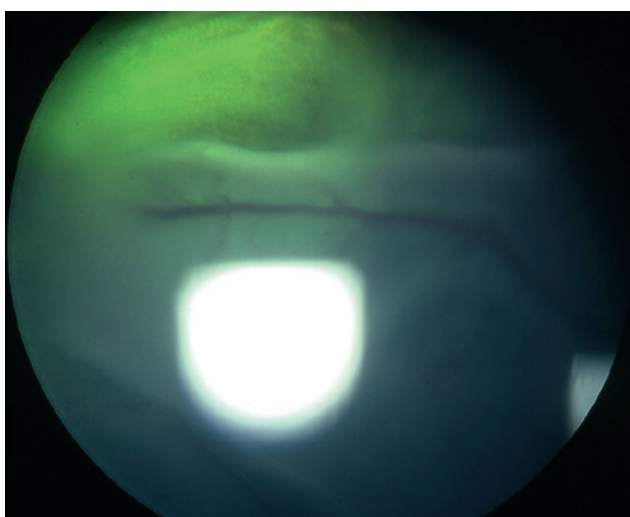
*Fig. 2 Multifocal retinal dysplasia. Left eye. Hungarian Puli. Many grey coloured neuroretinal folds can be seen in this 6 week old puppy.*



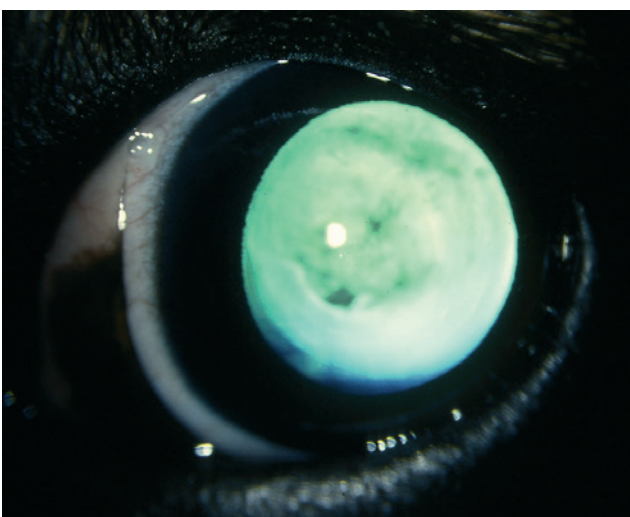
*Fig. 3 Geographic retinal dysplasia (GRD). Labrador Retriever. 2 years. The linear neuroretinal folds are curved and grouped in circular fashion in the midline of the tapetal fundus, right eye.*



*Fig. 4 Multifocal retinal dysplasia. Springer Spaniel. 2 years. Both linear and round folds can be seen above the three areas of increased tapetal hyper-reflectivity in this right eye.*



*Fig. 5 Total retinal dysplasia (TRD) seen as retinal detachment in the right eye of a 4 month old Samoyed. (the circular white mark is the camera flash)*



*Fig. 6 Congenital nuclear cataract (CNC). Left eye. English Cocker Spaniel. 4 months. The cataract is seen as a circular black lesion in the central part of the lens. It appears black as it interrupts the light being reflected from the tapetum.*

and cataract formation may also be seen. The incidence is particularly high in the working strains of this breed and again inheritance is as a simple recessive trait.

Total neuroretinal non-attachment has been described in the Sealyham Terrier, the Bedlington Terrier and the Labrador Retriever, but current incidence is extremely low (Fig.5). In the Labrador Retriever congenital neuroretinal non-attachment may also accompany chondrodysplasia, the affected dogs demonstrating retarded growth of the radius, ulna and tibia. In addition there may be separation of hypoplastic anconeal and coronoid processes, delayed epiphyseal development and hip dysplasia. Hyaloid remnants may be seen and cataract may subsequently develop. A similar entity has been described for the Samoyed.

### **Congenital Cataract**

Cataract is defined as any opacity of the lens and/or its capsule. Congenital inherited cataract always involves the central embryonic and foetal nuclear portion of the lens, whilst those lens fibres which make up the cortex usually remain transparent<sup>[5]</sup> (Fig.6). Thus congenital nuclear cataract is often described as stationary, with the effect on the dog's sight being dictated by the extent of the opacity. Such patients may be managed long term by using long acting mydriatic drugs, but when cortical involvement occurs lens removal may prove necessary. The condition occurs as a recessive trait in the Miniature Schnauzer and it may become established as an inherited entity in the Old English Sheepdog, the Golden Retriever and the West Highland White Terrier unless breeders respond adequately to early findings in these breeds. Congenital nuclear cataract may also accompany microphthalmos, PPM and retinal dysplasia in breeds like the Bloodhound, the Cavalier King Charles Spaniel, the Cocker Spaniel, the Dobermann, the Golden Retriever, the Old English Sheepdog, the Rottweiler, the Rough Collie, the Standard Poodle and the West Highland White Terrier as part of a multi-ocular defect (MOD)<sup>[6]</sup> (Fig.7). Congenital cataract can involve the lens capsule and cortex as a consequent feature of Persistent Pupillary Membrane (PPM) or Persistent Hyperplastic Primary Vitreous (PHPV). Remnant pupillary membrane may render the anterior capsule opaque at the points of attachment whilst varying degrees of posterior capsular opacity and posterior cortical cataract may accompany PHPV.



## Persistent Pupillary Membrane/ Persistent Hyperplastic Primary Vitreous

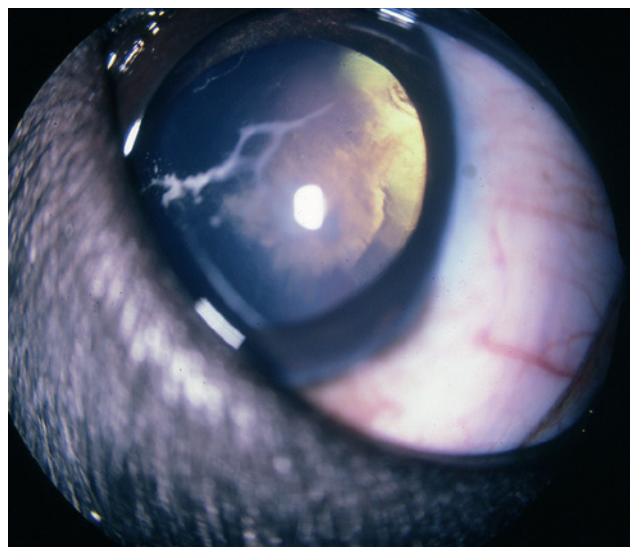
The role of the primary vitreous during organogenesis involves the nutrition of the developing lens through its hyaloid vessel component. The posterior and anterior branches of this vessel together with elements of the annular artery arising from the anterior rim of optic vesicle form a vascular network around the lens, the tunica vasculosa lentis (TVL). At the time of birth all parts of this network should have been resorbed but elements of both the anterior and posterior components may persist. The anterior remnants together with mesenchymal elements are referred to as persistent pupillary membrane (PPM) [7]. The lesions are commonly seen as short strands of tissue attached at one end to the iris collarette or longer strands running across the pupil from collarette to collarette. Occasionally there is adherence to the anterior lens capsule and associated cataract formation (Fig.8). Remnant posterior elements of the TVL may be hyperplastic and have considerable lens involvement (PHPV) [8].

PPM is described as a simple recessive trait in the Basenji, but it is seen as an occasional finding in many other breeds including the Bull Mastiff, the Cocker Spaniel, the Finnish Lapphund, the Lancashire Heeler, the Miniature Wire-haired Dachshund, the Petit Bassett Griffon Vendeen, the Rottweiler, the Siberian Husky and the West Highland White Terrier. In these breeds the mechanism of probable inheritance remains unclear : PPM remnants may also accompany microphthalmos, nuclear cataract and retinal dysplasia in MOD.

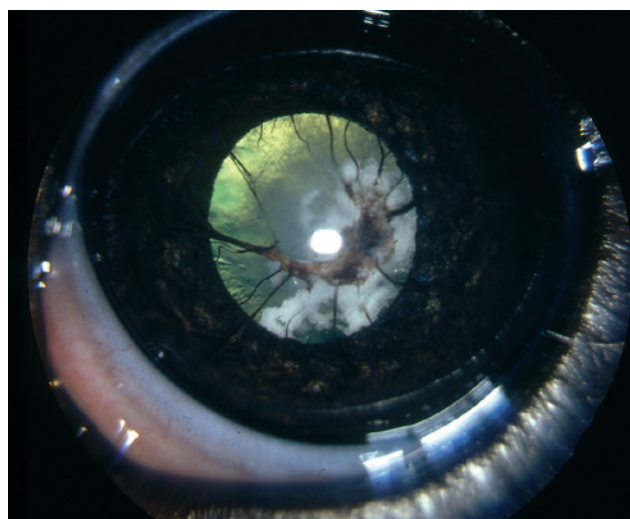
PHPV has been described as a primary defect in the Doberman and in the Staffordshire Bull Terrier. It is possibly inherited as an incomplete dominant trait. The lesions range from small brown particulate opacities of the posterior polar aspects of the capsule to extensive capsular and cortical opacities with occasional intralenticular haemorrhage (Fig.9).

## Collie Eye Anomaly

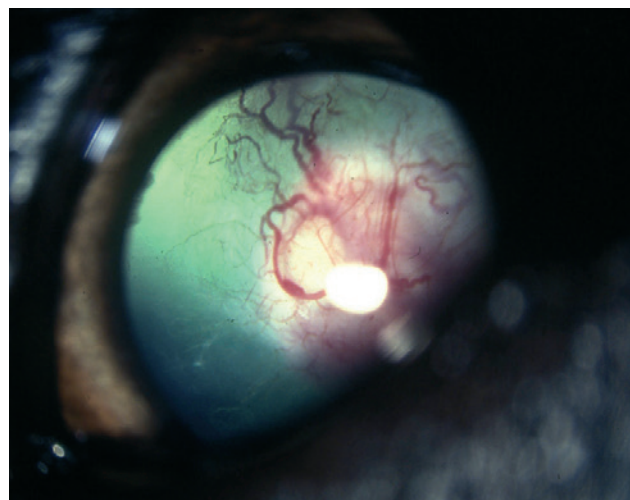
CEA is the commonest inherited ocular disease in the pedigree dog population in the United Kingdom. Accurate assessment of incidence has not been possible, but a forty to sixty per cent current involvement is estimated for the Rough Collie, Smooth Collie and Shetland



*Fig. 7 Multi-ocular defect (MOD). Left eye. English Cocker Spaniel. The globe is much smaller than normal (microphthalmos), nuclear cataract is present and the persistent pupillary membrane is attached to the anterior lens capsule.*



*Fig. 8 Persistent pupillary membrane (PPM) in a 4 year old Basenji, left eye. There is an associated anterior capsular/cortical cataract.*



*Fig. 9 Persistent hyperplastic primary vitreous (PHPV) in a 6 month old Doberman. In this example the blood vessels are patent and there is a posterior capsular/cortical cataract.*



Sheepdog breeds<sup>[9]</sup>. CEA is also seen in the Border Collie, but the incidence is low, between one and two per cent. It has also been recorded in the Lancashire Heeler and as such the author has proposed that the term PSA (Posterior Segment Anomaly) should be used to describe a condition not restricted to the Collie breeds<sup>[10]</sup>. CEA is pleomorphic, involving several structures within the posterior segment and is considered to be inherited as a simple recessive trait. The ophthalmoscopic features used in diagnosis are choroidal hypoplasia (CH) (Fig.10), papillary and peripapillary colobomata (Fig. 11), both congenital neuroretinal non-attachment (Fig.12) and

post-natal neuroretinal detachment and, possibly, the presence of intraocular haemorrhage (Fig. 13).

During organogenesis it is the cells of the posterior wall of the invaginating optic vesicle which form the primordial retinal pigment epithelium. Failure to express growth hormone by these cells affects the subsequent differentiation of all the ocular tissues. In CEA the choroid remains hypoplastic in an area of variable size lateral to the optic disc and non-closure of the foetal fissure leaves a colobomatous defect involving either papillary or peripapillary tissue. The degree of CH and

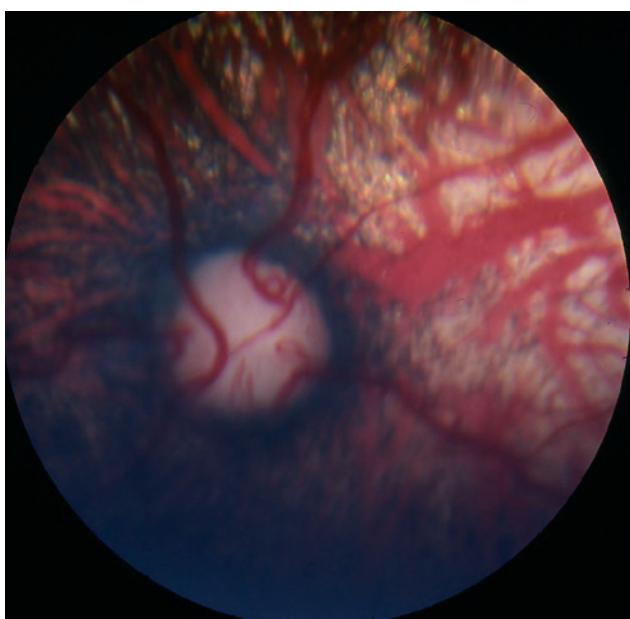


Fig. 10 Collie eye anomaly (CEA). In this left eye of a 2 year old Rough Collie a large patch of choroidal hypoplasia (CH) is seen lateral to the optic disc.

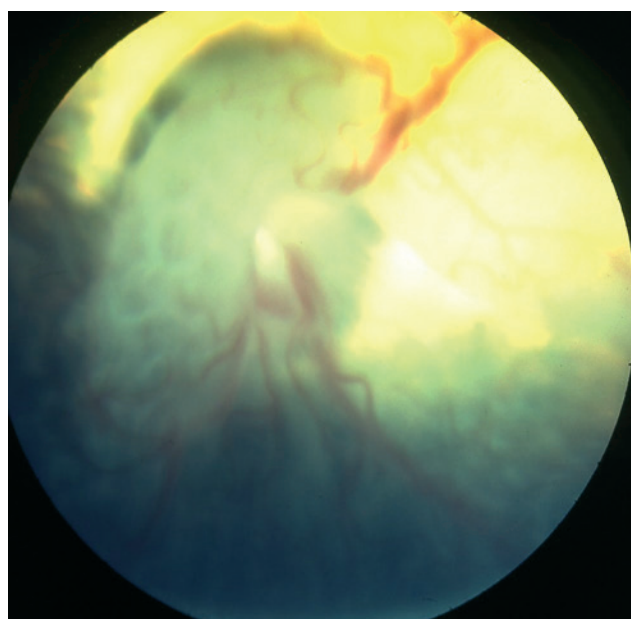


Fig. 12 Collie eye anomaly. Congenital retinal non-attachment : the grey folded retinal tissue overlies the optic disc.

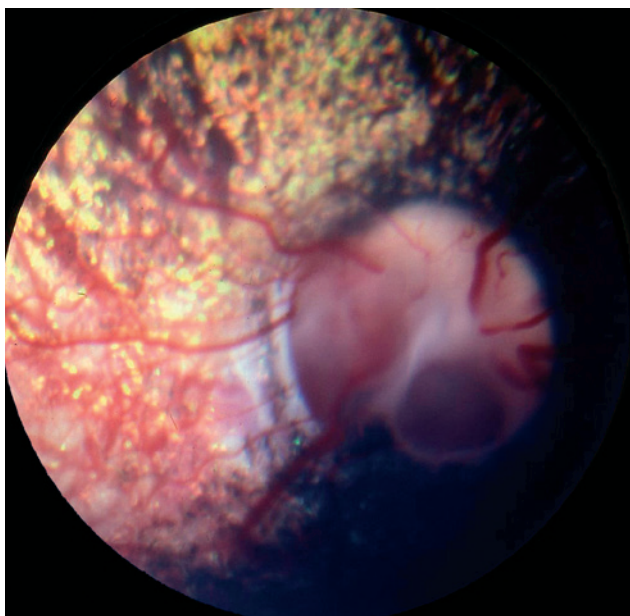


Fig. 11 Collie eye anomaly. In this right eye of a 4 year old Rough Collie a large choroidal hypoplasia lesion and two papillary colobomata are seen.

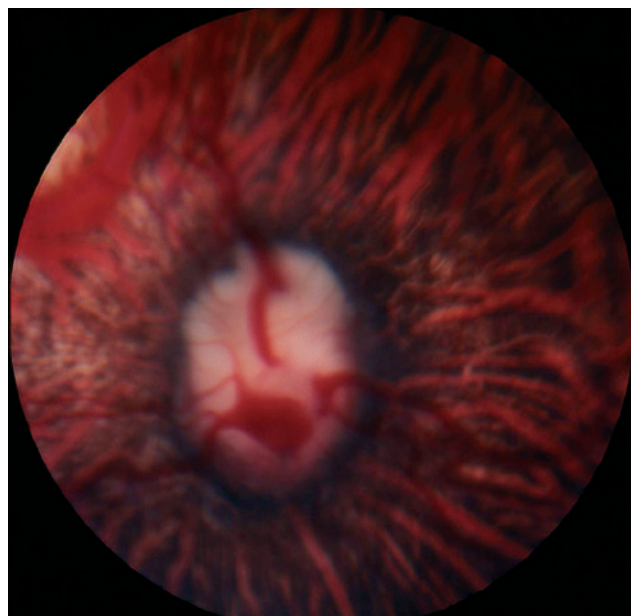
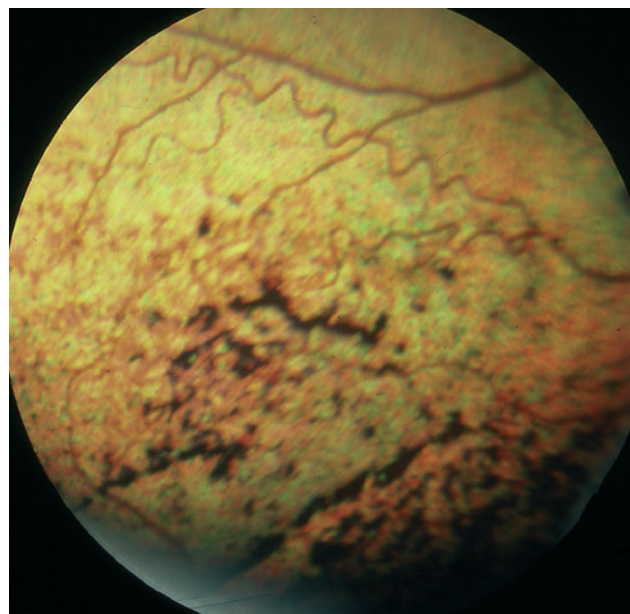
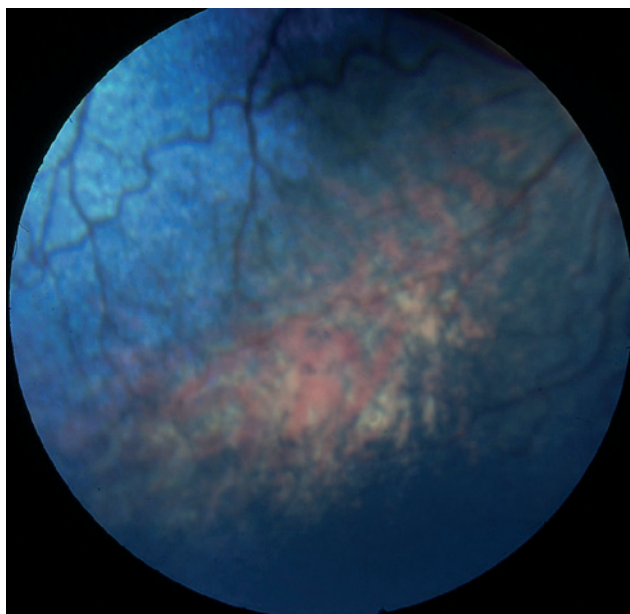


Fig. 13 Collie eye anomaly. A rounded haemorrhage is seen against the white background of the optic disc in this 4 month old Rough Collie pup.



*Figs. 14 and 15 demonstrate the "go normal" phenomenon. In figure 14 the patch of CH is seen as the red and white lesion lateral to the optic disc (right eye) in this 7 week old Rough Collie pup, but in figure 15 the CH lesion has been masked by melanin formation by 20 weeks of age.*

the size of the colobomata vary considerably between affected individuals and even between the eyes of the same individual. All affected puppies demonstrate CH, but by the age of twelve to sixteen weeks many may have the smaller lesions masked by the developing choroidal melanin pigmentation. Somewhat confusingly to the breeder such an affected puppy is described as a "go normal" (Figs. 14 & 15). Estimates vary, but in the U.K. it is likely that some thirty per cent of affected puppies demonstrate this masking procedure. The phenotype thus appears ophthalmoscopically normal but genetically these dogs are affected and should be avoided in disease control programmes. It is a significant aspect of the disease, underlying the necessity for screening all litters at around six to seven weeks of age.

Some thirty per cent of those demonstrating CH as adults also have colobomatous defects. Papillary colobomata involve the optic disc and vary considerably in size, on occasion the whole disc being affected. The peripapillary colobomata are not as common but again they can vary in size. These defects are considered to be due to the failure of scleral tissue to develop in areas associated with the closure of the foetal fissure, but explanation of the atypical coloboma is less easy to ascribe to this process. Peripapillary colobomata are lined with degenerate neuroretinal tissue and those dogs with large

papillary colobomata have defective sight. The role of the coloboma in post-natal neuroretinal detachment is not completely understood but neuroretina may first detach from the edges of the defect.

The CH lesion is inherited as a recessive trait, but there is some evidence to suggest that although the coloboma is considered to be part of the same anomaly this defect may be inherited in its own right. It is simply the high incidence of CH which means that colobomata are most often seen as an accompanying feature. Litter screening for colobomata thus remains necessary for the DNA test for CH is not diagnostic in this situation.

In a small percentage of affected dogs the neuroretina is non-attached at birth whilst in those with significant colobomatous defects the neuroretina may detach within the first three years of life. About one per cent of affected dogs present with intraocular haemorrhage but the aetiology of this complication remains open to speculation. It has been considered that preretinal capillaries at the equatorial parts of the globe may develop as a response to retinal anoxia and that these unsupported vessels may rupture. However haemorrhage can be associated with the presence of unsupported blood vessels within papillary colobomata and the persistence of hyaloid vasculature.



## Developmental inherited disease

### Eyelid abnormalities <sup>[11 &12]</sup>

The terms “entropion” and “ectropion” are familiar to all concerned with dog breeding, both conditions finding origin in the prescribed breed standards which dictate the appearance of the eye. Both are the consequences of euryblepharon (macropalpebral fissure) in which disparity between globe size and the length of the eyelid leads to deformation of the palpebral fissure. In entropion the eyelid margin rolls in against the surface of the eye to cause irritation, inflammation and possible ulceration (Fig.16), whilst in ectropion the lower eyelid hangs away from the globe to expose the membrana nictitans and the lower palpebral conjunctiva (Fig.17). Inheritance patterns remain unknown and radical attention to a revised breed standard offers the only real solution. Corrective surgery is possible in the pursuance of the relief of discomfort and the preservation of sight, but surgical correction is extremely difficult in patients in which gross euryblepharon results in the combined entropion/ectropion defect commonly seen in the St. Bernard, the Clumber Spaniel and the Bloodhound breeds and often referred to as the “diamond eye” (Fig.18).

In distichiasis, adventitious cilia arise from the eyelid margin and make contact with the corneal surface (Fig.19). Without doubt the condition is inherited in the Miniature Long Haired Dachshund, but it is also seen in very many breeds including the American and English Cocker Spaniels, the Bulldog, the Shetland Sheepdog and the Pekingese.

Trichiasis is the condition most commonly seen in the Cocker Spaniel in which the eyelashes are abnormally angled onto the corneal and conjunctival surfaces (Fig.20).



Fig. 16 Bilateral entropion in a 5 month old Golden Retriever.



Fig. 17 Bilateral euryblepharon and ectropion in a 6 month old Labrador Retriever.

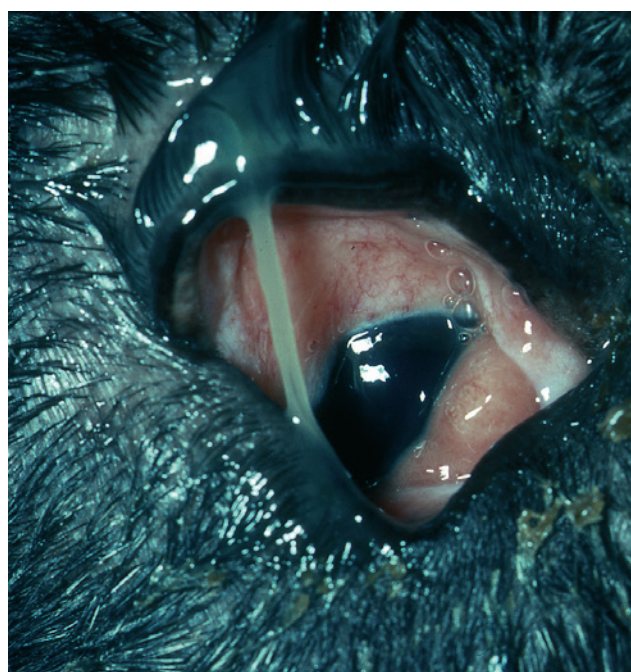


Fig. 18 Euryblepharon, diamond eye formation and nictitans gland prolapse. Right eye, 8 month old St. Bernard.

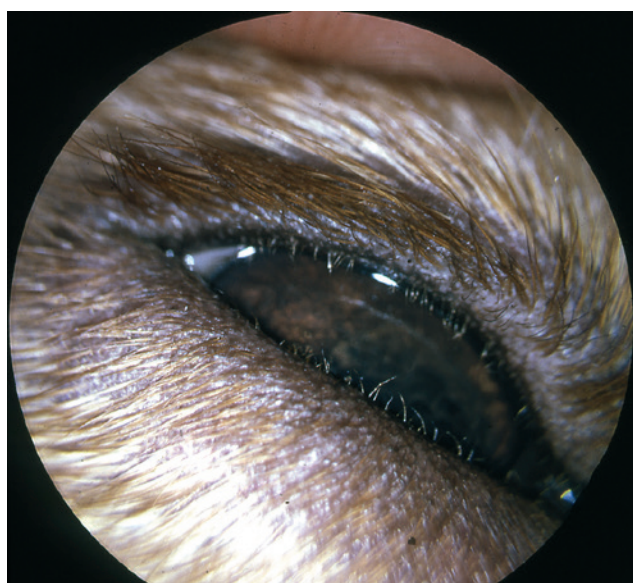

Fig. 19 Distichiasis. Right eye, 9 month old Pekingese.

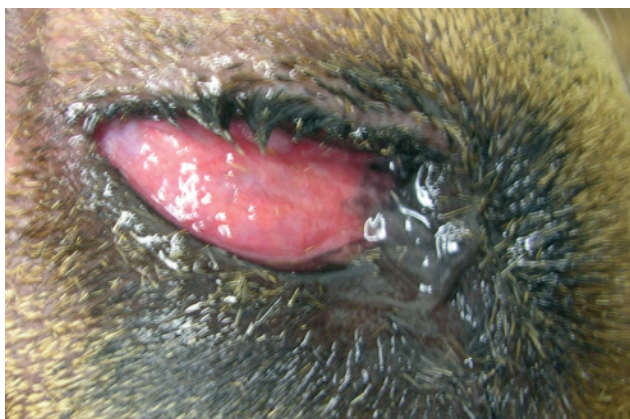

Fig. 20 Trichiasis. Right eye, 3 year old Bloodhound.

## Hereditary Cataract

Opacity of the lens is relatively common in the canine species and several causes ranging from dietary amino acid deficiency in young dogs to senility may be described. Some congenital cataract may be inherited, but inherited developmental cataract may appear at any age after birth and mainly affects young to middle aged subjects <sup>[13,14 & 15]</sup>. It is the pattern of the opacity coupled with the age of the dog which dictate the diagnosis of hereditary cataract (HC). The breeds involved and their incidence figures vary considerably from country to country : currently in the United Kingdom twenty two breeds are affected with HC, with its existence being suspected in another ten breeds for which survey work is currently ongoing.

Table 1 lists the breeds currently involved and the ages beyond which HC is not likely to develop <sup>[16]</sup>.

The lens enlarges throughout life due to the constant production of new fibres which are laid down around the embryonic and foetal nuclear material. These new fibres make up the lens cortex and it is their abnormal formation due to factors as yet undetermined which is responsible for cataract development. Both dominant and recessive inheritance traits are involved in HC and there is considerable variation in the presenting clinical picture and associated prognosis. For example, a 5% incidence (approximately) of posterior polar cataract in the Labrador and Golden Retriever breeds (Fig.21) has to be tempered with the fact that only 5% (approximately) of these dogs go on to develop a generalised cortical cataract which necessitates surgery (Fig.22 & 23).

Table 1 HC in the UK breeds.

Alaskan Malamute	9 years
Australian Shepherd	unknown
Belgian Shepherd Dog (all varieties)	9 years
Boston Terrier – two forms: early Late	3 years 8 years
Cavalier King Charles Spaniel	7 years
German Shepherd Dog	3 years
Giant Schnauzer	9 years
Irish Red and White Setter	9 years
Large Munsterlander	9 years
Leonberger	probably 9 years
Norwegian Buhund	5 years
Old English Sheepdog	3 years
Poodle (Standard)	18 months
Retriever (Chesapeake Bay)	9 years
Retriever (Golden)	9 years
Retriever (Labrador)	9 years
Schnauzer (Giant)	unknown
Schnauzer (Miniature)	3 years
Siberian Husky	6 years
Spaniel (American Cocker)	6 years
Spaniel (Welsh Springer)	3 years
Staffordshire Bull Terrier	18 months

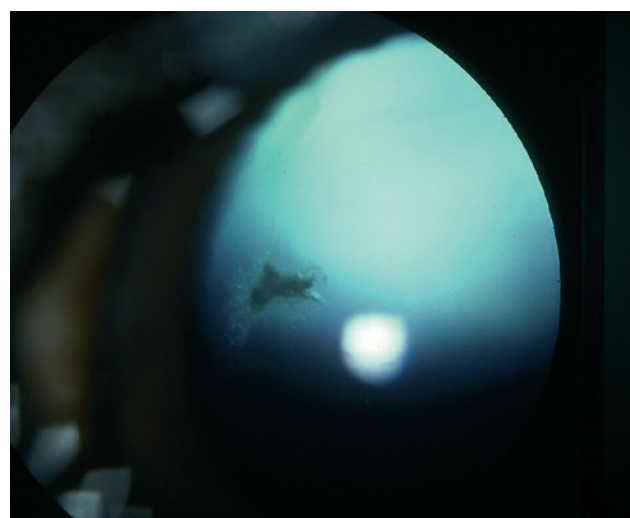
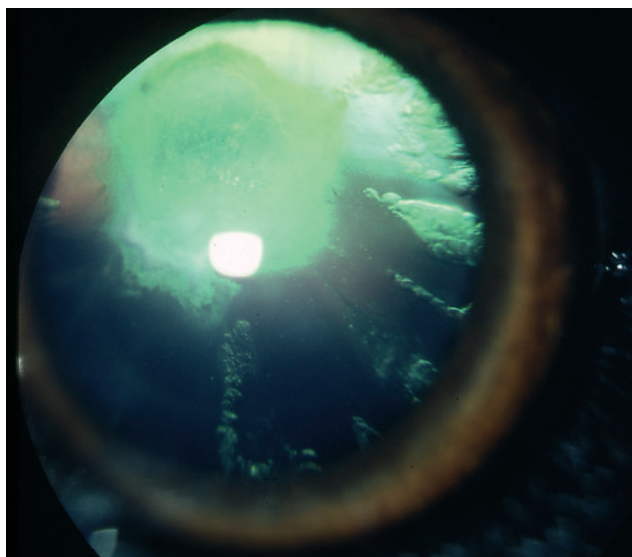
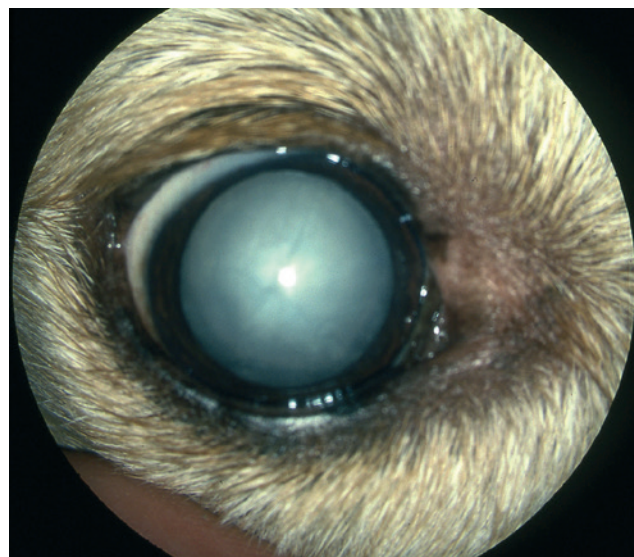


Fig. 21 Hereditary cataract (HC) seen as the dark triangular posterior polar opacity highlighted against the tapetal reflection in the left eye of this 4 year old Golden Retriever

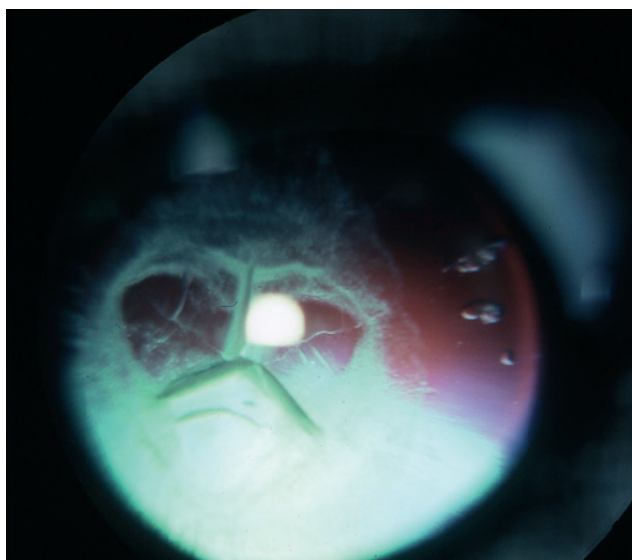




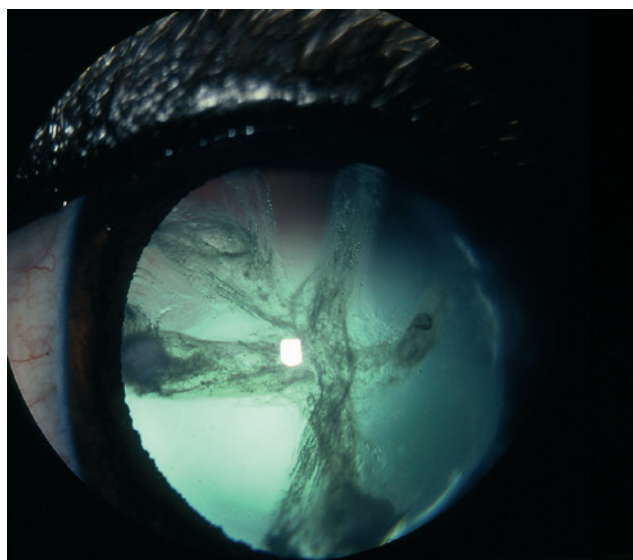
*Fig. 22 Hereditary cataract. Golden Retriever. 2 years. The posterior polar opacity is large and the linear opacities and vacuoles indicate progressive cortical change.*



*Fig. 23 Hereditary cataract. Total cortical cataract in a 6 year old Labrador Retriever. Right eye.*



*Fig. 24 Hereditary cataract. Posterior cortical cataract formation in a 5 year old Siberian Husky.*



*Fig. 25 Hereditary cataract. Late onset cataract in a 5 year old Boston Terrier, right eye.*

Whilst the young Boston Terrier or Miniature Schnauzer with early onset cataract always develops total cortical opacitation bilaterally, the Siberian Husky or the Norwegian Buhund develop cataract which seldom involves anterior cortical material (Fig.24). Of late the situation in the Boston Terrier has been complicated by the re-appearance of a relatively late onset cataract presenting from approximately 4 years of age. In appearance this cataract is very different from its early onset counterpart, linear opacities running from the lens equator centrally resulting in a clinical presentation similar to that of the spokes in a cartwheel (Fig.25). The American Cocker Spaniel may present with bilateral blindness or there may be a unilateral involvement in

which the cataract is restricted to a very small part of the lens: in essence any cataract appearing between 2 months and 6 years of age in this breed must be considered to be inherited.

In general cataract surgery in the presence of normal retinal function is only attempted when an eye is rendered functionally blind by the cataract or there is clear evidence that the developing opacity will involve all or most of the lens cortex. Fortunately surgery can offer the individual a chance of useful vision, but the control of HC ideally needs to be approached as a breed problem and the development of DNA tests is essential. To date only one such test exists and the recent identification

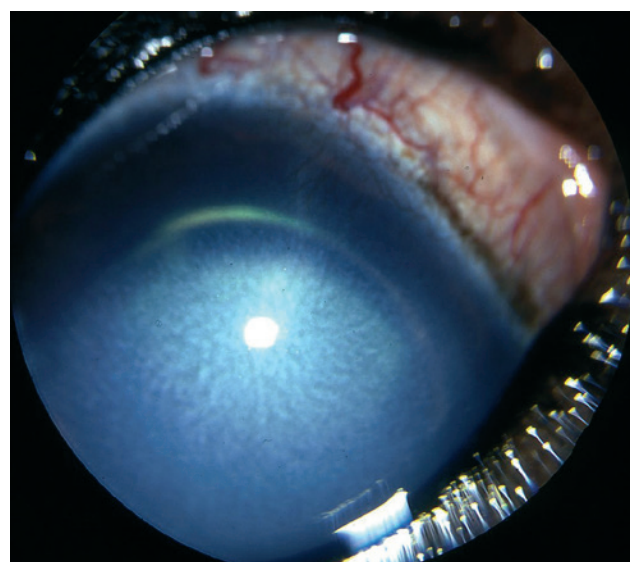
of the HSF4 mutation should lead to the eradication of hereditary cataract from the Australian Shepherd, the French Bulldog, and the Staffordshire Bull Terrier. It is the same mutation which is responsible for the early onset hereditary cataract of the Boston Terrier and the excellent endeavour of breeders to effect disease control in this breed in the UK based on clinical examination will be rewarded by the appearance of this test.

## Lens Luxation

The lens is held in position by an attachment of its posterior capsule to the vitreous (humour) and by its suspensory zonule. The zonular fibres are attached to the equatorial lens capsule and inserted into the epithelium of the ciliary processes. Within many terrier breeds and three non-terrier breeds a recessively inherited weakness of the zonular fibres predisposes to their rupture in early life. The lens then dislocates or luxates usually into the pupil or the anterior chamber to block the pupillary flow of aqueous from the posterior to the anterior chambers. Fluid pressure rises behind the iris and the iridocorneal angle collapses. The result is an acute onset secondary glaucoma<sup>[17 & 18]</sup> (Fig.26) and only the emergency removal of the luxated lens restores the intraocular pressure to normal, prevents optic nerve damage and reduces the chances of ciliary synechiae formation. Primary lens luxation occurs in early middle age in terrier breeds (including the Tibetan Terrier which is patently not a terrier) and it has also been recorded in the Australian Cattle Dog, the Chinese Crested, the Lancashire Heeler (which is a terrier) and the Border Collie. Fortunately the ADAMTS17 mutation responsible for this disease has been recently identified and a DNA test developed.

## Primary Glaucoma

Glaucoma is a pathological process in which there is damage to all the ocular structures as the result of a sustained elevation of the intraocular fluid pressure (IOP) beyond normal physiological limits. Without doubt it is one of the most severe ocular diseases inherited in the pedigree dog. The most significant pathological feature is the early irreversible destruction of the retinal ganglion cells as a result of a pressure induced impairment of axoplasmic flow at the level of the optic disc. The elevation of IOP may be gradual but in the dog the commonest clinical manifestation of primary glaucoma is that of an acute onset, painful, blinding process for



*Fig. 26 Anterior lens luxation and secondary glaucoma in the left eye of a 4 year old Parson Russell Terrier. Corneal oedema and episcleral congestion are present and a small green aphakic crescent can be seen at the 12 o'clock position.*

which there is little or no effective treatment. It presents as a genuine emergency and hours lost in delayed diagnosis or the application of ineffective therapy results in the traditionally poor prognosis for sight.

The lens and cornea are avascular and depend upon the constant production of the aqueous (humour) for their metabolic requirements. Aqueous production is balanced by a constancy in the rate of aqueous drainage from the anterior chamber through the iridocorneal (drainage) angle. All the canine glaucomas are due to defect within this structure, the secondary glaucomas being the result of iridocorneal angle disruption produced by antecedent or accompanying ocular disease whereas the primary glaucomas are due to genetically determined inherent defects<sup>[19,20 & 21]</sup>. There are two types of primary glaucoma in the dog and the terms "open angle" and "angle closure" are descriptive and generally acceptable. In open angle glaucoma (POAG) it is defect(s) at the level of the trabecular meshwork or the aqueous plexus which is (are) responsible for a moderate rise in IOP. The resulting disease process is thus slow to manifest itself with the first indications of its presence being a defect in sight, phacodonesis or globe enlargement. Early diagnosis is practically impossible because pain or discomfort is not part of the presenting clinical picture. POAG in the Beagle has been extensively described in the American literature as the result of long term studies conducted on a small pack of dogs maintained at the University of Florida<sup>[22]</sup>. The defect in aqueous drainage is at the level of the



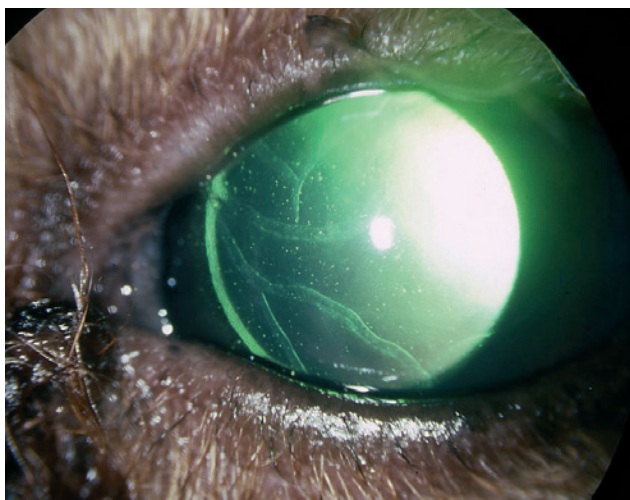


Fig. 27 Primary open angle glaucoma (POAG) in a 5 year old Petit Basset Griffon Vendeen, left eye. Globe enlargement has occurred and lens subluxation and several Haab striae can be seen.

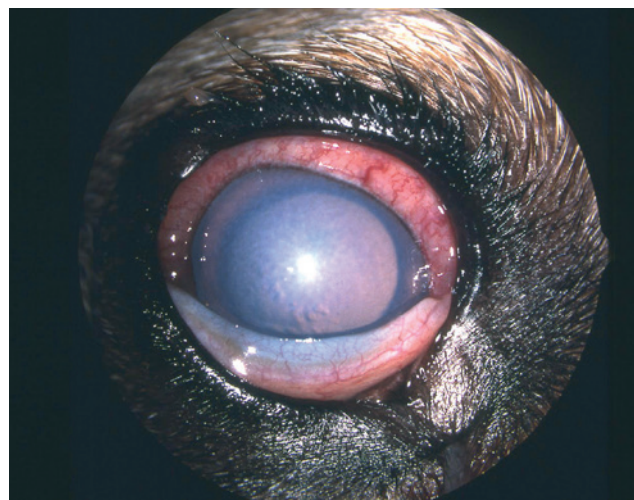

Fig. 28 Primary angle closure glaucoma in a 6 year old Cocker Spaniel, right eye. The episcleral congestion is marked and the mydriasis can be seen through the corneal oedema.

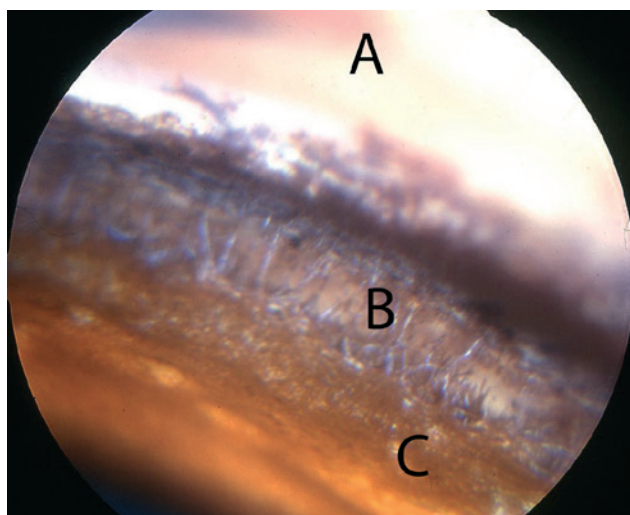


Fig. 29 Gonioscopy. In this normal eye the entrance to the ciliary cleft is open and the fine fibres of the pectinate ligament can be seen crossing the cleft opening. Beagle, 4 years. A = cornea, B = pectinate fibres overlying the ciliary cleft entrance, C = iris.




Fig. 30 Gonioscopy. Pectinate ligament dysplasia (PLD) in a 4 year old Basset Hound. The opening to the ciliary cleft is grossly narrowed and the dysplastic pectinate ligament is seen as sheets of greyish-white material.

trabecular meshwork and a DNA test has been developed for the causal ADAMTS10 mutation. Fortunately POAG is of extremely low incidence in the United Kingdom, involving only the Elkhound, the Petit Basset Griffon Vendeen (PBGV) and possibly the Miniature poodle breeds with any degree of certainty relating to inheritance (Fig.27) and early appropriate medical treatment can slow the process of ganglion cell degeneration. Sadly POAG in the PBGV is not caused by the ADAMTS10 mutation, even though the disease is clinically identical to that seen in the Beagle.

Angle closure glaucoma is relatively commonplace in the UK involving primarily the Basset Hound, the Cocker Spaniel, the Flat Coated Retriever, the Great Dane, the Siberian Husky, the Welsh Springer Spaniel and, more




Fig. 31 Gonioscopy. The narrowed opening to the ciliary cleft has closed in a glaucomatous eye. Cocker Spaniel, 6 years.

recently, the Leonberger breeds (Fig.28). This form of glaucoma is due to the closure of a congenitally defective iridocorneal angle usually in middle-aged dogs and is characterized by sudden onset pain and blindness. The angle develops from mesodermal tissue and incomplete cleavage is indicated by a narrowed entrance to the ciliary cleft and a dysplastic pectinate ligament (Figs.29, 30 & 31). This congenital defect can be identified easily in four to six month old dogs by gonioscopy and this screening procedure is the basis for disease control<sup>[23]</sup>. The genetic mutation/s involved has/have not yet been identified and as such DNA testing is not possible. Medical therapies are ineffective for angle closure glaucoma and current surgical techniques remain inadequate in terms of lifelong IOP control. The developing usage of fibroblast inhibitor drugs may render improvement in the results of anterior chamber drainage surgery, but the overall prognosis for the patient with angle closure glaucoma must remain poor.

### Progressive Retinal Atrophy

In the dog the primary neuroretinal degenerations are collectively described as Progressive Retinal Atrophy (PRA). Historically the PRA's were divided into two groups based on the ophthalmoscopic picture and the terms "generalised" and "central" have been used to differentiate the two groups. Today "generalised PRA", or simply PRA, is used to describe several retinal degenerations of varying aetiology in which the primary focus of disease is the photoreceptor unit<sup>[24 & 25]</sup>. Several genetically distinct causes have been recognised, but many have yet to be defined: however, irrespective of cause, the resultant retinal degeneration is usually characterised by a nyctalopia which progresses to total blindness and may involve secondary cataract formation. It is the age of onset and the speed of progression which vary considerably for the ophthalmoscopic features are very similar. All these diseases with the exception of the x-linked PRA's of the Samoyed and the Siberian Husky and the dominantly inherited PRA of the Bull Mastiff and Mastiff are inherited as simple autosomal recessive traits.

Central PRA (CPRA) is inherited retinal disease in which photoreceptor degeneration is secondary to defect within the retinal pigment epithelium (RPE). The condition is now known as Retinal Pigment Epithelial Dystrophy (RPED)<sup>[26 & 27]</sup> and evidence now exists to suggest that defective tocopherol metabolism is the cause. The inheritance pattern remains undetermined but fortunately the disease

is currently of low incidence. Both PRA and RPED may be present in the same breed.

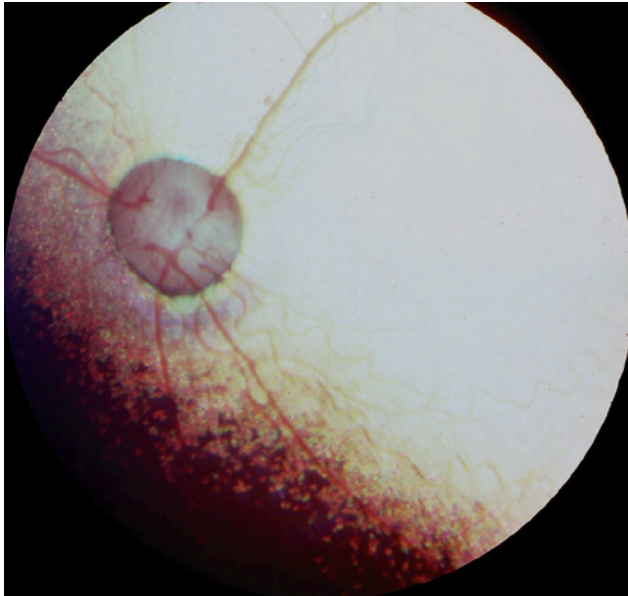
The twenty six breeds in which the specific types of PRA and RPED currently occur in the United Kingdom are seen in Table 2.

Table 2: the PRA breeds in the UK

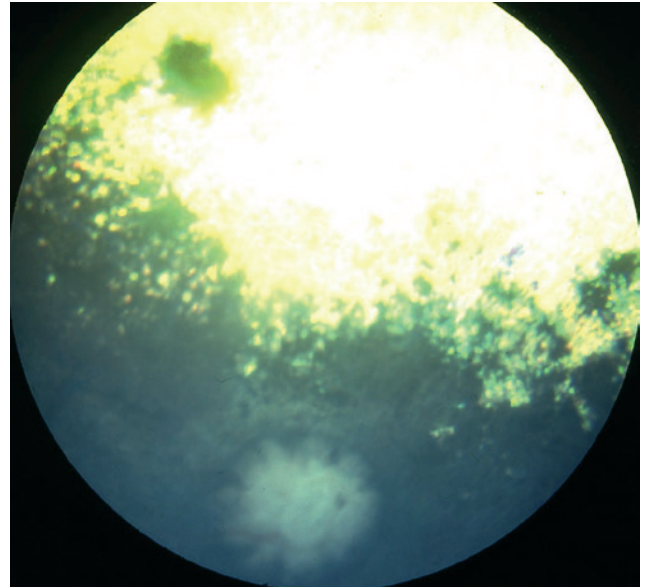
Australian Cattle Dog	PRA (prcd)
Border Collie	RPED
Briard	RPED
Collie (Rough)	RPED and PRA (rcd2)
Collie (Smooth)	RPED
Dachshund (Miniature Long-Haired)	PRA (CORD1)
Elkhound (Norwegian)	PRA (prcd and erd)
Finnish Lapphund	PRA (prcd)
Glen of Imaal Terrier	PRA (crd3)
Irish Setter	PRA (rcd1 and rcd4)
Irish Wolfhound	PRA
Lhasa Apso	PRA
Miniature Schnauzer	PRA -typeA
Poodle (Miniature)	PRA (prcd)
Poodle (Toy)	PRA (prcd)
Retriever (Chesapeake Bay)	PRA (prcd)
Retriever (Golden)	RPED (prcd)
Retriever (Labrador)	RPED and PRA (prcd)
Retriever (Nova Scotia Duck Tolling)	PRA (prcd)
Shetland Sheepdog	RPED
Spaniel (American Cocker)	PRA (prcd)
Spaniel (Cocker)	RPED and PRA (prcd)
Spaniel (English Springer)	RPED and PRA (PRA & CORD1)
Tibetan Spaniel	PRA
Tibetan Terrier	PRA (PRA & rcd4)
Welsh Corgi (Cardigan)	RPED and PRA (rcd3)

### a) Progressive retinal atrophy (GPRA or PRA)

Ophthalmoscopically all the generalised PRA's are characterised by an increased tapetal reflectivity due to the progressive thinning of the neuroretina in degeneration and an attenuation and eventual closure



*Fig. 32 Progressive retinal atrophy (PRA) in a 6 month old Irish setter, left eye. The tapetal reflection is much brighter than normal and the superficial blood vessels are markedly attenuated.*



*Fig. 33 Progressive retinal atrophy in a 7year old Miniature Poodle, right eye. This end stage photograph shows marked tapetal reflection, the "absence" of blood vessels, optic nerve atrophy with visualisation of the lamina cribrosa and the loss of pigmentation in the non-tapetal fundus.*

of the superficial retinal vasculature (Figs.32 & 33). PRA is always bilateral, although there may be slight asymmetry initially between the two eyes. In very early cases a slight tapetal hyporeflectivity may be seen in the peripheral tapetal fundus in some breeds but it is usually the subsequent hyperreflectivity that is recognised at the initial presentation, usually prompted by owner concern about sight. Increased reflectivity is usually first seen in the mid peripheral tapetal fundus and then progresses to involve all the tapetal fundus. Slight beading of the retinal vessels may precede their actual attenuation. Depigmentation of the RPE in the non-tapetal fundus may be followed by a process of patchy repigmentation, the clinical appearance being referred to as "pavementing". The eventual optic nerve degeneration due to ganglion cell death is characterised by crenation and pallor of the optic disc (Fig.33). As the disease progresses day blindness follows the initial nyctalopia and the pupillary light reflexes usually become sluggish. However these reflexes may still be present to a degree even in advanced disease, presumably due to intact ganglion cell activity. Secondary cataract formation can follow in some breeds, the initial changes occurring within the posterior cortical areas of the lens with subsequent opacitation of the whole lens.

Although the exact genetic cause or mutation is known only for a few types of PRA (Table 3), many PRAs can be described in terms of their aetiology and/or structural change. In one type of PRA dysplasia and subsequent degeneration of the rod and cone photoreceptors has

been described in the Irish Setter and the Sloughi (rod cone dysplasia type 1/rcd 1), the Rough Collie (rod cone dysplasia type 2/rcd 2) and the Cardigan Welsh Corgi (rod cone dysplasia type 3/rcd 3) breeds. All three are early onset diseases with severe impairment of vision being present at 6 to 8 months of age and total blindness usually at 12 months. The photoreceptor defect is an enzyme abnormality within the phototransduction cascade. Specifically the retinal level of the nucleotide cyclic guanosine monophosphate (c GMP) is elevated due to reduced c GMP – phosphodiesterase (c GMP-PDE) activity. The defect in the Irish Setter is a mutation of codon 807 of the  $\beta$ -subunit of c GMP-PDE and it has been possible to develop a DNA test to establish the genotype of phenotypically normal dogs in this breed. However, although the disease is identical both clinically and biochemically in the Rough Collie, the rcd 2 mutation is different but it has been mapped to the gene c 1 ORF36 on chromosome 7 and a DNA test is now available. The rod cone dysplasia seen in the Cardigan Welsh Corgi breed is caused by a mutation of the PDE 6A gene for which an accurate DNA-based test exists.

A second distinctive type of PRA in which a rod photoreceptor dysplasia (rod dysplasia/rd) is followed by subsequent cone degeneration was described in the Norwegian Elkhound, but this disease has now been eradicated. The nature of the rod dysplasia was undetermined, but morphological changes were described at 12 weeks with nyctalopia having developed by 6



months of age and total blindness occurring between 3 and 5 years of age. This disease should be differentiated from a recessively inherited early retinal degeneration (erd) more recently described for this breed. In this form of PRA nyctalopia is seen at 6 weeks and the dogs are blind at 12 to 18 months of age. Morphologically changes in the rod inner and outer segments are present by 5 weeks of age with both the rod and cone synaptic terminals developing abnormally. The gene mutation has been identified (STK38L) and a DNA test developed. A fourth type of PRA described as a photoreceptor dysplasia (pd) has been described in the Miniature Schnauzer. It is inherited as an autosomal recessive trait and unusual in that although there is abnormal development of both rods and cones by 24 days of age the classical ophthalmoscopic lesions are not observed until affected dogs are at least 2 years of age. It has been recently postulated that a second and possible third form of PRA may exist in this breed. Another

photoreceptor dysplasia has also been described for the Belgian Shepherd, but in this instance blindness is complete by 8 weeks of age. Retinal folding is seen by 11 weeks of age, these foci subsequently being replaced by areas of degeneration characterised by hyperreflectivity and central pigmentation.

Despite differences in phenotypic appearance and clinical progression, a genetically similar type of later onset PRA, progressive rod-cone degeneration (prcd), has been described for nine breeds of dog. It is a recessively inherited trait, the differences in phenotype either representing different mutations at the prcd locus or that the same mutation is present but its expression is modified by the genetic background. The breeds involved are the American and English Cocker Spaniels, the Australian Cattle Dog, the Chesapeake Bay Retriever, the Labrador Retriever, Miniature and Toy Poodles, the Nova Scotia Duck Tolling Retriever and the Portuguese Water dog.

Table 3: Distribution of various "known" PRA mutations in the pedigree dog.

PRA TYPE	BREED	MUTATION
Rod cone dysplasia (rcd)	Type I Irish Setter, Sloughi Type II Rough Collie Type III Cardigan Welsh Corgi	C GMP-PDE $\beta$ subunit C GMP-PDE $\beta$ subunit C GMP-PDE $6\alpha$
Early retinal degeneration (erd)	Norwegian Elkhound	STK38L
Photoreceptor dysplasia (pd)	Belgian Shepherd Miniature Schnauzer	Unknown Phosducin
Cone degeneration (cd)	Alaskan Malamute	$\beta 3$ – transducin
Progressive rod cone degeneration (prcd)	American & English Cocker Spaniels Australian Cattle Dog Chesapeake Bay Retriever Labrador Retriever Miniature and Toy Poodles Nova Scotia Duck Tolling Retriever Portuguese Water Dog	Unknown but involves chromosome 38
X linked PRA (XLPR)	Siberian Husky Samoyed	RPGR exon ORF 15
Cone-Rod Dystrophy	Miniature Smooth, Long and Wire-haired Dachshund	RPGRIP1
Progressive Retinal Atrophy (PRA)	Akita English Springer Spaniel Papillon Tibetan Spaniel Tibetan Terrier	Unknown Unknown + CORD1 Unknown Unknown Unknown + rcd4
Dominant PRA	Bull Mastiff Mastiff	RHO

In both the Poodle breeds ophthalmoscopic diagnosis is possible between 3 and 5 years of age with blindness occurring between 5 and 7 years. A greyish discolouration of the tapetal fundus is followed by retinal blood vessel attenuation and tapetal hyperreflectivity, this latter initially involving the mid- peripheral and peripheral zones. Secondary cataract formation is commonplace. The photoreceptors develop normally until 14 weeks of age, when disorganisation of their outer segments can be seen. In the English Cocker Spaniel prcd is usually expressed clinically somewhat later in life although a 3-8 years time frame has been reported. The appearance of the fundus can vary with hyperreflective streaks being seen centrally on either side of the optic disc whilst other parts of the retina look normal. These ophthalmoscopic differences are reflected in the histology with both advanced and mild change present in the same retina. This irregularity of change is characteristic in this breed, together with an overall slower rate of progression than in the Poodle breeds. Again secondary cataract formation is usual.

In prcd in the American Cocker Spaniel night blindness is present by 3 to 5 years of age and dogs are normally blind within 24 months of showing this sign. The ophthalmoscopic features present as early as 2.5 years of age, but the irregularity of degeneration seen so commonly in the English Cocker Spaniel is not a particular feature in its American cousin. The ophthalmoscopic changes are similar to those seen in the Poodle breeds. In the Labrador Retriever nyctalopia is not present until 4 to 6 years of age and severe visual impairment may not be noticeable until 7 or 8 years. A change in tapetal reflectivity is seen in the mid-peripheral and peripheral fundus, often accompanied by the appearance of a brownish streak on both sides of the optic disc. Tapetal hyperreflectivity and blood vessel attenuation ensue, but changes in the central fundus may not be too noticeable. In the Portuguese Water Dog the clinical picture is similar to that of the affected Labrador Retriever, with early ophthalmoscopic diagnosis being possible at 3 to 6 years of age.

The x-linked, autosomal recessive hereditary retinal degeneration (XLPR) which occurs in the Siberian Husky and Samoyed breeds is manifest at 2 to 4 years of age and the disease is similar clinically to the prcd seen in the Poodle breeds. The RPGR gene mutation has been described and a DNA test developed.

Early onset Cone-Rod Dystrophies (CORD/crd) have been described in the American Pit Bull Terrier, the Smooth-Haired Dachshund, the Wire-Haired Dachshund and the Miniature Long-Haired Dachshund with the cone-specific ERG responses being significantly reduced in amplitude at 5 to 6 weeks of age whilst the rod responses are normal. A mutation in the retinitis pigmentosa GTPase regulator-interacting protein 1 (RPGRIP1) gene has been identified in the Dachshund breeds and a test developed. CORD1 has also been identified in the English Springer Spaniel as a second PRA type in this breed. A late onset cone-rod dystrophy (crd3) has been ascribed to deletions of exons 15 and 16 in the ADAM9 gene in the Glen of Imaal Terrier and a DNA test is now available [28].

The remaining PRA's bar one are all simply referred to as Progressive Retinal Atrophy (PRA). Histological and electrophysiological studies have been completed in the Akita, the English Springer Spaniel, the Papillon, the Tibetan Spaniel and Tibetan Terrier. Age of onset varies between these breeds. Night blindness and ophthalmoscopic change is not usually seen until middle age in the Papillon. In this breed the disease is clinically similar to the prcd of the Poodle breeds, but secondary cataract does not occur. In the Tibetan Spaniel minor ophthalmoscopic change and nyctalopia occur between 3 and 5 years of age. In the Tibetan Terrier, however, night blindness is noted from 9 to 10 months of age with blindness being complete often before 3 years of age: clinicians should be aware that three types of PRA are present in this breed with the recently reported PRA3 causing disease between 4 to 7 years of age and a late onset PRA occurring much later in life. Further confusion is possible because retinal degeneration is also seen in the neuronal ceroid lipofuscinosis that is inherited in this breed. PRA in the Akita is heralded by nyctalopia between 1 and 3 years of age, but two patterns of initial ophthalmoscopic change have been described. The early changes may be seen as either a central hyperreflective band extending from the area centralis to the periphery or hyperreflectivity in the peripheral part of the tapetal fundus. The usual pattern of generalised tapetal hyperreflectivity and blood vessel attenuation follows with complete blindness occurring between 3 and 5 years of age. There is some uncertainty about the aetiology of the disease in the English Springer Spaniel in that there is considerable variation in the age at which the clinical signs may appear and the early signs are different

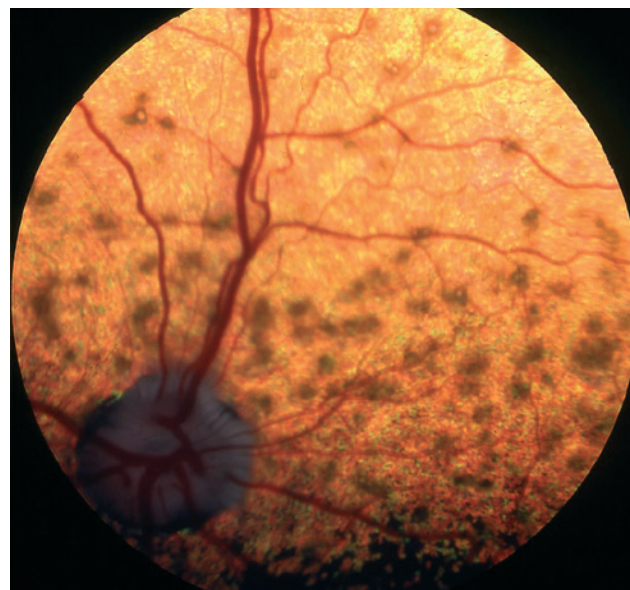
from what would be expected. Initially a slight colour change in the retina is seen peripherally at the tapetal-nontapetal junction followed by the development of a horizontal band of degeneration slowly progressing centrally. A generalized increase in tapetal reflectivity and blood vessel attenuation is eventually seen. Secondary cataract formation is common. The mutation has not been identified and a DNA test not developed: confusingly the CORDI mutation recently found in this breed does not cause this disease.

As the awareness of hereditary retinal degeneration in pedigree dogs has increased and as DNA research has evolved a late onset PRA (LOPRA) has now been identified in several breeds. A DNA test is available although details of the specific mutation involved have not yet been published. To date LOPRA has been found in the Gordon, Irish and English Setters and the Tibetan Terrier, but the expectation is that it will appear in other breeds in the future. It is a rod-cone degeneration and, perhaps rather confusingly, has been labelled rcd 4. It is usually seen in dogs of 8 to 10 years of age and as other rod-cone degenerations it is characterized initially by night blindness. Thus there are two established types of inherited retinal blindness in the Irish Setter, both early and late onset disease and possibly a third rod-cone degeneration in this breed which expresses between rcd1 and rcd4 in middle age.

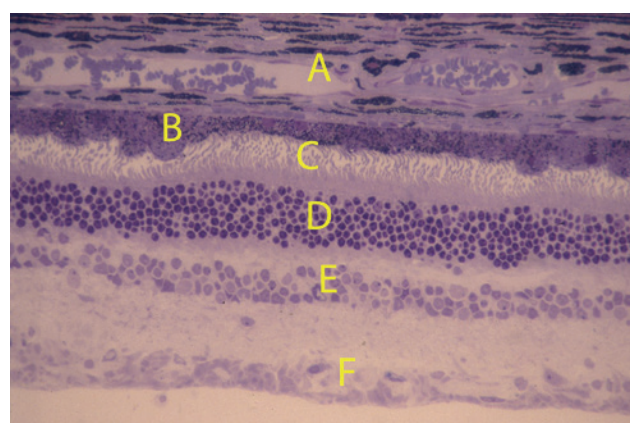
The one notable exception in the PRA story is the recessively inherited cone degeneration (CD) described in the Alaskan Malamute responsible for a congenital hemeralopia or day blindness. The disease is apparent by 8 to 10 weeks of age, but ophthalmoscopic changes are never seen, pupillary reflexes are normal and nyctalopia never occurs. The cones are normal at birth but in some morphological changes are seen by 7 weeks of age. All cones are affected by 6 months with the end stage being a pure rod retina at 4 years of age. A selective absence of  $\beta$ 3-transducin expression due to the deletion of the entire CNGB3 gene is considered to be the cause of this type of PRA.

### **b) Retinal Pigment Epithelial Dystrophy (RPED)**

Originally considered to be a primary photoreceptor degeneration, this disease is due to defective RPE activity. One of the many important functions of RPE cells is the degradation of utilised photoreceptor outer segments (POS). The visual pigments are located within the POS and there is a rapid turnover of this material



*Fig. 34 Retinal pigment epithelial dystrophy (RPED) in a 5year old Briard, left eye. Several spots of lipopigmentation are seen in the tapetal fundus.*



*Fig. 35 Histological section of retina from the tapetal fundus showing the accumulation of lipofuscin in a grossly distorted pigment epithelial cells. Briard, 7 years. A = choroid, B = diseased RPE, C = visual cell layer (photoreceptors), D = outer nuclear layer, E = inner nuclear layer, F = ganglion cell layer.*

during phototransduction. Rod outer segment renewal takes approximately ten days, the basic materials for production being provided by the RPE cells as a result of their breakdown of utilised POS. Defective RPE cells can neither degrade POS material quickly enough nor effectively participate in POS production. Their cytoplasm accumulates large quantities of the phagocytosed POS material and RPE function in terms of neuroretinal support ceases. Both the rod and cone photoreceptors degenerate and sight is affected. RPED has been recorded in the Border Collie, the Rough and Smooth Collie breeds, the Shetland Sheepdog, the English Cocker Spaniel, the English Springer Spaniel, the Briard and the Polish Lowland Sheepdog. The mechanism of inheritance remains



unknown but fortunately the incidence of this disease worldwide is rapidly diminishing.

The characteristic ophthalmoscopic feature of RPED is the appearance of a light brown pigment within the tapetal fundus, first as spots (Fig 34) but later as coalescing patches. An increased tapetal reflectivity is easily detected in the areas of degeneration between the patches, but blood vessel attenuation is less marked than in PRA and unlike PRA there is no secondary cataract formation. The pigmentation seen ophthalmoscopically is due to the accumulation of a lipopigment within cells of the RPE (Fig.35). However melanin protects against this disease process and the neuroretina overlying the pigmented RPE cells of the non-tapetal fundus will continue to function normally long into the disease process. Affected dogs therefore lose their central field of vision but maintain peripheral sight. There is undoubtedly genetic predisposition to this disease as witnessed by the specific breed involvement but many factors influence the course of degeneration. Recent studies have shown that affected dogs have low serum tocopherol levels despite dietary adequacy and the disease may simply be the ocular manifestation of inherited anomaly within tocopherol metabolism at the level of the liver. The reducing incidence of this disease may simply reflect an improvement in nutrition, with specific attention being paid to the vitamin levels in commercial foods.

### **Congenital Stationary Night Blindness**

This disease has only been recorded in the Briard and in addition to being named Congenital Stationary Night Blindness (CSNB), it is variously described in the literature as Hereditary Retinal Dystrophy, Lipid Retinopathy, Canine Leber's Congenital Amaurosis (CLCA) and RPE65 Null Mutation. At birth affected dogs have a non-recordable rod ERG or a markedly reduced b wave response and congenital night blindness is present. Daylight vision can vary considerably from near normal to severe impairment and the degree of visual impairment does not noticeably change throughout the dog's life. The ophthalmoscopic features are those of a subtle alteration in tapetal reflectivity and possible greyish spotting in the non-tapetal fundus, but such features are not seen until two to three years of age.. Histologically these spots are large lipid inclusion bodies in the RPE and they are believed to develop as the result of impaired retinal polyunsaturated fatty acid metabolism. The disease is due to a four base-pair deletion of the RPE65

gene, a DNA test has been developed and gene therapy is now possible for affected dogs <sup>[29]</sup>. CSNB is similar to the human disease, Leber's congenital amaurosis, and as such the studies completed in the Briard potentially have huge comparative value.

### **Canine Multifocal Retinopathy**

Canine Multifocal Retinopathy (CMR) is a strangely unique disease which has been recorded relatively recently in several breeds of dog including the Australian Shepherd, the Bullmastiff, the Cane Corso, the Coton du Tulear, the Dogue de Bordeaux, the Great Pyrenees, the Lapponian Herder, the Mastiff and the Perro de Presa Canarios. It is a recessively inherited trait which usually develops before 4 months of age and has the propensity to either slowly progress or disappear leaving retinal folds, somewhat depending on the breed. The disease is characterised by multifocal, greyish, circular bullous retinal detachments which may be confused with chorioretinitis lesions or retinal dysplasia. The detachments are associated with hypertrophied retinal pigment epithelium and discrete areas of tapetal hyperreflectivity are probably related to degeneration of the outer nuclear and plexiform layers. CMR is due to a BEST1 mutation and a DNA test has been developed <sup>[30]</sup>.

### **Neuronal Ceroid Lipofuscinosis**

This disease has been recorded in several breeds of dog as a recessively inherited trait in which lipopigments resembling ceroid and fuscine accumulate in brain and retinal tissue to cause neuronal necrosis. In man it is known as Batten's disease and blindness, dementia and seizures are followed by death. In the dog presentation varies between the breeds with ataxia and cortical blindness occurring in the English Setter with normal retinal activity, but retinal blindness due to retinal pigment epithelial cell and ganglion cell degeneration precedes the central signs in the Polish Nizinny and the Tibetan Terrier. In the Miniature Schnauzer the retinal changes and the central neurological signs develop together in dogs aged 3 to 4 years. These variations in clinical signs coupled with differing retinal electrophysiological and histological findings have led to a number of genetic mutations being identified. Increased aggression is a characteristic of the disease in the Nizinny and the Tibetan Terrier and in this latter breed it is the identification of a one base pair deletion

in exon 16 of the ATP13A2 gene that has led to the development of a DNA test for this dreadful disease <sup>[31]</sup>.

## The DNA tests for inherited ocular disease in dogs.

A considerable amount of inherited ocular disease control has been achieved based on simple clinical examination. In the UK rcd1 has hopefully been eliminated from the Irish Setter and the problem of RPED in the Briard has virtually disappeared. Regular routine eye examination particularly of breeding stock has achieved much with congenital and early onset disease, but the relatively recent development of DNA technology coupled with definition of the canine genome has meant rapid progress in the identification of disease mutations and the resultant and ongoing appearance of DNA based tests. As DNA contains the genetic information relating to inheritance it can be extracted from blood samples and even buccal swabs to locate and identify the mutations in affected and carrier dogs. Once a mutation has been identified then a test which is specific for that mutation can be developed <sup>[32]</sup>.

DNA testing allows the identification of the genetically normal dogs which can be safely used in breeding programmes. As many inherited diseases may develop in middle age or even later in life the identification of affected dogs before they develop clinical signs of disease is particularly valuable and, of course, DNA testing identifies the clinically normal carriers for a recessively inherited disease. Ideally only genetically normal stock should be used to effect disease control and its eventual eradication, but initially carrier stock and even affected stock can be used in matings with genetically normal dogs particularly where the gene pool is small.

DNA tests are currently available for the following ocular diseases:

- Hereditary cataract (HC) in the Australian Shepherd, the Boston Terrier (early onset), the French Bulldog and the Staffordshire Bull Terrier (early onset). (HFS4 mutation)
- Generalised Progressive Retinal Atrophy (GPRA) in the Australian Cattle Dog, the Cardigan Welsh Corgi, the Cocker Spaniel (both the English and American breeds), the Dachshunds (Miniature Long-Haired and Miniature Smooth-Haired), the English Springer Spaniel, the Finnish Lapphund, the Glen of Imaal Terrier, the Gordon Setter, the Irish Setter,

the Miniature Schnauzer, the Norwegian Elkhound, the Poodles (Miniature and Toy), the Retrievers (Chesapeake Bay, Golden, Labrador and Nova Scotia Duck Tolling breeds), the Rough Collie and the Yorkshire Terrier. ( see the PRA text for the known mutations in these breeds)

- Collie Eye Anomaly (CEA) in the Border Collie, Rough and Smooth Collies, the Shetland Sheepdog and the Lancashire Heeler. (NEHJ1 mutation)
- Primary Lens Luxation (PLL) in the Lancashire Heeler, the Miniature Bull Terrier, the Parson Russell Terrier, the Sealyham Terrier and the Tibetan Terrier. (ADAMTS17 mutation)
- Canine Multifocal Retinopathy (CMR) in the Australian Shepherd, the Bullmastiff, the Cane Corso, the Coton du Tulear, the Dogue de Bordeaux (French Mastiff), the Great Pyrenees, the Mastiff, the Laponian Herder and the Perro de Presa Canarios. (BEST1 mutation).

## Conclusion

The simple truth that inherited disease exists should spur our efforts to ensure that future pedigree dog populations are protected from a continuing threat and the contrary viewpoint based on the observation that most affected dogs may lead "normal" lives is misleading. The presence of an inherited disease within a breed should never be accepted in a negative way, but rather it should stimulate the whole breed to recognise the potential threat in a collective way and cooperate in disease control measures. Progress with the correction of the conformational defects is obvious and sound breed standards based on freedom from pain or discomfort can be written today. Compliance is more difficult, but through breeder instruction and understanding, critical judging, veterinary checks at dog shows and possible restrictions on official registration we should be able to effect the desired change. For those inherited diseases which are not due to faulty conformation the use of DNA testing combined with the continuing use of routine eye examination represents the most effective way of instituting disease control. It should be understood that there is real potential for any breed that is currently disease-free to develop hereditary eye disease and awareness of an emerging disease requires data based primarily on routine eye examination. Voluntary participation in these activities will benefit from positive encouragement by fellow breeders, the breed society and the respective kennel club. Legislation through kennel clubs and breed

societies should always possible, but some may regard this as punitive. However DNA tests allow the accurate assessment of genotype and the continuing use of routine ophthalmoscopic examinations will warn of emerging new disease situations. The responsibility for disease control must be adequately addressed and mistakes recognised, not hidden. It is true that dogs can cope with both disability and discomfort, but should they when alternatives exist? A blind dog often learns to live with its disease, but no dog should be condemned to a world of blindness and/or pain or discomfort at the time of its conception by action which places health and soundness second to other considerations.

## References

- [1] Crispin SM, Long SE & Wheeler CA. Incidence and ocular manifestations of multifocal retinal dysplasia in the Golden Retriever. *Vet Rec.* 1999, 145, 669-672.
- [2] Holle DM, Sarna CS & Aguirre GD. The geographical form of retinal dysplasia is not always a congenital abnormality. *Vet Ophthalmol.* 1999, 2, 61-66.
- [3] Barnett KC, Bjork GR & Kock E. Hereditary retinal dysplasia in the Labrador Retriever in England and Sweden. *J Sm Anim Pract.* 1970, 10, 755-759.
- [4] Toole DO, Young S, Severin GA & Neumann S. Retinal Dysplasia in English Springer Spaniel Dogs. *Vet Pathol.* 1983, 20, 298-311.
- [5] Barnett KC. Hereditary cataract in the Miniature Schnauzer. *J Sm Anim Pract.* 1985, 26, 635-644.
- [6] Gelatt KN, Samuelson DA, Bauer JE et al. Inheritance of congenital cataracts and microphthalmia in the Miniature Schnauzer. *Am J Vet Res.* 1983, 44, 1130-1132.
- [7] Barnett KC & Knight GC. Persistent pupillary membrane and associated defects in the Basenji. *Vet Rec.* 1969, 85, 242-248.
- [8] Stades FC. Persistent hyperplastic tunica vasculosa lentis and persistent primary vitreous in Doberman Pinchers: Genetic aspects. *J Am Anim Hosp Assoc.* 1983, 19, 957-964.
- [9] Bedford PGC. Collie eye anomaly in the United Kingdom. *Vet Rec.* 1982, 111, 253-270.
- [10] Bedford PGC. Collie eye anomaly in the Lancashire Heeler. *Vet Rec.* 1998, 143, 354-356.
- [11] Bedford PGC. Diseases and surgery of the canine eyelids. *Veterinary Ophthalmology*, ed. Gelatt KN. 3rd. edition. 1999. 535-568.
- [12] Stades FC & Gelatt KN. Diseases and surgery of the canine eyelid. *Veterinary Ophthalmology*, ed. KN Gelatt. 4th. edition. 2007, 563-618.
- [13] Barnett KC. The diagnosis and differential diagnosis of cataract in the dog. *J Sm Anim Pract* 1985, 26, 305-316.
- [14] Curtis R & Barnett KC. A survey of cataracts in the Golden and Labrador Retrievers. *J Sm Anim Pract.* 1989, 30, 277-286.
- [15] Ocular disorders presumed to be inherited in purebred dogs. 1999. ACVO. Purdue University.
- [16] British Veterinary Association/Kennel Club/International Sheepdog Society Eye Scheme. Information for panellists: Part 3: Technical Information. 2012.
- [17] Gwin R, Samuelson D, Powell N et al. Primary lens luxation in the dog associated with lenticular zonule degeneration and its relationship to glaucoma. *J Am Anim Hosp Assoc.* 1982, 18, 485-491.
- [18] Curtis R. Lens luxation in the dog and cat. *Vet Clin N Am Sm Anim Pract.* 1990, 20, 755-773.
- [19] Martin CL & Wyman M. Primary glaucoma in the dog. *Vet Clin N Am.* 1978, 8, 257-286.
- [20] Bedford PGC. The clinical and pathological features of canine glaucoma. *Vet Rec.* 1980, 107, 53-58.
- [21] Miller PE. Angle-closure glaucoma. *Proc Nordic Vet Ophthalmol Meet.* 2005, 1-14
- [22] Gelatt KN, Gum GG, Gwinn RM et al. Primary open angle glaucoma: Inherited primary open angle glaucoma in the Beagle. *Am J Pathol.* 1981, 102, 292-295
- [23] Bedford PGC. Gonioscopy in the dog. *J Sm Anim Pract.* 1977, 18, 615-629.
- [24] Millichamp NJ. Retinal degeneration in the dog and cat. In: *Retinal degeneration in the dog and cat.* *Vet Clin N Am Sm Anim Pract.* 1990, 20, 799-835.
- [25] Narfstrom K & Petersen-Jones S. Diseases of the canine ocular fundus. *Veterinary Ophthalmology*, ed. KN Gelatt. 4th. edition. 2007, 944-1025.
- [26] Aguirre G & Laties A. Pigment epithelial dystrophy in the dog. *Exp Eye Res.* 1976, 23, 247-256.
- [27] Lightfoot RM, Cabral L, Gooch L et al. Retinal pigment epithelial dystrophy in Briard dogs. *Res Vet Sci.* 1996, 60, 17-23.
- [28] Kropatsch R, Petrasch-Parwez E, Seelow et al. Generalized progressive retinal atrophy in the Irish Glen of Imaal Terrier is associated with a deletion in the ADAM9 gene. 2010. *Mol Cell Probes.* 24(6), 357-363.
- [29] Acland GM, Aguirre GD, Bennett J et al. Long term restoration of rod and cone vision by a single dose rAAV-mediated gene transfer to the retina in a canine model of childhood blindness. *Mol Ther.* 2005, 12, 1072-82.
- [30] Grahn BH, Philiberty H, Cullen CL et al. Multifocal retinopathy in the Great Pyrenees. *Vet Ophthalmol.* 1999, 1, 211-221.
- [31] Wohlke A, Ute P, Bock et al. A one base pair deletion in the canine ATP13A2 gene causes exon skipping and late onset neuronal lipofuscinosis in the Tibetan Terrier. *PLoS Genetics.* 2011, 7 (10) e1002304.
- [32] Mellersh C. DNA testing and domestic dogs. *Mamm Genome.* 2012, 23(1-2), 109-123.



## COMMISSIONED PAPER\* (PL)

# Hereditary oral disorders in pedigree dogs Proposals for their evidence and assessment

*J. Gawor<sup>1</sup>*

## SUMMARY

Oral problems which have an hereditary or familial basis as well as those showing breed predispositions were selected for consideration in this paper which follows from a project of the Polish Small Animal Veterinary Association (PSAVA). This project was initiated in response to the growing concern of the veterinary community to the increasing number of hereditary defects within the pedigree animal population. It was felt that a platform facilitating cooperation with the 'kennel clubs' would be very beneficial. The diagnostic criteria for each disease is detailed and a proposed ranking of the negative effect on the quality of life of affected animals is proposed. Forty nine breeds that may have genetic oral disorders are listed and suggestions on how to evaluate and certify affected individuals are described.

Key words: hereditary, oral disease, breed predisposition

This paper was commissioned by FECAVA for the special issue of EJCAP, Genetic/Hereditary Disease and Breeding.

## Introduction

More than 500 genetic defects currently exist in purebred dogs. Inherited diseases such as hip dysplasia, brachycephalic airway syndrome, cardiomyopathies, endocrine dysfunctions, blood disorders, oral problems and many more, affect the quality of life and lifespan of these dogs<sup>[1]</sup>. This paper concentrates on the numerous oral problems affecting dogs which have hereditary or familial characteristics or breed predispositions. The basis of inheritance is sometimes associated with a

single pair of genes, whilst in others a more complicated mechanism of inheritance is involved. In yet others it is based on observations only leading us to propose there is a familial basis with the mechanism of inheritance not being exactly understood<sup>[2]</sup>.

The Feline Advisory Bureau (FAB) proposed a very useful system of dividing hereditary problems in cats (confirmed and suspected) into three groups:

- the genetics of the condition has been confirmed and/or a genetic test is available.
- a breed predisposition is recognised and the condition is strongly suspected to be inherited.
- a potential breed predisposition is recognised but it is not currently known if the condition is inherited or not, (often here only single case reports are available or evidence is anecdotal<sup>[3]</sup>.)

1 Klinika Weterynaryjna arka, ul. Chłopska 2a, 30-806 Kraków, Poland  
E-mail: jgawor@pp.com.pl

\*The finding and conclusions presented here are based on the report of a Polish Small Animal Veterinary Association project which was published in 2009 (Magazyn Weterynaryjny vol. 18 nr 145'20) by the Dental Working Group of PSAVA. Veterinarians, skilled in the subject, were selected and asked to perform examinations, recording and certifying pedigree dogs which showed no signs or symptoms of oral hereditary problems.

The standards of assesment in oral disease should be the same as those pertaining in canine hereditary disorders in other disciplines such as orthopaedics, dermatology, ophthalmology etc. The localisation of the exact genes responsible for specific conditions is often easier in the dog as a map of canine genes has been already made<sup>[4]</sup>.

Diagnostic methods are shown in Table 1. The degree of the negative influence on the quality of life of animals affected with genetic defects is ranked in Table 2. Forty nine breeds that may have genetic oral disorders are listed and suggestions as to how to evaluate and record the diseases are listed in Table 3.

Table 1 Web based sources of genetic disease information on dogs

Examination and/or recording method		Requirements
Photography Ph		Required photographic documentation of the disease with characteristic signalments
Laboratory	Genetic G	Test must be performed by referral laboratories
	Histopathological H	Test must be performed in referral laboratories
	Other laboratories L	Test must be performed in referral laboratories
Clinical C		Clinical examination according to AVD EVDC AVDC standards
		a. Awaken animal examination
		b. Anesthetised animal examination
Radiography X		Projection and positioning appropriate to problem

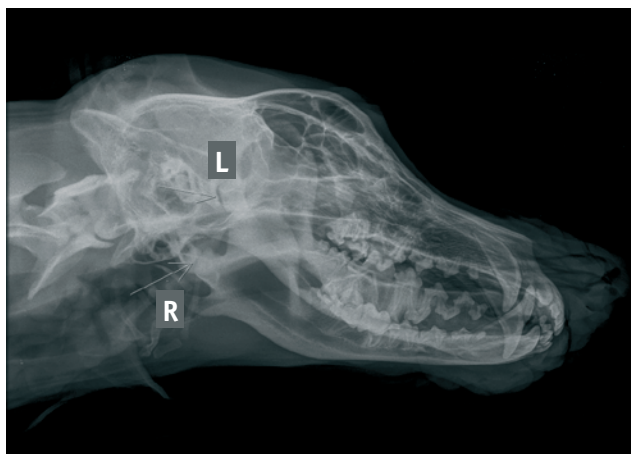


Fig. 1 American cocker spaniel with TMJ dysplasia

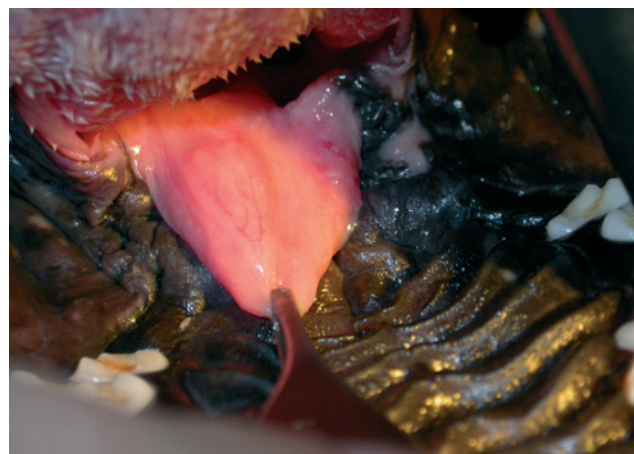

Fig. 3 English bulldog showing an elongated soft palate (a part of obturative syndrome)

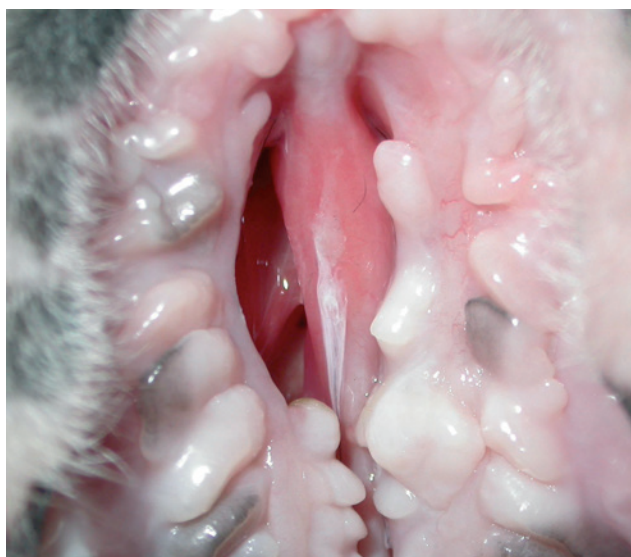

Fig.2 Boxer with a cleft palate

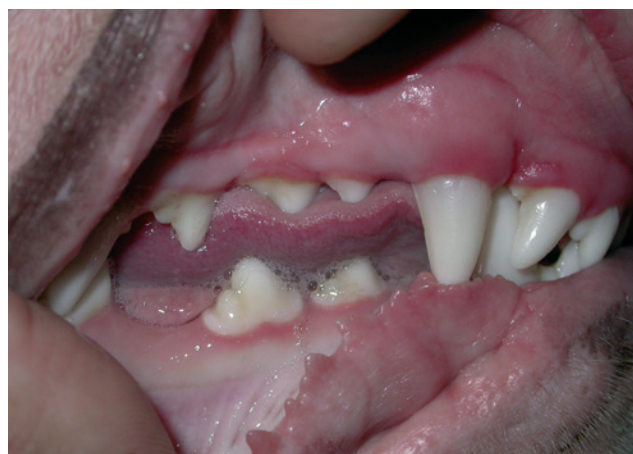
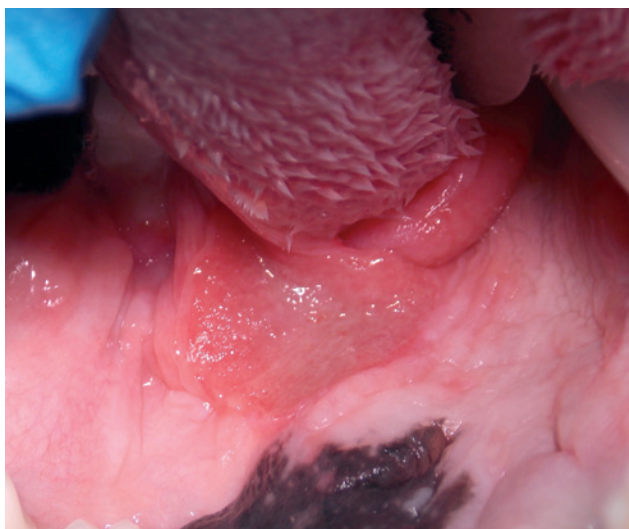
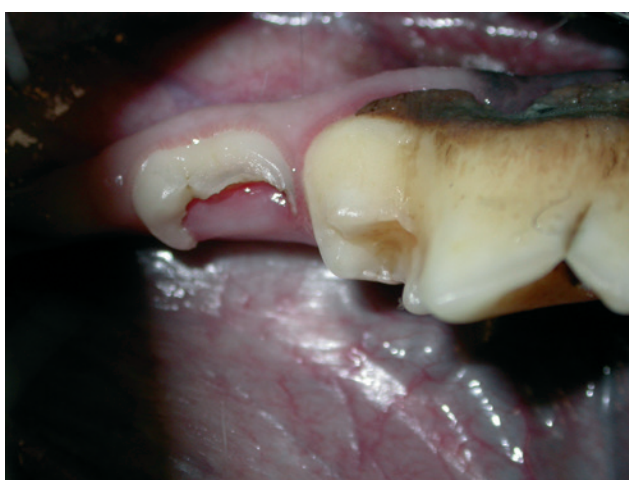Fig. 4 Bull terrier with a lingually displaced mandibular canine





*Fig. 5 Cavalier Eosinophilic granuloma complex*



*Fig. 6 Dental caries in a Dalmatian*

There have been great advances in diagnostic techniques providing many tests that help to confirm the genetic basis of disease. The number of such tests will probably increase every year and thus this, the most reliable basis for diagnosis, will play an increasingly important role. However, the first step in any diagnosis must be a thorough examination of the patient, with particular attention to the specific symptoms and following this considering the differential diagnosis.

For many years the selection process employed with breeding animals concentrated on characteristics such as the appearance only. Health issues were not considered by selection committees. This approach consolidated the presence of certain diseases and defects in the population of pedigree dogs<sup>[5]</sup>. Many breeds of dog are drastically different from the appearance of their ancestors. Even some metabolic and immune mediated defects<sup>[6]</sup>.within the domestic dog population are now considered to have an

hereditary basis and this fact has been totally ignored in breeding selection.

This paper describes PSAVA proposals for an evidence based system to record the occurrence of oral and maxillofacial hereditary defects in a population of pure-bred dogs. These proposals are coordinated by the Board of PSAVA and its Scientific Pedigree Dogs committee and are parallel to PSAVA projects carried out by other disciplines (ophthalmic, diagnostic imaging, cardiology, etc.) The Dental working group of PSAVA developed a list which includes 49 breeds, among which examples of both single and multiple defects can be found. Each specific disease or problem related to the breed is referred to in the literature. The diagnosis of a particular disease is based on precise criteria such as clinical assesment, imaging and laboratory tests (histopathology and/or genetic). Documentation of registered diseases should be either photographic or radiographic. In addition, each problem was evaluated in terms of its negative influence on the health and vital functions of the animal. This 'negative score' was shown in a scale of 1-3 with 1 being the lowest and 3 the highest level of deleterious effect (Table 2).

*Table 2 Ranking of negative influence on the health and vital functions of the animal.*

Ranking	Clinical importance
1	Low and moderate effect on life quality. Treatment not always necessary
2	Significant influence on life comfort and quality. Mandatory treatment.
3	Critical influence on Health. Mandatory treatment, in severe cases the likely consideration of euthanasia.


The clinical evaluation in addition to the certification process is shown in the forms on the next two pages. This is carried out by veterinarians who meet specific requirements established by the PSAVA Board of Hereditary Problems Certification. Breeders or pet owners who are interested in subjecting their dogs to the test will receive a certificate describing the presence or absence of specific genetic problems in the assessed individual.

The final decision as to how the results of this certification test can be used in the context of selective breeding of pedigree dogs is made independently by the Polish Kennel Club.



Example figure: The assessment charts used in Poland (2 pages)

## CANINE ORAL AND MAXILLOFACIAL ASSESSMENT CHART




<b>Date of examination</b> 13.01.2009		<b>Number</b> 001/2009		
<b>Owner</b>	Grażyna Gawor, Kraków ul. Chłopska 2a			
<b>Dog</b>	<b>Full name</b>	Chelsea, Momot		
	<b>Sex</b> samica	<b>Date of birth</b> 22.04.2005		
	<b>ID</b>	MC 1272647973247		
	<b>Breed</b>	Boxer		
	<b>Umaszczenie</b> <b>Kennel club</b> <b>Oral treatment</b>	żółta Małopolski Gingivectomy/gingivoplasty		
<b>Breed predispositions</b>	<i>Supernumerary teeth</i>	<i>Cleft palate</i>	<i>Gingival hyperplasia</i>	<i>Retained teeth</i> <i>Dentigerous cyst</i>
<b>Clinical assesment</b>	SN 102	Not found	Pseudopockets	Missing 305
<b>Radiographic evaluation</b>	Fused tooth			DTC 305
<b>Laboratory results</b>			Histopathology: gingival hyperplasia	
<b>Photographic documentation</b>	yes			yes
<b>Ranking</b>	1	0	1	2
<b>Total</b>	4			

**Authorised Veterinary Surgeon:** Jerzy Gawor


Example figure: The assessment charts used in Poland (2 pages)

## CANINE ORAL AND MAXILLOFACIAL ASSESMENT CHART




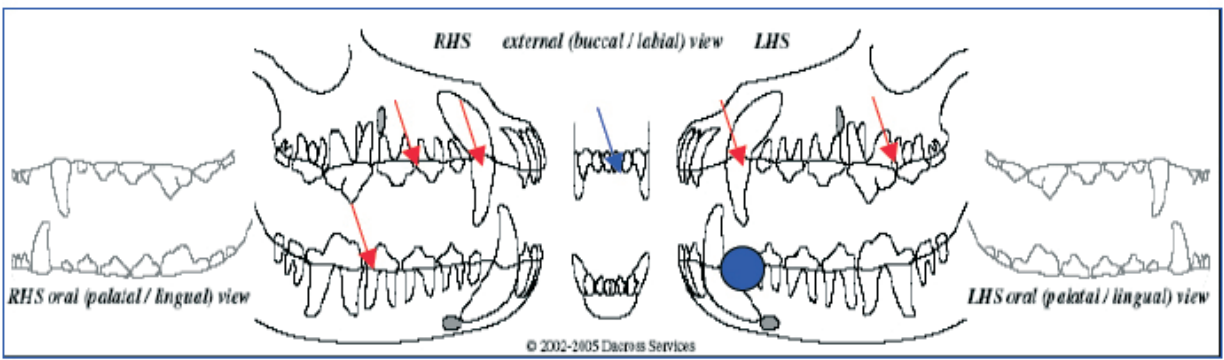
**Appendix to oral assesment:**

**Scull type:** brachycephalic/ mesocephalic/ dolichocephalic;



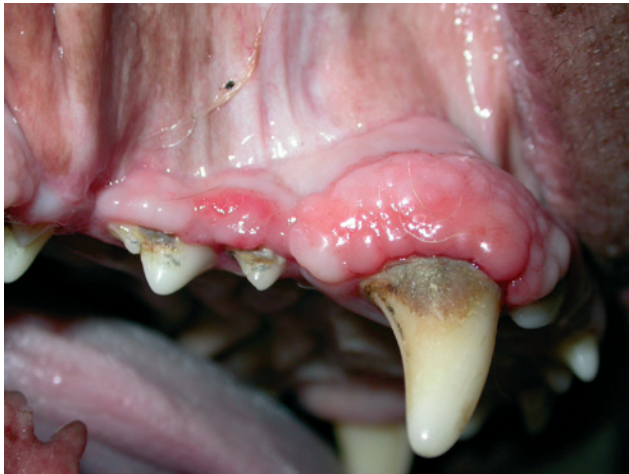**Occlusion:** normocclusion, **Class I:** anterior cross-bite/ posterior cross-bite/ linguoversion, mesioversion/teeth crowding/ rotated teeth **Class II:** mandibular distoclusion/ prognathia/ wry bite/ **Klasa III** progenia/ retrognathia wry bite/level bite. **Class IV** – wry bite  
Open occlusion/traumatic occlusion



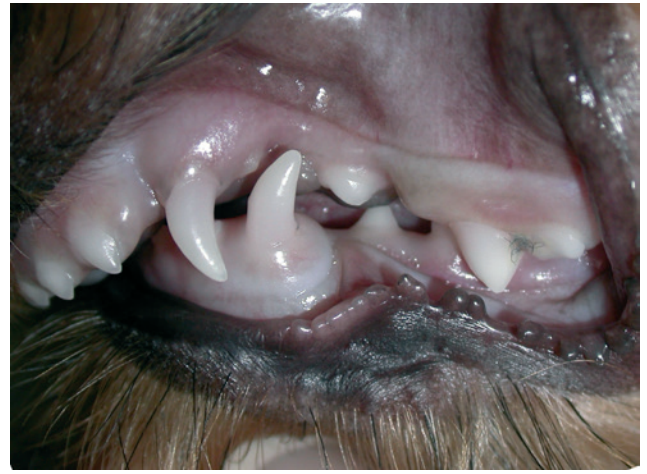

© 2002-2005 Dacris Services

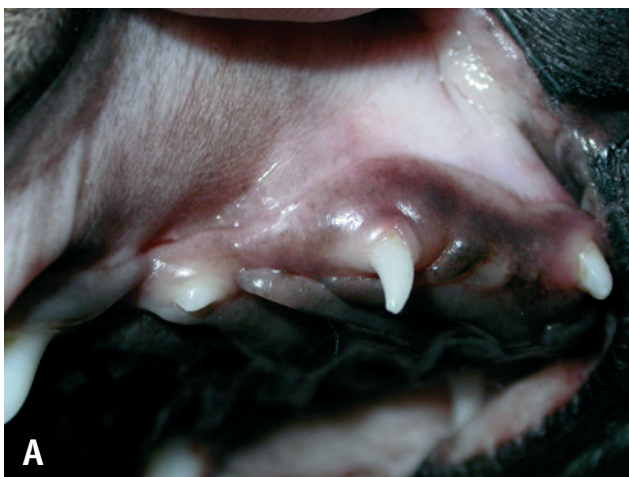**Authorised Veterinary Surgeon** *Jerzy Gawor*



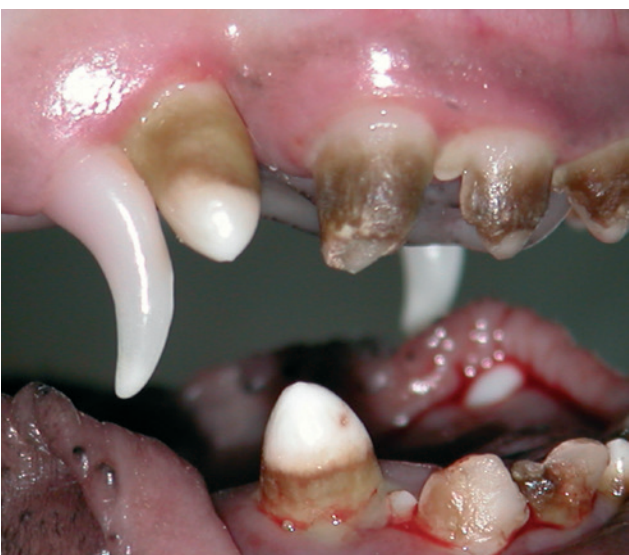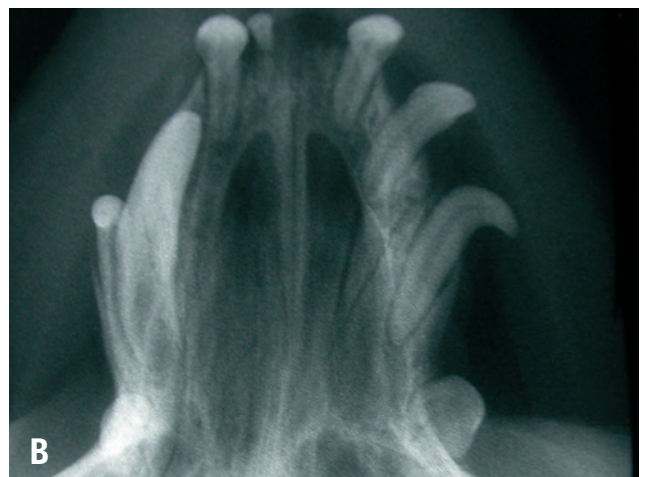*Fig. 7 Great Dane with gingival hyperplasia*



*Fig. 9 Longhaired dachshund showing Retrogenia*



*Fig. 8. Oligodontia in a chinese crested dog*



*Fig. 10 Standard poodle showing enamel hypoplasia*



*Fig. 11 Rottweiler vitiligo*

Some of the listed problems such as Cranio-Mandibular Osteopathy or UV syndrome <sup>[7,8]</sup> are not located exclusively in the mouth but all of them affect oral health and/or function. Other problems such as gingival hyperplasia or supernumerary teeth <sup>[9,10]</sup> are 'just dental' but also influence general health. There are few problems of a

systemic nature which have a strong influence on the oral cavity (eg.von Willebrand disease <sup>[11]</sup>) especially when oral surgery or dental procedures are performed. Certain anatomical anomalies have shown a tendency to be inherited, and also occur more frequently in certain breeds (for example gingival hyperplasia in Boxers or



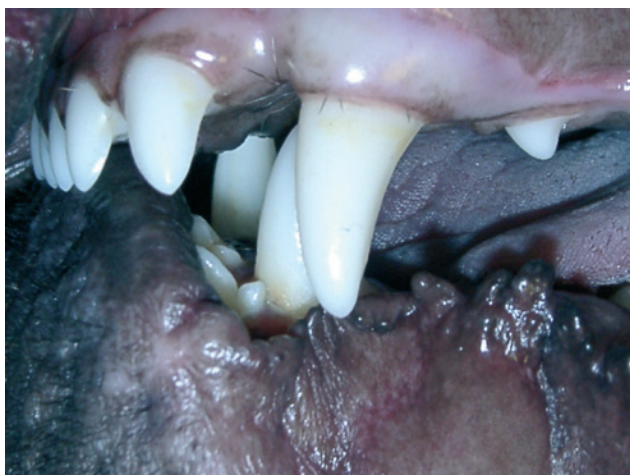

Fig. 12 Shar pei with the 'Tight lip' syndrome

retrogenia [Receding lower jaw and/or mandibular distocclusion] in Longhaired Dachshunds [12,13].

Some of the described problems may appear controversial because there is no proof of their hereditary origin, but clinical observations in the population of a particular breed indicate their strong tendency to appear to be inherited. An example of this is persistent primary dentition in the Yorkshire terrier. Historically, the anomaly which was considered most frequently as being hereditary and for which a genetic factor exists which can be selected against in breeding, is the cleft palate [15]. Among oral problems, there are diseases that slightly affect quality of life but carry a potential risk of serious complications developing if neglected, not treated or not treated properly. Examples are retained, impacted, or missing teeth. Disorders of tooth eruption may be of two types: a generalised disorder such as delayed eruption in the Tibetan terrier [14] or a more local one such as impaction of the first mandibular premolar followed by formation of odontogenic cysts as occurs in the Shi-tzu and brachycephalic dogs [15].

In this study, there are no specific clinical descriptions of disease entities, but these can be seen in the illustrations which show the selected most important symptoms. The PSAVA proposal will help address the growing problem of the presence genetic defects in the pedigree animal pool.

Veterinarians and pet owners often feel that purchasing a 'pedigree' dog is tantamount to a warranty that the animal is free from defects and serious diseases. In fact such a warranty cannot be provided even with the best control system. The existing selection criteria leave many

opportunities for the introduction of individuals into reproductive pool that will then pass on negative traits to their offspring. Current knowledge allows us to determine which defects are indisputably dangerous to life and compromise the health of the dog and which others at the moment seem to be less important to quality of life [16,17,18].

It is important to add to the list some conditions which seems to be just 'cosmetic' but which may in fact seriously affect health or have other severe consequences [19].

For many years, veterinarians have attempted to increase the control of hereditary diseases in pedigree dogs [20,21,22]. These efforts are well articulated in the recommendations for Kennel Clubs and the professional media. Specific recommendations can be found in Finland, Norway, Canada and The Netherlands [23,24,25,26]. Additionally, in 2004 in Greece (Rhodes) at the FECAVA European Congress, the subject of the FECAVA symposium was congenital defects and diseases [27,28,29].

In order to help in the diagnosis of hereditary diseases a selection of diagnostic methods is suggested (Table 1.) A useful method of recording the results is described in Table 3 alongside each condition.

The examination must be carried out by an authorised veterinary surgeon, licensed for that purpose. It must follow the agreed protocol which will be specific to the breed and condition as will the certificate issued if the animal is approved. In Poland competent Veterinary surgeons are authorized by a Committee of the PSAVA. Authorization has to be verified regularly and attention is paid to the Veterinary surgeon's CPD and CE record. More information is available on <http://www.pslwmz.org.pl/index.php/stomatologia> This website allows translation in English.

For all conditions examined a score of 1-3 points (Table.2) is given. One point indicates a low level of affect on the quality of life. Treatment is not always necessary. Two points are assigned to animals with more serious problems whilst 3 points would result in the animal being disqualified from breeding because of the severe effect of the condition on the health, functionality and quality of life of the dog.

Points can be given for more than one condition in an animal, for example a boxer affected by gingival hyperplasia, supernumerary dentition and dentigerous



cysts each only giving one or two points but resulting in a total collect of 4 points. When the total number of points collected during evaluation of the animal exceeds 3, this fact should also be treated as the presence of eliminating fault.

At the moment very few health problems have a significant impact on the decision as to whether or not to allow an individual to reproduce. Dental problems which are taken into account are the number of teeth and malocclusion<sup>[30]</sup>. Many other important anatomical and metabolic disorders or abnormalities are ignored.

One must assume that this situation will result in a growing number of dental disorders in pure-bred dogs. Table 3 shows in which breeds dental problems are most frequently found.

All of these conditions should be treated to remove or at least palliate the condition. The aim is to limit the ability of affected animals from spreading the problem within breed.

Most conditions can be successfully treated, although it can sometimes be time consuming and expensive. An animal which receives a certificate confirming the absence of diseases that can be inherited can be declared to have: No evidence of oral and maxillofacial genetic, hereditary or breed predisposition diseases. A copy of the certificate can be seen in the dental section of [www.pslwmz.org.pl](http://www.pslwmz.org.pl)

The list of conditions, standards of assessment and other methodology will be reviewed every year by the Project Management Board of PSVA .

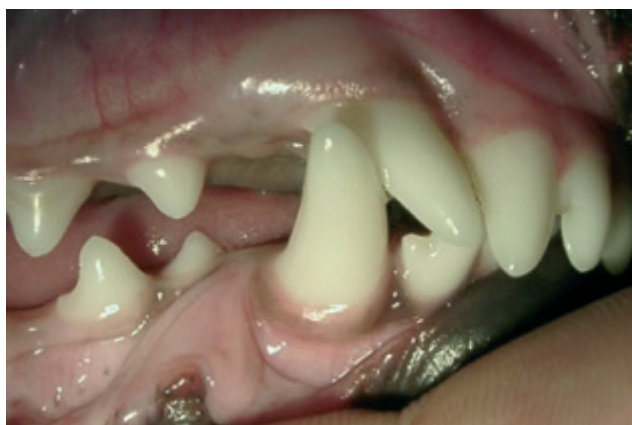

Fig. 13 Sheltie with lance teeth

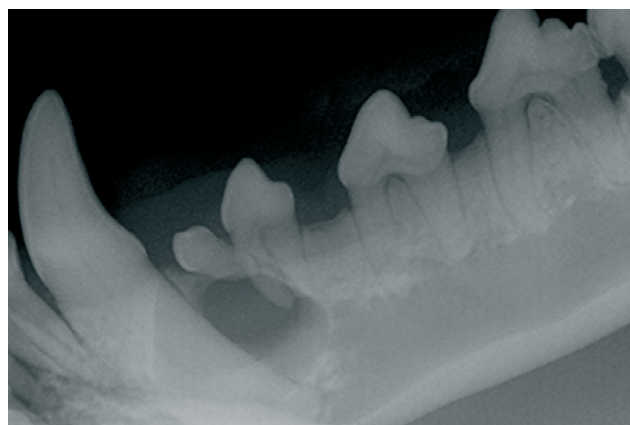


Fig. 14 Shi-Tzu with a Dentigerous cyst

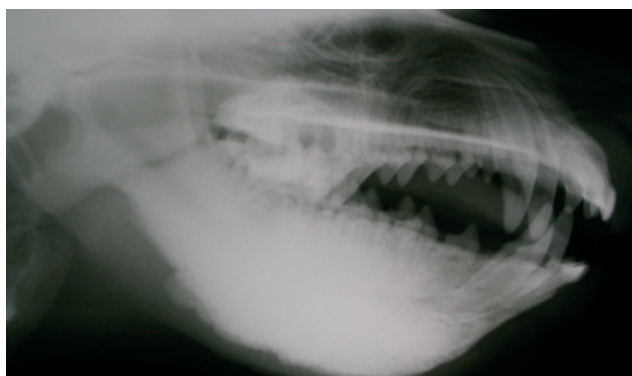

Fig. 15 WHWT CMO

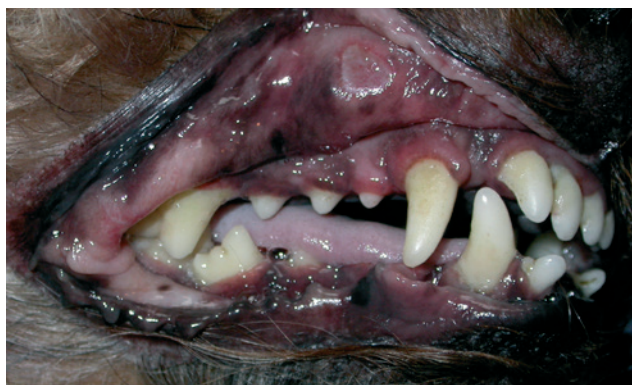

Fig. 17 Plaque associated stomatitis in the Yorkshire terrier

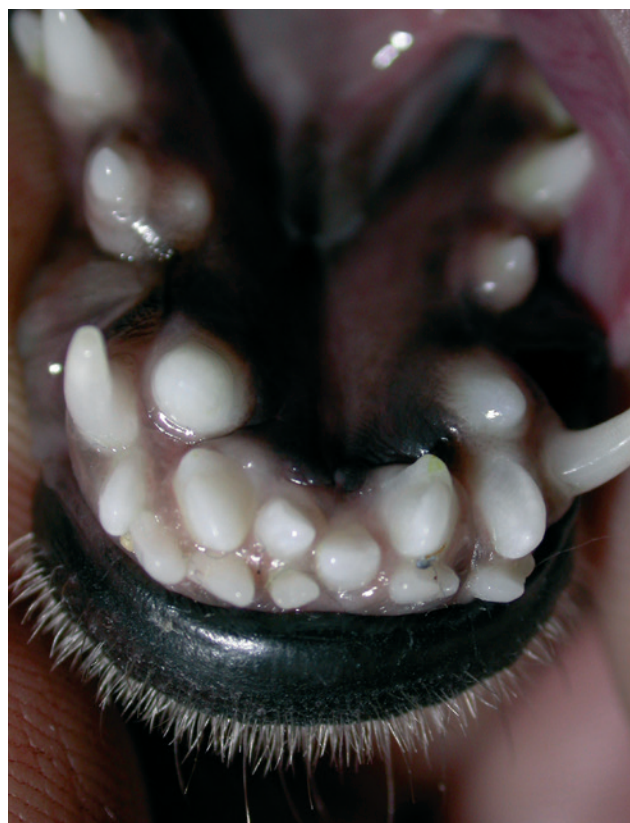

Fig. 16 Persistent deciduous teeth in the Yorkshire terrier

*Table 3 List of breeds and the problems associated with these breeds, together with the required diagnostic methods and ranking of clinical importance The Abbreviations used can be seen at the end of this paper before the references*

Breed	Required diagnostic method and record	Problem	Ranking of clinical importance Tab1
Akita inu	C, Ph X	Uveodermatologic syndrome (UV-syndrome) TMJ dysplasia; open mouth locking syndrome	3 3
American cocker spaniel	X	TMJ dysplasia; open mouth locking syndrome (Fig.1)	3
Basset hound	X	TMJ dysplasia; open mouth locking syndrome	3
St. Bernard	C, Ph C, Ph	Cheilitis due to macrocheilia Cleft tongue, Bifid tongue	1 3
Boxer	C, Ph, X C, Ph C, Ph C, X X	Supernumerary teeth, Cleft palate (Fig.2 ) Gingival hyperplasia Retained teeth Dentigerous cyst	1 3 1 2 2
Brittany Spaniel	C, Ph	Cleft palate	3
Boston terrier	C, Ph	Elongated soft palate	2
English bulldog	C, Ph, X C, Ph C, Ph	Elongated soft palate (Fig. 3) Supernumerary teeth, Wry mouth	2 1 2
French bulldog	C, Ph C, X	Elongated soft palate Teeth overcrowding	2 1
Bull terrier	C, Ph	Lingually displaced Canines (Fig.4)	1
Bullmastif	C, X	Idiopathic calvarial hyperostosis	2
Cairn terrier	X, H	Cranio-mandibular osteopathy (CMO)	3
Cavalier King Charles spaniel	C, Ph, H C, Ph X C, Ph H	Plaque associated stomatitis Lip fold dermatitis TMJ dysplasia; open mouth locking syndrome Oral form of the Eosinophilic granuloma complex (Fig.5)	2 1 3 2
Italia Greyhound	C, R	Lance teeth	2
English Cocker spaniel	C, Ph X	Lip fold dermatitis Abnormalities in skull development	1 2
Collie	L C, X C, H	Grey Collie syndrome, Lance teeth Gingival hyperplasia	3 2 1
Dalmation	C, X C, H	Caries (Fig.6) Gingival hyperplasia	1 1
Doberman	G C, H	v. Willebrand's disease Gingival hyperplasia	3 1
Great Dane	C, H	Gingival hyperplasia (Fig.7)	1
Dogue de Bordeaux (Bordeaux Mastiff)	C, H	Gingival hyperplasia	1
Chinese crested dog	C, X	Oligodontia (Fig. 8a and 8b)	2
Longhaired Dachshund	C, X C, Ph C, Ph	Lance teeth Retrogenia (Fig .9) Lingually displaced Canines	2 2 2
Shorthaired Dachshund	C, X C, Ph C, Ph, X	Lance teeth Lingually displaced Canines Periodontopathy of the palatal aspect in maxillary cuspids	2 2 1
Kerry blue terrier	C, X	Oligodontia	1

Table3 Continued ...

Breed	Required diagnostic method and record	Problem	Ranking of clinical importance Tab1
Labrador retriever	X	TMJ dysplasia; open mouth locking syndrome	3
Lhasa apso	C, X	Teeth overcrowding	1
	C, X	Retained teeth	2
	X	Dentigerous cyst	2
Maltese terrier	C, Ph, H	Chronic Ulcerative Periodontitis/Stomatitis (CUPS )	2
Pug	C, Ph	Elongated soft palate	2
Anatolian shepherd	C, Ph	Ankyloglossia (tongue tie)	1
German shepherd	C, Ph	Retrogenia	2
	C, Ph	Lingually displaced Canines	2
	L	Masticatory Muscle Myositis MMM	3
Tervuren	C, Ph	Vitiligo (loss of colour)	1
Pointer	C, Ph	Retrogenia	2
Standard Poodle	C, Ph, X	Periodontopathy of the palatal aspect in maxillary cuspids	1
	C, X, Ph	Hypoplasia of the enamel (Fig.10)	2
Rottweiler	C, Ph	Vitiligo (Fig.11)	1
	L	Masticatory muscle myositis (MMM)	2
Samoyed	C, L	Uveodermatologic syndrome (UV-syndrome)	3
Irish Setter	C, Ph, X	Supernumerary teeth,	1
	C, Ph	Lip fold dermatitis	1
	X	TMJ dysplasia; open mouth locking syndrome	3
Shar-pei	C, Ph	'Tight lip' syndrome (Fig .12)	2
	C, Ph	Retrogenia	2
	C, Ph	Lingually displaced Canines	2
Sheltie	C, X	Lance teeth (Fig.13)	2
Shi-tzu	X	Dentigerous cyst (Fig.14)	2
	C, X	Teeth overcrowding	1
	C, X	Periodontal disease	1
Springer spaniel	C, Ph	Lip fold dermatitis	1
	C, X	TMJ dysplasia; open mouth locking syndrome	3
Syberian husky	C, Ph, H	Plaque associated stomatitis	1
	C, L	Uveodermatologic syndrome; (UV-syndrome)	3
	C, H	Eosinophilic granuloma complex with oral expression	2
Schnautzer	C, Ph	Microcheilia (swollen lips)	2
Miniature Schnautzer	C, Ph	Microcheilia	2
	G	Myotonia congenita.	3
Tibetan terrier	C, X	Delayed teeth eruption	2
Scottish terrier	X, H	Craniomandibular osteopathy (CMO)	3
	C, Ph, H	Plaque associated stomatitis	1
Weimeraner	X	TMJ dysplasia; open mouth locking syndrome	3
West highland white terrier	X, H	Craniomandibular osteopathy (CMO) (Fig. 15)	3
Wheaton terrier	C, Ph	Delayed teeth eruption	2
Yorkshire terrier	C, X	Persistent deciduous teeth (Fig .16)	2
	C, Ph	Teeth crowding	1
	C, Ph, H	Plaque associated stomatitis (Fig .17)	1

References to Table 3 available upon request: jgawor@pp.com.pl

## Abbreviations

- Ph Photographic documentation is performed to record the symptoms of the disease, which are considered pathognomic or typical for a particular disease.
- G Genetic testing at the moment does not apply to certain diseases simply because there is no commercial test available as yet (though it is likely that a test may appear test for CMO). If there is no test available, another of the diagnostic criteria must be fulfilled (for example in the case of CMO this would be radiological and histopathological examination) <sup>[34]</sup>.
- H Histopathological examination should be performed in referral laboratories, the evaluation being undertaken by qualified veterinary pathologists <sup>[35]</sup>.
- L Laboratory testing refers to a number of diseases listed in Table 3. (Laboratory tests do not embrace genetic tests in the context of this paper)
- C Clinical assessments are those which follow the standards of EVDC, AVDC or AVD. These include the physical assessment of the oral cavity, bite, periodontium, dentition and mucous membranes. The documentation of such a study should follow a standard protocol of oral examination and photography. Photographs should be taken of any specific features of the problem and should always be correctly positioned and of good quality and magnification <sup>[36]</sup>.
- X Radiographic examination must be carried out according to standard rules and using appropriate imaging equipment and positioning. Image represents diagnostic value based on its resolution, contrast and projection<sup>[37]</sup>.

It will be possible to introduce additional evaluation criteria and new problems which arise if they are considered hereditary.

The aim is to encourage breeders to participate in the project on voluntary basis. Hopefully some Kennel Clubs may be prepared to accept that mandatory controls are needed for some conditions in some breeds. This PSAVA dentistry project will hopefully pioneer a new approach to selective breeding enhancing the quality of life of our pets.

The results of the oral assessment protocol will be archived by the veterinarian, a copy being given to the pet owner as well as to the Project Management Board of PSAVA. The age of the animal being evaluated will depend on the problem and breed concerned but in general the aim is to perform this assessment twice at the age of 6 and 14 months in all breeds.

Efforts have been made for many years in the past to control the degenerative diseases of the elbow and hip and these have faced many barriers and constraints from both veterinarians and breeders. Both mentioned diseases cause very serious defects that threaten the normal functionality of the affected pet <sup>[31,32,33]</sup>. PSAVA hopes that, in agreement with the Kennel Club, breeders will be encouraged to work together to improve the dental health of dogs and control of inherited diseases in the pure-bred dog population. The proposals outlined in this paper could become the basis of further general discussion of inherited disease which, in the author's opinion, would be very worthwhile.

## These Abbreviations are also used in the tables:

- AVD - Academy of Veterinary Dentistry  
 AVDC - American Veterinary Dental College  
 CMO - Craniomandibular osteopathy  
 CUPS - Chronic Ulcerative Periodontitis/Stomatitis  
 EGC - Eosinophilic Granuloma Complex  
 EVDC - European Veterinary Dental College  
 FAB - Feline Advisory Bureau  
 FCI - Fédération Cynologique Internationale  
 MMM - Muscle Masticatory Myositis  
 PSAVA - Polish Small Animal Veterinary Association  
 TMJ - Temporo mandibular joint  
 UV-syndrome - Uveodermatologic Syndrome



## References

- [1] Koharik A. A new direction for kennel club regulations and breed standards CVJ / Vol 48 / September 2007
- [2] Meyers-Wallen VN. Ethics and genetic selection in purebred dogs. *Reprod Domest Anima*. 2003 Feb;38(1):73-6.
- [3] Inherited disorders in cats - confirmed and suspected. Available at: <http://www.fabcats.org> Feline Advisory Bureau.
- [4] Mellersh C. Give a dog a genome. *Vet J*. 2008 Oct;178(1):46-52. Epub 2007 Sep 11.
- [5] Sampson J. The geneticist's view on dog breeding: How can improved health be achieved. The FECAVA Symposium, WSAVA/FECAVA Congress, Rhodes 8th Oct 2004
- [6] Ackerman L. The Genetic Connection: A Guide to Health Problems in Purebred Dogs. Colorado: AAHA Press, 1999:1-28.
- [7] Gawor J. Craniomandibular Osteopathy in Dogs. *Proc of BVDA 18th Scientific meeting* 19th April 2006 Birmingham 8.
- [8] Kern TJ, Walton DK, Riis RC, Manning TO, Laratta LJ, Dziezyc J. Uveitis associated with poliosis and vitiligo in six dogs. *J Am Vet Med Assoc*. 1985 Aug 15;187(4):408-14.
- [9] Lewis JR, Reiter AA. Management of Generalized gingival enlargement in a dog- case report and literature review. *J Vet Dent* 22(3) 160-169, 2005
- [10] Wiggs RB, Lobprise HB. Clinical Oral Pathology in Veterinary Dentistry Principles and Practice, Lippincott-Raven, 1997. 104-139
- [11] Brooks MB, Erb HN, Foureman PA, Ray K. von Willebrand disease phenotype and von Willebrand factor marker genotype in Doberman Pinschers. *Am J Vet Res*. 2001 Mar;62(3):364-9.
- [12] Gawor J. Nadziąślaki - aktualne informacje na temat rozpoznawania i leczenia u psów i kotów *Magazyn Wet.* 2005, Nr 5, 12
- [13] Gruneberg H, Lea AJ. An inherited jaw anomaly in long haired dachshunds. *J Genet* 1940, 39, 285-296
- [14] Gawor J. Kliniczna i radiologiczna ocena uzębienia u szczenięcia w trakcie wyrzynania. *Przypadek kliniczny*. *Zycie Wet* 2008/12
- [15] Edmonds, L., Stewart, R.W., Selby, L.: Cleft lip and palate in dogs (Boxer breed): a preliminary report, *Carnivore Genetics Newsletter* 9:204-209, 1972.
- [16] Stapleton B.L., Clarke L.L. Mandibular Canine tooth impaction In a young dog treatment and subsequent eruption a case report *J Vet Dent* 16(3) 105-108, 1999
- [17] Okuda Ayako. Dentigerous Cysts In Brachycephalic breed dogs and diagnostic findings and treatment with bone augmentation. WSAVA 2003 Congress proceedings 24-27 October 2003, Bangkok Thailand. 121-122
- [18] Gough A., Thomas A. Predyspozycje rasowe do chorób u psów i kotów SIMA WLW, Warszawa 2006
- [19] McGreevy PD, Nicholas, FW. Some practical solutions to welfare problems in dog breeding. *Animal Welfare* 1999;8:329-341.
- [20] Surgeon T.W. 2007. Indications planning and ethical considerations for orthodontic treatment. *Pesquisa Veterinária Brasileira* 27(Supl.).
- [21] Giger U. Hereditary & Genetic Diseases Modern Diagnostics for Hereditary Disorders in Dogs and Cats *Proc of XXVIII WSAVA Congress Bangkok*, Thailand 24-27 2003
- [22] Evans RI, Herbold JR, Bradshaw BS, Moore GE. Causes for discharge of military working dogs from service: 268 cases (2000-2004). *J Am Vet Med Assoc*. 2007 Oct 15;231(8):1215-20.
- [23] Hernandez M. Breed Predisposition to Oral Pathology. *Proc of 8th WCVD Kyoto* July 11-13 2003 126-8
- [24] Mullan S, Main D. Principles of ethical decision-making in veterinary practice. In *Practice* 2001:396-401.
- [25] Leppänen M, Paloheimo A, Saloniemi H. Attitudes of Finnish dog-owners about programs to control canine genetic diseases. *Prev Vet Med*. 2000 Feb 1;43(3):145-58.
- [26] Indrebo A. Breeding of healthy dogs - a breeders perspective. The FECAVA Symposium, WSAVA/FECAVA Congress, Rhodes 8th Oct 2004
- [27] Koharik A. A new direction for kennel club regulations and breed standards CVJ / Vol 48 / September 2007
- [28] van Hagen MA, Janss LL, van den Broek J, Knol BW. The use of a genetic-counselling program by Dutch breeders for four hereditary health problems in boxer dogs. *Prev Vet Med*. 2004 Apr 30;63(1-2):39-50
- [29] Sampson J. The geneticist's view on dog breeding: How can improved health be achieved. The FECAVA Symposium, WSAVA/FECAVA Congress, Rhodes 8th Oct 2004
- [30] Indrebo A. Breeding of healthy dogs - a breeders perspective. The FECAVA Symposium, WSAVA/FECAVA Congress, Rhodes 8th Oct 2004
- [31] Hedhammar I. FCI approach to health dog breeding, The FECAVA Symposium, WSAVA/FECAVA Congress, Rhodes 8th Oct 2004
- [32] Giger U. Hereditary & Genetic Diseases Modern Diagnostics for Hereditary Disorders in Dogs and Cats *Proc of XXVIII WSAVA Congress Bangkok*, Thailand 24-27 2003
- [33] Gawor J., Szczenię jako pacjent stomatologiczny. *Mag. Wet.* 13, 87. 9-12 2004.
- [34] Wiggs R.B., Lobprise H.B. Oral Examination and Diagnosis in.: *Veterinary Dentistry Principles and Practice*, Lippincott-Raven, 1997. 87-104
- [35] DuPont G., DeBowes L. *Atlas of Dental Radiography*. Elsevier Saunders 5-122, 2009
- [36] FCI Standards and nomenclatures dost pne na stronie; <http://www.fci.be/nomenclatures>
- [37] Alekiewicz R, Budzi ska Z, Nowicki M, Adamiak Z, Lisiecka B. Canine hip dysplasia of selected breeds- results obtained by two Polish clinics based on radiological examination conducted in 1997-2006. *Pol J Vet Sci*. 2008;11(2):139-42.

- [38] Everts RE, Hazewinkel HA, Rothuizen J, van Oost BA. Bone disorders in the dog: a review of modern genetic strategies to find the underlying causes. *Vet Q.* 2000 Apr;22(2):63-70.
- [39] LaFond E, Breur GJ, Austin CC. Breed susceptibility for developmental orthopedic diseases in dogs. *J Am Anim Hosp Assoc.* 2002 Sep-Oct;38(5):467-77.



## COMMISSIONED PAPER (SE)

# Genetic background of acquired cardiac disease in dogs

Jens Häggström<sup>1</sup>, Katja Höglund<sup>2</sup>, Ingrid Ljungvall<sup>1</sup>

## SUMMARY

The two most common forms of acquired heart disease, myxomatous mitral valve disease (MMVD) and dilated cardiomyopathy (DCM), are more common in some breeds than others. Genetic factors have therefore long been suspected to be important for development of these two common heart diseases. The mode of inheritance for MMVD has been suggested as a polygenetic threshold trait, whereas DCM, with the exception of a few breeds, has been suggested inherited as an autosomal dominant trait. Associations between genomic regions and presence of disease has been described for both MMVD in Cavalier King Charles Spaniels and for DCM in multiple breeds, but causative mutations have, so far, only been suggested for DCM in Doberman Pinschers and in Boxer dogs. The present article is aimed at reviewing the genetic factors for the two most common forms of acquired heart disease, MMVD and DCM, in particularly affected breeds, and furthermore to outline the current screening programmes aimed at identifying diseased dogs and reducing prevalence of heart disease by breeding measures.

This paper was commissioned by FECAVA for the special issue of EJCAP, Genetic/Hereditary Disease and Breeding.

## Introduction

Various types of heart disease and their sequels, congestive heart failure (CHF) or sudden death, are frequently encountered in dogs. Cardiac patients account for about 5-10% of the total number of patients in small animal practice [Buchanan 1992]. Swedish animal actuarial data concerning claims for refund due to death/euthanasia shows that the mortality caused by heart disease accounts for 7-10%, and is the third most common identified cause for death after neoplastic disease and traumatic disease [Egenvall, Bonnett et al. 2000, Egenvall, Bonnett et al. 2000, Bonnett, Egenvall et al. 2005]. Heart disease is often grouped into two groups: congenital and acquired. Congenital heart disease

means that the disorder was present already at birth, whereas acquired heart disease develops at some time point after birth. Acquired heart disease accounts for the vast majority of cases of heart disease in dogs. The predisposition for acquired heart disease varies between breeds, where some, such as Doberman Pinschers, Great Danes, and Boxer dogs, are predisposed to acquired myocardial disease, i.e. dilated cardiomyopathy (DCM) whereas others, such as Cavalier King Charles Spaniels (CKCS) and Dachshund, are predisposed to acquired valvular disease, i.e. myxomatous mitral valve disease (MMVD) [Egenvall, Bonnett et al. 2000, Egenvall, Bonnett et al. 2000, Bonnett, Egenvall et al. 2005]. It may appear obvious that genetic factors play a major role in the development of congenital heart disease, whereas this may not be as obvious for acquired heart disease. However, it is now convincingly shown that genetic factors also play a major role in the development of MMVD and DCM, the two most common types of acquired

1 Department of Clinical Sciences, and (2) Anatomy, Physiology, and Biochemistry, Faculty of Veterinary Medicine and Animal Science, Swedish University of Agricultural Sciences, Uppsala, Sweden  
E-mail: Jens.Haggstrom@slu.se

heart disease in dogs. [Martin, Stafford Johnson et al. 2010, Mausberg, Wess et al. 2011, Meurs, Lahmers et al. 2012, Meurs, Mauceli et al. 2010, Palermo, Stafford Johnson et al. 2011, Philipp, Vollmar et al. 2008, Stephenson, Fonfara et al. 2012, Hazlett, Maxie et al. 1983, Smucker, Kaul et al. 1990, Swenson, Haggstrom et al. 1996, Dambach, Lannon et al. 1999, Olsen, Fredholm et al. 1999, Meurs, Miller et al. 2001, Basso, Fox et al. 2004, Meurs 2004, Distl, Vollmar et al. 2007, Werner, Raducha et al. 2008, Lewis, Swift et al. 2011, Madsen, Olsen et al. 2011] Studies indicate, however, that although genetic factors do appear to play an important role for causing acquired heart disease, the genetic background and mode of inheritance are not as simple as initially thought.

Comparably much work has been conducted where the genetic background of MMVD and DCM have been investigated. [Swenson, Haggstrom et al. 1996, Meurs 1998, Olsen, Fredholm et al. 1999, Meurs 2005, Stephenson, Häggström et al. 2012] The reason for this is three-fold. Firstly, the differences in prevalence and specific types of heart disease between breeds are striking. For example, the likelihood is 11 times greater for a CKCS to die or become euthanised because of heart disease compared to the mean of all other breeds. [Haggstrom, Hansson et al. 1992, Egenvall, Bonnett et al. 2000, Egenvall, Bonnett et al. 2000, Bonnett, Egenvall et al. 2005] Secondly, because of the technical advances in medical science, strict definitions of disease exist in comparison to other types of disease, such as neurological disorders. Thirdly, the purebred dog has undergone two major population bottlenecks, one recent in the form of breed creation and the second much older selection to create domestic animals. [Karlsson and Lindblad-Toh 2008, Larson, Karlsson et al. 2012] These processes formed the genetic structure of the dog and can be used to break the genome into blocks (haplotypes) that are inherited from parent to offspring. Within a single breed we can see that these haplotypes are long ( $\sim 0.5\text{-}1 \times 10^6$  nucleotides), but are much shorter ( $1 \times 10^4$  nucleotides) between breeds. This genetic structure within and between breeds has opened up the possibility of using dogs with naturally occurring disease as models for human disease, including heart disease. [Karlsson and Lindblad-Toh 2008, Lequarre, Andersson et al. 2011]

The present article is aimed at reviewing the genetic background for the two most common forms of acquired

heart disease, MMVD and DCM, in particularly affected breeds, and furthermore to outline the current screening programmes aimed at identifying diseased dogs and reducing prevalence of heart disease by breeding measures.

## Myxomatous mitral valve disease (MMVD)

Myxomatous mitral valve disease is the most common type of heart disease in dogs and has been reported to account for 75% of cases of heart disease in dogs, [Das and Tashjian 1965, Detweiler and Patterson 1965, Buchanan 1992, Olsen, Häggström et al. 2010] but with a considerably higher proportion in predisposed breeds. [Haggstrom, Hansson et al. 1992, Egenvall, Bonnett et al. 2000, Egenvall, Bonnett et al. 2000, Bonnett, Egenvall et al. 2005, Olsen, Häggström et al. 2010] The disease leads to progressive lesions on primarily the mitral valve and associated chordae tendineae, although any of the four heart valves may be affected. The lesions are characterized by elongation of the chordae tendineae and bulging (prolapse) of the leaflets into the atrium, which, in turn lead to incomplete coaptation of the leaflets and valve insufficiency. [Pedersen, Kristensen et al. 1995, Olsen, Häggström et al. 2010] The disease in dogs has many similarities with MMVD in people and has therefore been proposed a good model for this disease (Fig 1, 2A-C.). [Pedersen and Häggström 2000] With progression the valve leakage becomes more pronounced and secondary changes to heart chamber dimensions develop. Finally, signs of CHF may develop. The disease typically develops in middle-aged to old dogs of small to medium sized breeds, and the prevalence of disease is higher in

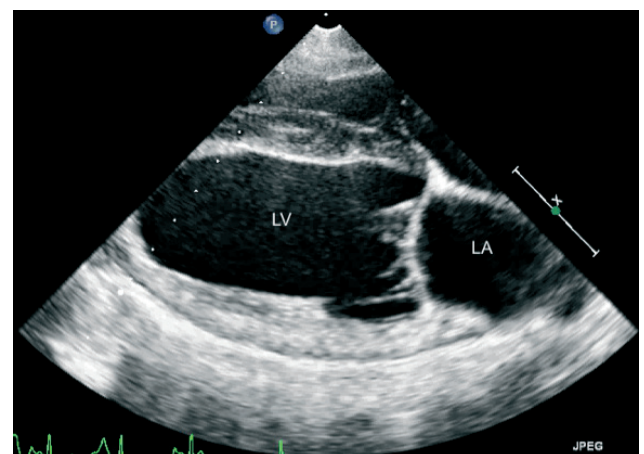


Fig 1 Two dimensional echocardiogram in the right parasternal long axis view of a normal dog LV, left ventricle; LA, left atrium



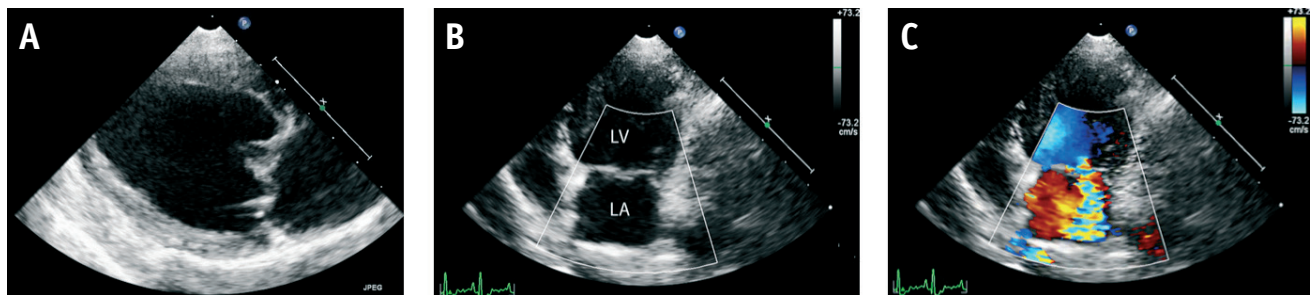


Fig. 2 Two dimensional echocardiogram in the right parasternal long axis (A.) and left apical 4 chamber (B. and C.) views of dogs with myxomatous mitral valve disease (MMVD). A. Shows a rounded dilated left atrium and ventricle in a dog with moderate MMVD. The mitral valve leaflets are thickened and bulges into the left atrium during systole. The echocardiograms in B. and C. show the same image without (B.) and with (C.) colour Doppler mode in a dog with mild to moderate MMVD. Slight bulging of the mitral valve leaflets during systole is evident in B. and a laterally directed mitral insufficiency jet is evident in C. LV, left ventricle; LA, left atrium.

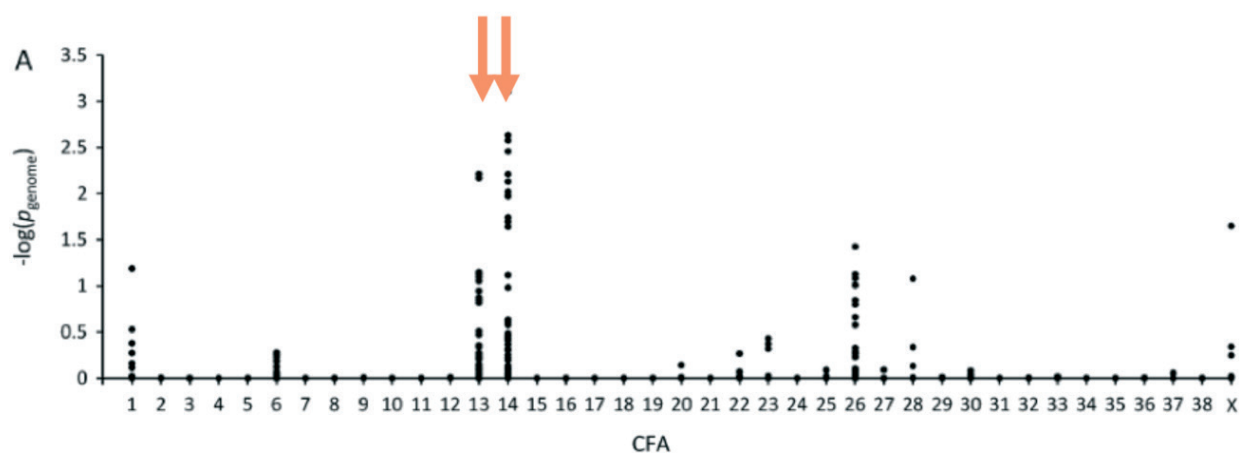


Fig. 3 Genome-wide association of single nucleotide polymorphism (SNP) markers to MMVD in CKCS. 139 dogs with an early onset of MMVD and 102 dogs with a late or no onset of MMVD reveals an association of MMVD to canine chromosome 13 ( $P_{\text{genome}} = 6.8 \times 10^{-3}$ ) and 14 ( $P_{\text{genome}} = 7.9 \times 10^{-4} - 2.3 \times 10^{-2}$ ) (arrows). From Madsen, Olsen, et al. 2011). Printed with permission from publisher.

male than in female dogs. [Haggstrom, Hansson et al. 1992, Swenson, Haggstrom et al. 1996, Olsen, Häggström et al. 2010, Lewis, Swift et al. 2011, Birkegaard, Reiman et al. 2013] Myxomatous mitral valve disease is chronic in nature with a progression spanning over years from very mild disease to severe symptomatic valve insufficiency. [Olsen, Häggström et al. 2010] Survival studies indicate that prognosis is dependent on stage of disease; dogs having secondary changes (cardiomegaly) in response to the valvular leakage but no clinical signs have been reported a median survival time of 33 months, whereas dogs having developed signs of CHF have a median survival time of 9 months. [Borgarelli, Savarino et al. 2008] These median survival times are slightly higher compared to those reported in clinical drug trials including dogs with MMVD. [Ettinger, Benitz et al. 1998, Atkins 2002, Kwart, Haggstrom et al. 2002, Haggstrom, Boswood et al. 2008]

In people, the mode of inheritance of MMVD has been suggested as autosomal dominant with age- and gender-dependent expression [Devereux, Brown et al. 1982] whereas others have suggested a polygenic mode of inheritance [Wilcken 1992] Because of the great differences in prevalence of MMVD between different dog breeds, MMVD in dogs has long been suspected to be influenced by genetic factors, but it was not until the mid 1990's this was shown in published studies. [Swenson, Haggstrom et al. 1996, Olsen, Fredholm et al. 1999] The major reason for this is that it is comparably difficult to study the inheritance of MMVD because dogs develop the disease at a comparably high age, which means that many dogs may have died or been euthanised for a reason other than heart disease. Furthermore, age has to be accounted for in the studies, because the prevalence of MMVD is strongly associated with age, even within a breed. Because most dogs will develop the disease with

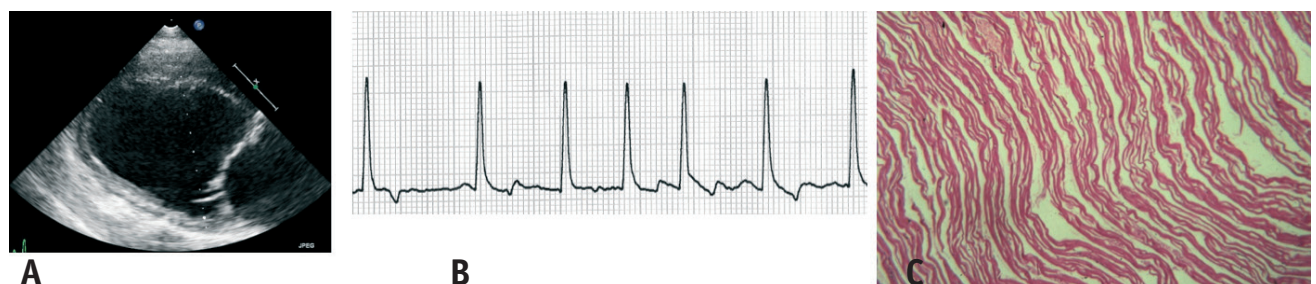advancing age and the disease is chronic and progressive, the difference between breeds with a high and a low prevalence is the age of onset of MMVD. A breed with a high prevalence typically develops the disease at a comparably young age, whereas a breed with a low prevalence has a late onset. Two studies, one including CKCSs and one including Dachshunds, have independently shown that the parental cardiac status influences the cardiac status in the offspring at a given age, and that the mode of inheritance is not consistent with a simple Mendelian inheritance.[Swenson, Haggstrom et al. 1996, Olsen, Fredholm et al. 1999] In fact, it has been suggested that the disease is inherited as a polygenetic threshold trait, where males have an earlier onset than females.[Swenson, Haggstrom et al. 1996, Olsen, Fredholm et al. 1999]

Recently, a genome-wide association study (GWAS) was published, where two loci, a 1.58 Mb region on canine chromosome (CFA)13 ( $p_{\text{genome}} = 4.0 \cdot 10^{-5}$ ) and a 1.68 Mb region on CFA14 ( $p_{\text{genome}} = 7.9 \cdot 10^{-4}$ ) associated with early onset of MMVD was described in CKCS (Fig.3.).[Madsen, Olsen et al. 2011] In this study, MMVD affected dogs were defined as dogs with CHF due to MMVD before 8 years of age or significant systolic heart murmur over the mitral area before 4.5 years of age. Unaffected dogs were defined as dogs with no or very mild heart murmur after 8 years of age. The associated genomic area is currently being investigated further for identifying causative mutations. Hopefully, these findings can potentially contribute to development of a DNA based test for identifying dogs at risk for early onset of MMVD, but no such test is yet available. Furthermore, it is not known if the associations found in the CKCS are present also present in other breeds.

Breed screening for MMVD is currently conducted in CKCSs in many countries. These screening programmes are based either on cardiac auscultation or echocardiography or a combination of both. These screening programmes are in most cases linked with a breeding programme, where dogs have to be free of the disease at a given age to be approved for breeding. Two studies have independently shown that this strategy has reduced the prevalence of MMVD in CKCS in Denmark and in the UK.[Lewis, Swift et al. 2011, Birkegaard, Reiman et al. 2013]

## Dilated cardiomyopathy

Dilated cardiomyopathy is defined as a primary myocardial disease characterised by cardiac enlargement and impaired systolic function in the absence of other cardiac or non-cardiac causes (Fig 4A.).[Richardson, McKenna et al. 1996] Dilated cardiomyopathy is prevalent in certain large to giant sized breeds of dogs and the disease contributes to a large proportion of the overall mortality in these breeds in dogs <10 years of age.[Martin, Stafford Johnson et al. 2010, Egenvall, Bonnett et al. 2000, Egenvall, Bonnett et al. 2000, Tidholm, Haggstrom et al. 2001, Bonnett, Egenvall et al. 2005] Population based European actuarial data showed that out of the 12 breeds with the highest cardiac mortality, 11 were breeds prone to develop DCM (Irish Wolfhound, Great Dane, St. Bernard, Newfoundland, Leonberger, Doberman Pinscher, Finnish Hound, Boxer, Giant Schnauzer, Cocker Spaniels). [Egenvall, Bonnett et al. 2006] The impact of DCM on mortality is striking in affected breeds; the mortality ranged from 3.6% per year at risk (Irish Wolfhound). [Egenvall, Bonnett et al. 2006] This cause specific mortality can only be matched by MMVD in CKCS (2.5% per year at risk). [Egenvall, Bonnett et al. 2006] Dilated



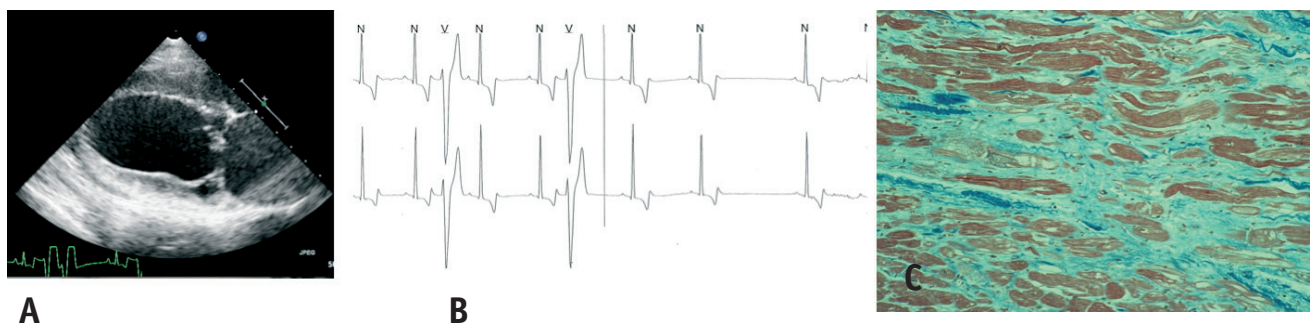
**Fig. 4** Two dimensional echocardiogram in the right parasternal long axis view from a dog with dilated cardiomyopathy (DCM) during systole (A.). The echocardiogram shows a rounded heart with dilatation of both the left atrium and ventricle. Dogs with dilated cardiomyopathy frequently present with atrial fibrillation, evident in the electrocardiogram in B. (lead II). Furthermore, DCM is associated with histopathological findings of attenuated wavy fibres (C.). The myocytes are thinner than normal and have a wavy appearance. The myocytes are separated by a clear space, indicating oedematous fluid that is generally free from cellular infiltrates. C. with courtesy of Professor Lennart Jönsson.

cardiomyopathy is most common in large breed dogs, but not all large breeds are affected. For instance German Shepherds and Labrador Retrievers had cardiac mortality comparable to the “average breed” in the European actuarial data. [Egenvall, Bonnett et al. 2006] Dilated cardiomyopathy is uncommon in small-bred dogs and findings indicative of DCM in such dogs should always be questioned. Because of the high incidence of DCM in affected breeds, there is a growing interest among breeders and pet owners to take actions to reduce the occurrence of DCM. Screening programs have been initiated in some breeds in several countries. These programs aim to identify affected dogs at an early stage and exclude them from breeding. The prognosis after diagnosis of symptomatic DCM is poor and the median survival time ranges between 27 to 140 days, [Monnet, Orton et al. 1995, Calvert, Pickus et al. 1997, Tidholm, Svensson et al. 1997, Ettinger, Benitz et al. 1998, 1999, Vollmar 2000, Tidholm, Haggstrom et al. 2001, Borgarelli, Santilli et al. 2006] but there are breed differences. For diagnostic, prognostic, therapeutic, and breeding purposes it is essential to detect the asymptomatic (preclinical) phase of the disease. For the pet owner with a dog with DCM, it is important that the clinician establish an accurate diagnosis to allow adequate therapy to improve the dogs’ quality of life and improve survival.

The clinical presentation may be subtle and include the gradual development of exercise intolerance and weight loss. However, more commonly, these early indications are overlooked and the diagnosis of DCM is not established until CHF develops and the patient is presented for coughing, dyspnoea, tachypnoea,

wasting, arrhythmia, syncope, and sometimes ascites. Indeed, increasing interest in screening families of dogs where DCM is prevalent has led to an appreciation that there is a very long phase of the disease that is not associated with clinical signs evident to the owner or veterinarian. [Calvert, Hall et al. 1997, Brownlie and Cobb 1999, Vollmar 2000, Tidholm, Haggstrom et al. 2001, Meurs 2005] Indeed, the phase with clinical signs, usually associated with the presence of CHF, is the final stage of several years of insidious progression. For the symptomatic patient, it is important for the clinician to rule out other possible causes for the clinical signs, such as pericardial effusion, pneumonia, neoplastic disease, undiscovered congenital heart disease. For the asymptomatic patient, the challenge lies in differentiating normal variation and other cardiac or non-cardiac pathologies from DCM.

Histopathological characterisation of dogs with DCM suggests that there are two phenotypes that presumably precipitate different clinical presentations. [Tidholm, Haggstrom et al. 2001] Most dogs with DCM present with systolic dysfunction and cardiac dilatation, often accompanied with an arrhythmia- most commonly atrial fibrillation (Fig.4B.). [Tidholm, Haggstrom et al. 2001] The histopathological findings commonly found in these dogs include thin myocytes with a wavy appearance that are separated by a clear space, indicating oedematous fluid that is generally free from cellular infiltrates (Fig. 4C.). There may also be diffuse infiltration of subendocardial fibrosis.[Tidholm, Haggstrom et al. 1998, Dambach, Lannon et al. 1999, Sleeper, Henthorn et al. 2002, Tidholm and Jonsson 2005] However, a proportion



**Fig. 5** Two-dimensional echocardiogram obtained in systole in the right parasternal long axis view from a Doberman Pinscher dog with the arrhythmic form of DCM. (A.). The echocardiogram shows only mild changes of rounding and dilatation of the left atrium and ventricle, but arrhythmia evident in the simultaneous ECG recording at the bottom of the image. Some (not all) Doberman Pinscher and Boxer dogs with DCM may present with ventricular arrhythmia, evident in the electrocardiogram in B. obtained from a 24-hour (Holter) recording. The arrhythmogenic presentation of DCM is associated with histopathological findings (C.) of fatty infiltration and degeneration (vacuolization and fragmentation) of the myocytes as well as proliferation of connective tissue. C. with courtesy of Professor Lennart Jönsson.



of Boxers and Doberman Pinschers (not all), present with ventricular tachyarrhythmias, causing fainting and weakness, but cardiac dilatation and systolic dysfunction are not apparent (Fig. 5A-B.). [Harpster 1983, Harpster 1991, Calvert, Hall et al. 1997, Calvert and Wall 2001, Tidholm, Haggstrom et al. 2001, Baumwart, Meurs et al. 2005, Meurs 2005]. These Doberman Pinschers and Boxers presenting with ventricular tachyarrhythmias often have myocardial lesions that include myocytolysis, myofibre degeneration, vacuolization and myocyte atrophy with extensive fibrosis and fatty infiltration (Fig. 5C). [Harpster 1983, Tidholm, Haggstrom et al. 2001, Tidholm and Jonsson 2005]

Although DCM is currently considered to be a genetic disease, [Meurs, Miller et al. 2001, Tidholm, Haggstrom et al. 2001, Dukes-McEwan, Borgarelli et al. 2003, Meurs 2005, Meurs, Fox et al. 2007] diagnosis is currently based on phenotypic characterisation. Because of the two histopathological phenotypes, dogs of different breeds are screened differently for preclinical disease. Most breeds are screened using echocardiography, [O'Grady and O'Sullivan 2004] whereas Doberman Pinschers and Boxers are also screened with 24-hour (Holter) recordings [Motskula, Linney et al. 2013, Palermo, Stafford Johnson et al. 2011, Stern, Meurs et al. 2010, Wess, Schulze et al. 2010, Wess, Schulze et al. 2010, Calvert, Hall et al. 1997, Calvert, Pickus et al. 1997] because a single ECG trace only corresponds to a small fraction of the dog's rhythm over a 24 hour period, and identification of intermittent abnormalities may be entirely fortuitous. Evidence of ventricular arrhythmia may precede echocardiographic evidence of DCM in the Doberman Pinscher by some months or even years. [Palermo, Stafford Johnson et al. 2011, Stern, Meurs et al. 2011, Wess, Schulze et al. 2010, Calvert, Hall et al. 1997] In Doberman Pinschers and Boxer dogs, therefore, Holter monitoring is of proven value in the identification of dogs destined to develop DCM and guidelines have been produced for these breeds for acceptable number of ventricular depolarizations over a 24 hour period. [Motskula, Linney et al. 2013, Wess, Schulze et al. 2010, Harpster 1991, Calvert 1995] The echocardiographic diagnosis of DCM is based on the identification of myocardial (predominantly but not solely) systolic dysfunction with the active exclusion of other acquired or congenital cardiac diseases. [Tidholm, Haggstrom et al. 2001, Dukes-McEwan, Borgarelli et al. 2003, Meurs 2005]

Dilated cardiomyopathy has been described to be inherited as an autosomal dominant trait in most breeds where it has been studied, the exceptions being Great Danes and Portuguese Water dogs (see below). [Meurs 1998, Meurs 2005] At present date, only two causative mutations have been suggested, one in Dobermann Pinschers and one in Boxer dogs (see below). [Meurs, Lahmers et al. 2012, Meurs, Mauceli et al. 2010.] However, genome wide association analyses have also been performed in Irish Wolfhounds, Newfoundlands and Great Dane dogs, and preliminary results of significant genome wide associations have been presented, [Philipp, Vollmar et al. 2008, Björnerfeldt, Höglund et al. 2011] but no candidate genes have yet been brought forward in these breeds. In people, mutations in the genes encoding the thick filament components myosin heavy chain and myosin binding protein C together explain 75% of inherited cases of hypertrophic cardiomyopathy (HCM) (which is a rare disease in dogs, but not in cats), which is suggestive that HCM is a disease of the sarcomere. [Lopes, Rahman et al. 2013] In contrast, DCM in people appears to be far more genetically heterogeneous, with mutations in genes encoding cytoskeletal, nucleoskeletal, mitochondrial, and calcium-handling proteins. [McNally, Golbus et al. 2013] Private mutations account for most DCMs, with few hotspots or recurring mutations. More than 50 single genes are linked to inherited DCM in people, [McNally, Golbus et al. 2013] including many genes that also link to HCM. There are still many human DCM forms, where the causative mutation remains unknown.

## Doberman Pinscher

The prevalence of DCM in Doberman Pinschers in the USA or Canada has been reported between 45 and 63%. [O'Grady and O'Sullivan 2004] A recent study from Europe showed a similar prevalence with 58% of the dogs being affected. [Wess, Schulze et al. 2010.] This European study showed that 37% of the dogs had only VPCs without echocardiographic changes and that arrhythmia often was the first abnormality detected. In this study, only a few dogs (13%) presented with only echocardiographic changes and no arrhythmias on Holter examination. Although there was no overall difference in the occurrence of DCM between male and female dogs, female dogs had significantly more VPCs without echocardiographic changes than male dogs and this difference became more apparent with increasing age. Male dogs developed earlier echocardiographic



changes than did female dogs. Older studies from the USA and elsewhere reported a higher prevalence of DCM in male dogs. [Calvert, Hall et al. 1997, Calvert, Pickus et al. 1997, O'Grady and O'Sullivan 2004] However, the study from Europe found an equal sex distribution, which supports the suspected autosomal dominant mode of inheritance [Wess, Schulze et al. 2010]. The different findings concerning the sex distribution may be explained by the results of the study that showed an equal sex distribution but different disease progression between male and female dogs. Female dogs seem to experience a more slowly progressive disease with VPCs as the only abnormality found even in the older age groups. [Wess, Schulze et al. 2010.] Diagnosis of DCM in Doberman Pinschers relies primarily on echocardiographic evaluation of left ventricular dimensions and function and evidence of ventricular arrhythmias, detected by Holter. Breed specific reference ranges have been established. [Wess, Maurer et al. 2010, Wess, Schulze et al. 2010, Wess, Schulze et al. 2010, Calvert, Jacobs et al. 2000, Calvert, Jacobs et al. 2000]. Newer tests, such as biomarkers or new echocardiographic methods, have recently been evaluated regarding their value in diagnosing DCM in Doberman Pinschers. [Simak, Keller et al. 2011, Singletary, Morris et al. 2012, Wess, Butz et al. 2011, Wess, Maurer et al. 2010, Wess, Simak et al. 2010]

Dilated cardiomyopathy in Doberman Pinschers has been suggested to be inherited as an autosomal dominant trait [Petric, Stabej et al. 2002, Meurs, Fox et al. 2007]. Several genes have been suggested causative for development of DCM in people, and some of these genes have been evaluated in Doberman Pinschers. So far 15 genes (ACTC1, CAV1, CSRP3, DES, LDB3, LMNA, MYH7, PLN, SGCD, TCAP, TNNC1, TNNI3, TNNT2, TPM1, VCL) have been studied, but none of them could be shown associated with DCM in Doberman Pinschers. [Meurs, Magnon et al. 2001, Stabej, Leegwater et al. 2005, Meurs, Hendrix et al. 2008, O'Sullivan, O'Grady et al. 2011] The results from a GWAS were recently published including Doberman Pinscher dogs from USA, where dogs had been classified according to echocardiography only. (Meurs, Lahmers et al. 2012) This study reported an area of significant association with DCM on chromosome 14, an area that turned out coding for the mitochondrial enzyme pyruvate dehydrogenase kinase 4 (PDK4). Specifically, a 16-base pair deletion in the 50-donor splice site of intron 10 of the pyruvate dehydrogenase kinase 4 gene was identified in affected dogs. This finding was coupled by abnormal

structure of mitochondria in affected dogs as evaluated by electron microscopy, again suggesting that mitochondrial function is important in the development of DCM in this breed. The mutation in the PDK4 gene was tested in a cohort of European dogs from Germany and the UK, but the association could not be replicated in this population of dogs [Owczarek-Lipska, Mausberg et al.]. This is suggestive of other causative genes in European dogs and/or geographic stratification of the breed. A genome-wide significant association to DCM was recently found in German Doberman Pinschers, classified according to both echocardiographic and 24-hour (Holter) findings) on chromosome 5 ( $p = 3.54 \times 10^{-8}$ ). [Mausberg, Wess et al. 2011]. The association was replicated in an independent cohort collected in the UK. There is no currently known DCM candidate gene under the association signal. Therefore, DCM in Doberman Pinschers offers the chance of identifying a novel DCM gene.

## Irish Wolfhounds

Dilated cardiomyopathy in the Irish Wolfhound represents the highest cardiac cause specific mortality in any breed in Swedish actuarial data. [Egenvall, Bonnett et al. 2006] Surprisingly, the highest cause specific mortality in Irish Wolfhounds is not DCM, but osteosarcoma. [Egenvall, Nodtvedt et al. 2007] Irish wolfhounds with DCM commonly present with arrhythmia (most commonly atrial fibrillation), dilated cardiac chambers, poorly contracting myocardium, and signs of CHF [Brownlie 1991, Vollmar 1998, Vollmar 2000]. Atrial fibrillation may precede the onset of signs of CHF over years [Brownlie 1991]. Echocardiographic reference values have been established for Irish wolfhounds, which is important for diagnosing of DCM in this breed [Vollmar 1999]. Irish Wolfhounds are currently screened for DCM using echocardiography. The prevalence of DCM in the breed has been reported as high as 41%, and the mean age of onset has been estimated to 4.5 years [Vollmar 2000], which should be compared to survival studies in the breed which reports of mean survival time of 6-9 years [Egenvall, Bonnett et al. 2006, Urfer, Gaillard et al. 2007]. Female dogs are less frequently affected and develop the disease at an higher age than males [Brownlie 1991, Vollmar 2000, Egenvall, Bonnett et al. 2006]. This suggests a protective effect in female Irish wolfhounds. A major gene model with sex-specific allele effects was the most plausible explanation for the inheritance of DCM in Irish wolfhounds whereas a monogenic mode of inheritance of DCM had been rejected

using complex segregation analysis [Distl, Vollmar et al. 2007]. The associations between several candidate genes and presence of DCM have been reported, and they include the tafazzin (TAZ), cardiac muscle actin alpha, (ACTC1), cysteine and glycine-rich protein 3 (CSRP3), desmin (DES), phospholamban (PLN), sarcoglycan delta (SGCD) and tropomodulin 1 (TMOD1). [Philipp, Brosch et al. 2007, Philipp, Vollmar et al. 2008, Philipp, Vollmar et al. 2008] None of these candidate genes could be associated with the presence of DCM in the breed. More recently, a genome wide association (GWAS) study was performed within the LUPA project to identify loci associated with DCM in Irish wolfhounds including 106 DCM cases and 84 controls [Philipp, Vollmar et al.]. Using a general linear model analysis with sex, inbreeding coefficient and the first three principal components as covariates, one single nucleotide polymorphism (SNP) was significantly associated with DCM on CFA37 and five SNPs suggestively associated with DCM on CFA1, 10, 15, 21 and 17 were identified. On CFA37, MOGAT1 and ACSL3, two enzymes of the lipid metabolism were located near the identified SNP [Philipp, Vollmar et al. 2008]. These genes are currently being sequenced in search for mutations causative for DCM in the breed.

## Great Dane

Great Danes (GD) are one of the most common breeds identified with DCM in retrospective analyses of case records [Martin, Stafford Johnson et al. 2010, Monnet, Orton et al. 1995, Borgarelli, Santilli et al. 2006]. In Swedish actuarial data, the GD has been reported the breed with the third highest cardiac cause specific mortality (after the Irish Wolfhound and Cavalier King Charles Spaniel) [Bonnett, Egenvall et al. 1997, Egenvall, Bonnett et al. 2006]. Despite this, there are few publications examining the prevalence, natural history, or inheritance and disease progression in this breed [Meurs, Miller et al. 2001, Tarducci, Borgarelli et al. 2003]. The prevalence of DCM in GD was recently reported as high as 36%, [Stephenson, Fonfara et al.] whereas others have reported lower prevalences ranging between 3.9-11% [Sisson and Thomas 1995, Tarducci, Borgarelli et al. 2003]. A report from the UK suggests that GDs have shorter median survival times than other breeds [Martin, Stafford Johnson et al.]. Dilated cardiomyopathy in Great Danes has been reported to present in a similar way to Irish Wolfhounds with cardiac dilatation and poor myocardial contractility with atrial fibrillation as the most

common arrhythmia, [Meurs, Miller et al. 2001, Tarducci, Borgarelli et al. 2003] although a recent report from the UK reported a high proportion dogs with ventricular arrhythmias [Stephenson, Fonfara et al. 2012]. Breed specific reference values for echocardiographic dimensions have been established, [Koch, Pedersen et al. 1996] and revised in a recent publication [Stephenson, Fonfara et al. 2012]. Great Dane dogs are currently screened by echocardiography. One study suggested that, although the mode of inheritance of DCM could not be definitively identified, it appeared to be inherited as an X-linked recessive trait [Meurs, Miller et al. 2001]. Another study suggested that DCM is inherited as an autosomal dominant inheritance trait [Stephenson, Fonfara et al. 2012]. The phospholamban gene has been evaluated as a candidate gene for DCM in the breed, but no association could be identified [Stabej, Leegwater et al. 2005]. The results from a genome-wide association study, conducted within the LUPA project, is currently under evaluation, but preliminary results are suggestive of multiple genomic regions associated with DCM in the breed [Björnerfeldt, Höglund et al. 2011].

## Boxer

The Boxer is a breed known to develop DCM, but the situation in this breed is more complicated from the diagnostic standpoint compared to other breeds. One reason is that Boxer dogs are predisposed to congenital aortic stenosis [Bussadori, Pradelli et al. 2009]. Furthermore, Boxer dogs may present with clinical findings of DCM similar to other breeds, such as atrial fibrillation and dilated hypocontracting hearts, with or without signs of CHF [Palermo, Stafford Johnson et al. 2011, Tidholm and Jonsson 1997]. However, a proportion of Boxer dogs may present with comparably unremarkable echocardiographic changes, but have episodes of ventricular arrhythmias, including ventricular tachycardia and/or ventricular premature depolarizations [Hariu and Carpenter 2010, Palermo, Stafford Johnson et al. 2011, Harpster 1983, Tidholm and Jonsson 1997, Basso, Fox et al. 2004]. Indeed, the number of ventricular depolarizations may be thousands on the 24-hour (Holter) ECG recording [Motskula, Linney et al. 2013, Stern, Meurs et al. 2010]. The ventricular arrhythmias may cause weakness, collapse or sudden death, but usually not CHF. Histopathology in dogs affected by ventricular arrhythmias frequently shows fatty or fibro-fatty replacement of the myocardium primarily in the

right ventricle but the changes may also reach the left ventricle [Harpster 1983, Basso, Fox et al. 2004, Tidholm and Jonsson 2005]. This form of cardiomyopathy was first reported by Harpster et al. in 1983 [Harpster 1983] and was called “Boxer cardiomyopathy”. However, the disease shares many features with a human form of cardiomyopathy called arrhythmogenic right ventricular cardiomyopathy (ARVC), [Basso, Fox et al. 2004] and this terminology is currently also used for the Boxer disease. It is currently not known, if, and, if so, how, the classical DCM form and the ARVC form are associated with each other. Both forms usually develop in adult dogs, but the mean age of presentation has been reported slightly lower for ARVC (median age 6 years) [Hariu and Carpenter 2010, Palermo, Stafford Johnson et al., Harpster 1983]. Furthermore, the survival times have been reported longer for dogs with ARVC compared to dogs with classical DCM [Palermo, Stafford Johnson et al. 2011]. Boxer dogs are currently screened for DCM by use of echocardiography and 24-hour (Holter) ECG. Breed specific normal reference ranges are available [Motskula, Linney et al. 2013]. The ARVC form has been extensively studied in reports emanating primarily from the USA, where it appears to be the predominant form of cardiomyopathy in the breed.[Basso, Fox et al. 2004, Baumwart, Meurs et al. 2005, Baumwart, Meurs et al. 2009] Reports and anecdotal evidence from Europe suggest a reversed situation on this continent, where the classical form appears more prevalent.[Palermo,

Stafford Johnson et al.2011] This suggests geographic genetic stratification within the breed.

The ARVC form has been reported to be familial and appears to be inherited as an autosomal dominant trait with reduced penetrance.[Meurs 1998, Meurs 2004] It appears to be a disease associated with abnormal intercellular contacts. When myocardium from ARVC dogs were compared to non-ARVC dogs reductions in the number of desmosomes adherens junctions and gap junctions were found.[Oxford, Danko et al.2011] Recently, a GWAS identified several regions of association, of which the strongest resided on chromosome 17. The associated locus corresponded to the Striatin gene on chromosome 17, and dogs with the mutation had a reduction in Striatin mRNA (Fig. 6) [Meurs, Mauceli et al. 2010]. Immunofluorescence studies localized Striatin to the intercalated disc region of the cardiac myocyte[Meurs, Mauceli et al. 2010]. Dogs that were homozygous for the deletion had a more severe form of disease based on a significantly higher number of ventricular premature complexes, but a proportion of dogs with ARVC did not have the mutation and vice versa. An attempt has been made to replicate the association between the Striatin mutation and ARVC in UK Boxer dogs, [Stephenson, Häggström et al. 2012] but failed to do so. The results showed that the Striatin mutation was very common in this population of UK Boxer [Stephenson, Häggström

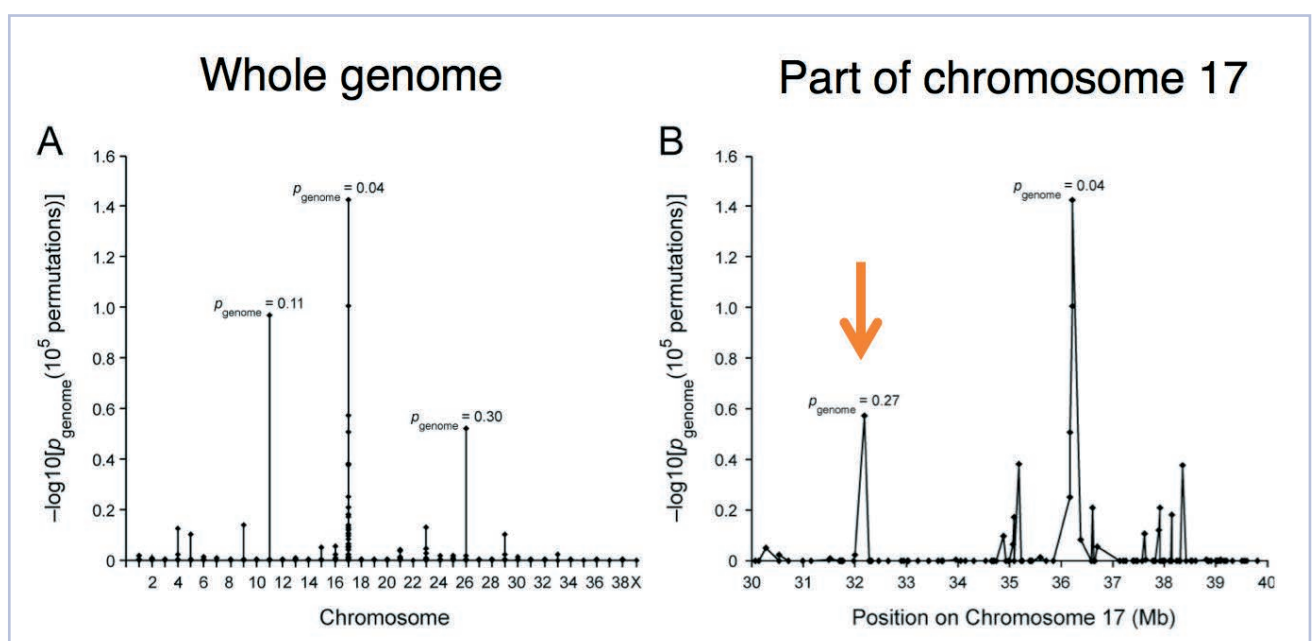


Fig. 6 Genome-wide association mapping of 300 Boxer dogs, 65 with the arrhythmogenic form of cardiomyopathy (ARVC). A 10 Mb region on canine chromosome 17 exhibited genome-wide significant association ( $p_{\text{genome}} < 0.04$ ) (A.). Close up of the chromosome 17 peaks (B.). The lower peak (arrow) in B. corresponds to area of the Striatin gene. From Meurs, Maucelli, et al. 2010). Printed with permission from publisher.

et al. 2012]. However, the proportion of dogs in the phenotypically normal and phenotypically affected dogs was not significantly different. Furthermore, in contrast to the Boxers from USA, the genotype was not correlated to the number of VPCs recorded over 24 hours in the UK population [Stephenson, Häggström et al. 2012]. These results suggest that Boxer ARVC appears to be influenced by more than one gene and/or geographic stratification of the breed.

### Cocker Spaniels and Portuguese water dogs

Cocker spaniels and Portuguese water dogs stand out as extreme breeds for developing DCM. Not only are they comparably small-sized breeds compared to other affected breeds. They also represent the extreme forms concerning breed-specific natural history of DCM. Dilated cardiomyopathy develops in young Portuguese water dogs, where affected dogs have been reported to die at 2-32 weeks of age, which has led to the disease being referred to as Juvenile DCM in this breed [Dambach, Lannon et al. 1999, Alroy, Rush et al. 2000, Sleeper, Henthorn et al. 2002]. Furthermore, the disease has a rapid progression with development of CHF or sudden death [Dambach, Lannon et al. 1999, Alroy, Rush et al. 2000, Sleeper, Henthorn et al. 2002]. To the contrary, DCM in Cocker Spaniels usually affects middle aged to old dogs, and affected dogs, even symptomatic dogs have been reported to have very long survival times, in comparison with other breeds, with median survival times of 82 weeks [Martin, Stafford Johnson et al. 2010, Fuentes, Corcoran et al. 2002]. Dilated cardiomyopathy is reported to be inherited as a autosomal recessive trait in Portuguese waterdogs, and the disease has been reported associated with a locus on chromosome 8 using GWAS [Dambach, Lannon et al. 1999, Werner, Raducha et al. 2008]. This genomic area is interesting because surrounding genes have been reported associated with different forms of human cardiomyopathy [Werner, Raducha et al. 2008]. Little is known concerning the

genetic background of DCM in Cocker Spaniels. Diagnosing DCM in Cocker spaniels is complicated by the fact that some dogs may have concurrent MMVD and dilated hypocontracting hearts and it is sometimes not possible to clinically distinguish if the dog suffers primarily from the valvular leakage or myocardial disease. Development of DCM in Cocker Spaniels has been suggested to be influenced by nutritional factors, specifically Taurine deficiency, and affected dogs have been reported to benefit from nutritional supplementation with Taurine/ Carnitine as indicated by improved cardiac performance [Kittleson, Keene et al. 1997]. Abnormal Taurine metabolism also has been suggested to play a role in the development of juvenile DCM in Portuguese water dogs [Alroy, Rush et al. 2000, Alroy, Rush et al. 2005].

### Conclusions

Myxomatous mitral valve disease and DCM are more prevalent in some breeds than others, but both contribute considerably to the overall morbidity and mortality in affected breeds. Myxomatous mitral valve disease appears to clinically present in a similar manner in predisposed breeds, but the difference between breeds is the age of onset. Dilated cardiomyopathy presents differently between different breeds, presumably owing to different disease progression and histopathological changes in the myocardium. The mode of inheritance for MMVD has been suggested as a polygenetic threshold trait, whereas DCM, with the exception of a few breeds, has been suggested inherited as an autosomal dominant trait. Associations between genomic regions and presence of disease have been described for both MMVD in CKCSs and for DCM in multiple breeds. However, causative mutations have, hitherto, only been suggested for DCM in Doberman Pinschers and in Boxer dogs. Several breed specific candidate genes are likely to be suggested in the near future. Hopefully, these findings can potentially contribute to development of DNA based testing identifying dogs at risk for developing MMVD or DCM.



## References

- Alroy, J., J. E. Rush, L. Freeman, M. S. Amarendhra Kumar, A. Karuri, K. Chase and S. Sarkar (2000). Inherited infantile dilated cardiomyopathy in dogs: genetic, clinical, biochemical, and morphologic findings. *Am J Med Genet* 95(1): 57-66.
- Alroy, J., J. E. Rush and S. Sarkar (2005). Infantile dilated cardiomyopathy in Portuguese water dogs: correlation of the autosomal recessive trait with low plasma taurine at infancy. *Amino Acids* 28(1): 51-56.
- Atkins, C. (2002). Enalapril monotherapy in asymptomatic mitral regurgitation: Results of the VetProof trial. ACVIM Forum, Dallas, Tx.
- Basso, C., P. R. Fox, K. M. Meurs, J. A. Towbin, A. W. Spier, F. Calabrese, B. J. Maron and G. Thiene (2004). Arrhythmogenic right ventricular cardiomyopathy causing sudden cardiac death in boxer dogs: a new animal model of human disease. *Circulation* 109(9): 1180-1185.
- Baumwart, R. D., K. M. Meurs, C. E. Atkins, J. D. Bonagura, T. C. DeFrancesco, B. W. Keene, S. Koplitz, V. Luis Fuentes, M. W. Miller, W. Rausch and A. W. Spier (2005). Clinical, echocardiographic, and electrocardiographic abnormalities in Boxers with cardiomyopathy and left ventricular systolic dysfunction: 48 cases (1985-2003). *J Am Vet Med Assoc* 226(7): 1102-1104.
- Baumwart, R. D., K. M. Meurs and S. V. Raman (2009). Magnetic resonance imaging of right ventricular morphology and function in boxer dogs with arrhythmogenic right ventricular cardiomyopathy. *J Vet Intern Med* 23(2): 271-274.
- The BENCH Study Group (1999). The effect of benazepril on survival times and clinical signs of dogs with congestive heart failure: Results of a multicenter double-blinded, placebo controlled, long-term clinical trial. *J Vet Cardiol* 1:7-17
- Birkegaard, A. C., M. J. Reiman, J. Häggström, T. Martinussen, H. D. Pedersen and L. H. Olsen (2013). Evaluation of the breeding program aiming at reducing the prevalence of myxomatous mitral valve disease in Cavalier King Charles Spaniels in Denmark. Annual ACVIM Forum, Seattle, WA.
- Björnerfeldt, S., K. Höglund, J. Meadows, A. Tidholm, J. Dukes-McEwan, H. Stephenson, K. Meurs, J. G. Kresken, M. Oyama, K. Lindblad-Toh, G. Andersson and J. Häggström (2011). Identifying genes predisposing Great Danes and Newfoundland dogs to dilated cardiomyopathy. European Human Genetics Conference. Amsterdam RAI, The Netherlands: (Abstract P09.083).
- Bonnett, B. N., A. Egenvall, A. Hedhammar and P. Olson (2005). Mortality in over 350,000 insured Swedish dogs from 1995-2000: I. Breed-, gender-, age- and cause-specific rates. *Acta Vet Scand* 46(3): 105-120.
- Bonnett, B. N., A. Egenvall, P. Olson and A. Hedhammar (1997). Mortality in insured Swedish dogs: rates and causes of death in various breeds. *Vet Rec* 141(2): 40-44.
- Borgarelli, M., R. A. Santilli, D. Chiavegato, G. D'Agnolo, R. Zanatta, A. Mannelli and A. Tarducci (2006). Prognostic indicators for dogs with dilated cardiomyopathy. *J Vet Intern Med* 20(1): 104-110.
- Borgarelli, M., P. Savarino, S. Crosara, R. A. Santilli, D. Chiavegato, M. Poggi, C. Bellino, G. La Rosa, R. Zanatta, J. Haggstrom and A. Tarducci (2008). Survival characteristics and prognostic variables of dogs with mitral regurgitation attributable to myxomatous valve disease. *J Vet Intern Med* 22(1): 120-128.
- Brownlie, S. E. (1991). An electrocardiographic survey of cardiac rhythm in Irish wolfhounds. *Vet Rec* 129(21): 470-471.
- Brownlie, S. E. and M. A. Cobb (1999). Observations on the development of congestive heart failure in Irish wolfhounds with dilated cardiomyopathy. *J Small Anim Pract* 40(8): 371-377.
- Buchanan, J. (1992). Causes and prevalence of cardiovascular disease. Kirk's current veterinary therapy XI. R. Kirk and J. Bonagura. Philadelphia, WB Saunders: 647-655.
- Bussadori, C., D. Pradelli, M. Borgarelli, D. Chiavegato, G. D'Agnolo, L. Menegazzo, F. Migliorini, R. Santilli, A. Zani and C. Quintavalla (2009). Congenital heart disease in boxer dogs: results of 6 years of breed screening. *Vet J* 181(2): 187-192.
- Calvert, C. (1995). Diagnosis and management of ventricular tachyarrhythmias in Doberman Pinschers with cardiomyopathy. Kirk's Current Veterinary Therapy. Small Animal Practise. J. Bonagura. Philadelphia, WB Saunders: 799-806.
- Calvert, C. A., G. Hall, G. Jacobs and C. Pickus (1997). Clinical and pathologic findings in Doberman pinschers with occult cardiomyopathy that died suddenly or developed congestive heart failure: 54 cases (1984-1991). *J Am Vet Med Assoc* 210(4): 505-511.
- Calvert, C. A., G. Jacobs, C. W. Pickus and D. D. Smith (2000). Results of ambulatory electrocardiography in overtly healthy Doberman Pinschers with echocardiographic abnormalities. *J Am Vet Med Assoc* 217(9): 1328-1332.

- Calvert, C. A., G. J. Jacobs, D. D. Smith, S. L. Rathbun and C. W. Pickus (2000). Association between results of ambulatory electrocardiography and development of cardiomyopathy during long-term follow-up of Doberman pinschers. *J Am Vet Med Assoc* 216(1): 34-39.
- Calvert, C. A., C. W. Pickus, G. J. Jacobs and J. Brown (1997). Signalment, survival, and prognostic factors in Doberman pinschers with end-stage cardiomyopathy. *J Vet Intern Med* 11(6): 323-326.
- Calvert, C. A. and M. Wall (2001). Results of ambulatory electrocardiography in overtly healthy Doberman Pinschers with equivocal echocardiographic evidence of dilated cardiomyopathy. *J Am Vet Med Assoc* 219(6): 782-784.
- Dambach, D. M., A. Lannon, M. M. Sleeper and J. Buchanan (1999). Familial dilated cardiomyopathy of young Portuguese water dogs. *J Vet Intern Med* 13(1): 65-71.
- Das, K. M. and R. J. Tashjian (1965). Chronic mitral valve disease in the dog. *Vet. Med./Small Anim. Clin.* 60: 1209-1215.
- Detweiler, D. K. and D. F. Patterson (1965). The prevalence and types of cardiovascular disease in dogs. *Ann. N. Y. Acad. Sci.* 127: 481-516.
- Devereux, R. B., W. T. Brown, R. Kramer-Fox and I. Sachs (1982). Inheritance of mitral valve prolapse: effect of age and sex on gene expression. *Ann Intern Med* 97: 826-832.
- Distl, O., A. C. Vollmar, C. Brosch, H. Hamann and P. R. Fox (2007). Complex segregation analysis of dilated cardiomyopathy (DCM) in Irish wolfhounds. *Heredity* 99(4): 460-465.
- Dukes-McEwan, J., M. Borgarelli, A. Tidholm, A. C. Vollmar and J. Haggstrom (2003). Proposed guidelines for the diagnosis of canine idiopathic dilated cardiomyopathy. *J Vet Cardiol* 5(2): 7-19.
- Egenvall, A., B. N. Bonnett and J. Haggstrom (2006). Heart disease as a cause of death in insured Swedish dogs younger than 10 years of age. *J Vet Intern Med* 20(4): 894-903.
- Egenvall, A., B. N. Bonnett, P. Olson and A. Hedhammar (2000). Gender, age, breed and distribution of morbidity and mortality in insured dogs in Sweden during 1995 and 1996. *Vet Rec* 146(18): 519-525.
- Egenvall, A., B. N. Bonnett, M. Shoukri, P. Olson, A. Hedhammar and I. Dohoo (2000). Age pattern of mortality in eight breeds of insured dogs in Sweden. *Prev Vet Med* 46(1): 1-14.
- Egenvall, A., A. Nodtvedt and H. von Euler (2007). Bone tumors in a population of 400 000 insured Swedish dogs up to 10 y of age: incidence and survival. *Can J Vet Res* 71(4): 292-299.
- Ettinger, S. J., A. M. Benitz, G. F. Ericsson, S. Cifelli, A. D. Jernigan, S. L. Longhofer, W. Trimboli and P. D. Hanson (1998). Effects of enalapril maleate on survival of dogs with naturally acquired heart failure. The Long-Term Investigation of Veterinary Enalapril (LIVE) Study Group. *J Am Vet Med Assoc* 213(11): 1573-1577.
- Fuentes, V. L., B. Corcoran, A. French, K. E. Schober, R. Kleemann and C. Justus (2002). A double-blind, randomized, placebo-controlled study of pimobendan in dogs with dilated cardiomyopathy. *J Vet Intern Med* 16(3): 255-261.
- Haggstrom, J., A. Boswood, M. O'Grady, O. Jons, S. Smith, S. Swift, M. Borgarelli, B. Gavaghan, J. G. Kresken, M. Patteson, B. Ablad, C. M. Bussadori, T. Glaus, A. Kovacevic, M. Rapp, R. A. Santilli, A. Tidholm, A. Eriksson, M. C. Belanger, M. Deinert, C. J. Little, C. Kvart, A. French, M. Ronn-Landbo, G. Wess, A. V. Eggertsdottir, M. L. O'Sullivan, M. Schneider, C. W. Lombard, J. Dukes-McEwan, R. Willis, A. Louvet and R. DiFrancia (2008). Effect of pimobendan or benazepril hydrochloride on survival times in dogs with congestive heart failure caused by naturally occurring myxomatous mitral valve disease: the QUEST study. *J Vet Intern Med* 22(5): 1124-1135.
- Haggstrom, J., K. Hansson, C. Kvart and L. Swenson (1992). Chronic valvular disease in the cavalier King Charles spaniel in Sweden. *Vet Rec* 131(24): 549-553.
- Hariu, C. D. and D. H. Carpenter, Jr. Arrhythmogenic right ventricular cardiomyopathy in boxers. *Compend Contin Educ Vet* 32(12): E3.
- Harpster, N. K. (1983). Current veterinary therapy VIII. R. Kirk. Philadelphia, WB Saunders: 329-337.
- Harpster, N. K. (1991). Boxer cardiomyopathy. A review of the long-term benefits of antiarrhythmic therapy. *Vet Clin North Am Small Anim Pract* 21(5): 989-1004.
- Hazlett, M. J., M. G. Maxie, D. G. Allen and B. P. Wilcock (1983). A retrospective study of heart disease in doberman pinscher dogs. *Can Vet J* 24(7): 205-210.
- Karlsson, E. K. and K. Lindblad-Toh (2008). Leader of the pack: gene mapping in dogs and other model organisms. *Nat Rev Genet* 9(9): 713-725.
- Kittleson, M. D., B. Keene, P. D. Pion and C. G. Loyer (1997). Results of the multicenter spaniel trial (MUST): taurine- and carnitine-responsive dilated cardiomyopathy in American cocker spaniels with decreased plasma taurine concentration. *J Vet Intern Med* 11(4): 204-211.

- Koch, J., H. D. Pedersen, A. L. Jensen and A. Flagstad (1996). M-mode echocardiographic diagnosis of dilated cardiomyopathy in giant breed dogs. *Zentralbl Veterinarmed A* 43(5): 297-304.
- Kvart, C., J. Haggstrom, H. D. Pedersen, K. Hansson, A. Eriksson, A. K. Jarvinen, A. Tidholm, K. Bsenko, E. Ahlgren, M. Ilves, B. Ablad, T. Falk, E. Bjerkfas, S. Gundler, P. Lord, G.
- Wegeland, E. Adolfsson and J. Corfitzen (2002). Efficacy of enalapril for prevention of congestive heart failure in dogs with myxomatous valve disease and asymptomatic mitral regurgitation. *J Vet Intern Med* 16(1): 80-88.
- Larson, G., E. K. Karlsson, A. Perri, M. T. Webster, S. Y. Ho, J. Peters, P. W. Stahl, P. J. Piper, F. Lingaas, M. Fredholm, K. E. Comstock, J. F. Modiano, C. Schelling, A. I. AgoulNIK, P. A. Leegwater, K. Dobney, J. D. Vigne, C. Vila, L. Andersson and K. Lindblad-Toh (2012). Rethinking dog domestication by integrating genetics, archeology, and biogeography. *Proc Natl Acad Sci U S A* 109(23): 8878-8883.
- Lequarre, A. S., L. Andersson, C. Andre, M. Fredholm, C. Hitte, T. Leeb, H. Lohi, K. Lindblad-Toh and M. Georges (2011). LUPA: a European initiative taking advantage of the canine genome architecture for unravelling complex disorders in both human and dogs. *Vet J* 189(2): 155-159.
- Lewis, T., S. Swift, J. A. Woolliams and S. Blott (2011). Heritability of premature mitral valve disease in Cavalier King Charles spaniels. *Vet J* 188(1): 73-76.
- Lopes, L. R., M. S. Rahman and P. M. Elliott (2013). A systematic review and meta-analysis of genotype-phenotype associations in patients with hypertrophic cardiomyopathy caused by sarcomeric protein mutations. *Heart*.
- Madsen, M. B., L. H. Olsen, J. Haggstrom, K. Hoglund, I. Ljungvall, T. Falk, G. Wess, H. Stephenson, J. Dukes-McEwan, V. Chetboul, V. Gouni, H. F. Proschowsky, S. Cirera, P. Karlskov-Mortensen and M. Fredholm (2011). Identification of 2 loci associated with development of myxomatous mitral valve disease in Cavalier King Charles Spaniels. *J Hered* 102 Suppl 1: S62-67.
- Martin, M. W., M. J. Stafford Johnson, G. Strehlau and J. N. King (2010) Canine dilated cardiomyopathy: a retrospective study of prognostic findings in 367 clinical cases. *J Small Anim Pract* 51(8): 428-436.
- Mausberg, T. B., G. Wess, J. Simak, L. Keller, M. Drogemuller, C. Drogemuller, M. T. Webster, H. Stephenson, J. Dukes-McEwan and T. Leeb (2011) A locus on chromosome 5 is associated with dilated cardiomyopathy in Doberman Pinschers. *PLoS One* 6(5): e20042.
- McNally, E. M., J. R. Golbus and M. J. Puckelwartz (2013). Genetic mutations and mechanisms in dilated cardiomyopathy. *J Clin Invest* 123(1): 19-26.
- Meurs, K. (2005). Primary myocardial disease in the dog. *Textbook of Veterinary Internal Medicine*. S. Ettinger and E. Feldman. Philadelphia, Elsevier Saunders: 1077-1082.
- Meurs, K. M. (1998). Insights into the heritability of canine cardiomyopathy. *Vet Clin North Am Small Anim Pract* 28(6): 1449-1457, viii.
- Meurs, K. M. (2004). Boxer dog cardiomyopathy: an update. *Vet Clin North Am Small Anim Pract* 34(5): 1235-1244, viii.
- Meurs, K. M., P. R. Fox, M. Norgard, A. W. Spier, A. Lamb, S. L. Koplitz and R. D. Baumwart (2007). A prospective genetic evaluation of familial dilated cardiomyopathy in the Doberman pinscher. *J Vet Intern Med* 21(5): 1016-1020.
- Meurs, K. M., K. P. Hendrix and M. M. Norgard (2008). Molecular evaluation of five cardiac genes in Doberman Pinschers with dilated cardiomyopathy. *Am J Vet Res* 69(8): 1050-1053.
- Meurs, K. M., S. Lahmers, B. W. Keene, S. N. White, M. A. Oyama, E. Mauceli and K. Lindblad-Toh (2012) A splice site mutation in a gene encoding for PDK4, a mitochondrial protein, is associated with the development of dilated cardiomyopathy in the Doberman pinscher. *Hum Genet* 131(8): 1319-1325.
- Meurs, K. M., A. L. Magnon, A. W. Spier, M. W. Miller, L. B. Lehmkuhl and J. A. Towbin (2001). Evaluation of the cardiac actin gene in Doberman Pinschers with dilated cardiomyopathy. *Am J Vet Res* 62(1): 33-36.
- Meurs, K. M., E. Mauceli, S. Lahmers, G. M. Acland, S. N. White and K. Lindblad-Toh (2010) Genome-wide association identifies a deletion in the 3' untranslated region of striatin in a canine model of arrhythmogenic right ventricular cardiomyopathy. *Hum Genet* 128(3): 315-324.
- Meurs, K. M., M. W. Miller and N. A. Wright (2001). Clinical features of dilated cardiomyopathy in Great Danes and results of a pedigree analysis: 17 cases (1990-2000). *J Am Vet Med Assoc* 218(5): 729-732.
- Monnet, E., E. C. Orton, M. Salman and J. Boon (1995). Idiopathic dilated cardiomyopathy in dogs: survival and prognostic indicators. *J Vet Intern Med* 9(1): 12-17.
- Motskula, P. F., C. Linney, V. Palermo, D. J. Connolly, A. French, J. Dukes-McEwan and V. Luis Fuentes Prognostic Value of 24-Hour Ambulatory ECG (Holter) Monitoring in Boxer Dogs. *J Vet Intern Med* 27(4): 904-912.

- O'Grady, M. R. and M. L. O'Sullivan (2004). Dilated cardiomyopathy: an update. *Vet Clin North Am Small Anim Pract* 34(5): 1187-1207.
- O'Sullivan, M. L., M. R. O'Grady, W. G. Pyle and J. F. Dawson (2011). Evaluation of 10 genes encoding cardiac proteins in Doberman Pinschers with dilated cardiomyopathy. *Am J Vet Res* 72(7): 932-939.
- Olsen, L., J. Häggström and H. Pedersen (2010). Acquired Valvular Heart Disease. *Textbook of Veterinary Internal Medicine. Diseases of Dogs and Cats*. S. Ettinger and E. Feldman. Philadelphia, Elsevier Saunders: 1209-1319.
- Olsen, L. H., M. Fredholm and H. D. Pedersen (1999). Epidemiology and inheritance of mitral valve prolapse in Dachshunds. *J Vet Intern Med* 13(5): 448-456.
- Owczarek-Lipska, M., T. B. Mausberg, H. Stephenson, J. Dukes-McEwan, G. Wess and T. Lee (2013). A 16-bp deletion in the canine PDK4 gene is not associated with dilated cardiomyopathy in a European cohort of Doberman Pinschers. *Anim Genet* 44(2): 239.
- Oxford, E. M., C. G. Danko, B. G. Kornreich, K. Maass, S. A. Hemsley, D. Raskolnikov, P. R. Fox, M. Delmar and N. S. Moise. Ultrastructural changes in cardiac myocytes from Boxer dogs with arrhythmogenic right ventricular cardiomyopathy. *J Vet Cardiol* 13(2): 101-113.
- Palermo, V., M. J. Stafford Johnson, E. Sala, P. G. Brambilla and M. W. Martin. Cardiomyopathy in Boxer dogs: a retrospective study of the clinical presentation, diagnostic findings and survival. *J Vet Cardiol* 13(1): 45-55.
- Pedersen, H. and J. Häggström (2000). Mitral valve prolapse in the dog: A model of mitral valve prolapse in man. *J Cardiovasc Res* 47: 234-243.
- Pedersen, H. D., B. O. Kristensen, K. A. Lorentzen, J. Koch, A. L. Jensen and A. Flagstad (1995). Mitral valve prolapse in 3-year-old healthy Cavalier King Charles Spaniels. An echocardiographic study. *Can J Vet Res* 59(4): 294-298.
- Petric, A. D., P. Stabej and A. Zemva (2002). Dilated cardiomyopathy in Doberman Pinschers: Survival, Causes of Death and a Pedigree Review in a Related Line. *J Vet Cardiol* 4(1): 17-24.
- Philipp, U., C. Broschk, A. Vollmar and O. Distl (2007). Evaluation of tafazzin as candidate for dilated cardiomyopathy in Irish wolfhounds. *J Hered* 98(5): 506-509.
- Philipp, U., A. Vollmar and O. Distl (2008). Evaluation of six candidate genes for dilated cardiomyopathy in Irish wolfhounds. *Anim Genet* 39(1): 88-89.
- Philipp, U., A. Vollmar and O. Distl (2008). Evaluation of the titin-cap gene (TCAP) as candidate for dilated cardiomyopathy in Irish wolfhounds. *Anim Biotechnol* 19(4): 231-236.
- Philipp, U., A. Vollmar, J. Haggstrom, A. Thomas and O. Distl. Multiple Loci are associated with dilated cardiomyopathy in Irish wolfhounds. *PLoS One* 7(6): e36691.
- Richardson, P., W. McKenna, M. Bristow, B. Maisch, B. Mautner, J. O'Connell, E. Olsen, G. Thiene, J. Goodwin, I. Gyafas, I. Martin and P. Nordet (1996). Report of the 1995 World Health Organization/International Society and Federation of Cardiology Task Force on the Definition and Classification of cardiomyopathies. *Circulation* 93: 841-842.
- Simak, J., L. Keller, M. Killich, K. Hartmann and G. Wess (2011). Color-coded longitudinal interventricular septal tissue velocity imaging, strain and strain rate in healthy Doberman Pinschers. *J Vet Cardiol* 13(1): 1-11.
- Singletery, G. E., N. A. Morris, M. Lynne O'Sullivan, S. G. Gordon and M. A. Oyama (2012). Prospective evaluation of NT-proBNP assay to detect occult dilated cardiomyopathy and predict survival in Doberman Pinschers. *J Vet Intern Med* 26(6): 1330-1336.
- Sisson, D. D. and W. P. Thomas (1995). Myocardial disease. *Textbook of Veterinary Internal Medicine*. S. J. Ettinger and E. C. Feldman. Philadelphia, WB Saunders: 995-1032.
- Sleeper, M. M., P. S. Henthorn, C. Vijayasarathy, D. M. Dambach, T. Bowers, P. Tijssens, C.
- F. Armstrong and E. B. Lankford (2002). Dilated cardiomyopathy in juvenile Portuguese Water Dogs. *J Vet Intern Med* 16(1): 52-62.
- Smucker, M. L., S. Kaul, J. A. Woodfield, J. C. Keith, S. A. Manning and J. A. Gascho (1990). Naturally occurring cardiomyopathy in the Doberman pinscher: a possible large animal model of human cardiomyopathy? *J Am Coll Cardiol* 16(1): 200-206.
- Stabej, P., P. A. Leegwater, A. A. Stokhof, A. Domanjko-Petric and B. A. van Oost (2005). Evaluation of the phospholamban gene in purebred large-breed dogs with dilated cardiomyopathy. *Am J Vet Res* 66(3): 432-436.
- Stephenson, H., J. Häggström, J. Meadows et al. (2012). Results from the Canine LUPA project (Cardiovascular workpackages). 22nd ECVIM-CA Congress, Maastricht, The Netherlands.
- Stephenson, H. M., S. Fonfara, J. Lopez-Alvarez, P. Cripps and J. Dukes-McEwan (2012). Screening for dilated cardiomyopathy in Great Danes in the United Kingdom. *J Vet Intern Med* 26(5): 1140-1147.



Stern, J. A., K. M. Meurs, A. W. Spier, S. L. Koplitz and R. D. Baumwart (2010) Ambulatory electrocardiographic evaluation of clinically normal adult Boxers. *J Am Vet Med Assoc* 236(4): 430-433.

Swenson, L., J. Haggstrom, C. Kvart and R. K. Juneja (1996). Relationship between parental cardiac status in Cavalier King Charles spaniels and prevalence and severity of chronic valvular disease in offspring. *J Am Vet Med Assoc* 208(12): 2009-2012.

Tarducci, A., M. Borgarelli, R. Zanatta and A. Cagnasso (2003). Asymptomatic dilated cardiomyopathy in Great Danes: clinical, electrocardiographic, echocardiographic and echo-Doppler features. *Vet Res Commun* 27 Suppl 1: 799-802.



## COMMISSIONED PAPER (UK)

## Chiari-like malformation and syringomyelia

Clare Rusbridge<sup>1,2</sup>

## INTRODUCTION

Syringomyelia is a condition characterised by fluid filled cavities (syrinxes or syringes) within the central spinal cord and the resulting damage produces clinical signs of pain and neurological deficits. Since the increase in availability of magnetic resonance imaging (MRI), syringomyelia is an increasingly common diagnosis in veterinary medicine <sup>[1, 2]</sup> The most common cause of syringomyelia in the dog is Chiari-like malformation (Fig 1), a condition analogous to Chiari Type I and O malformation in humans <sup>[3, 4]</sup>.

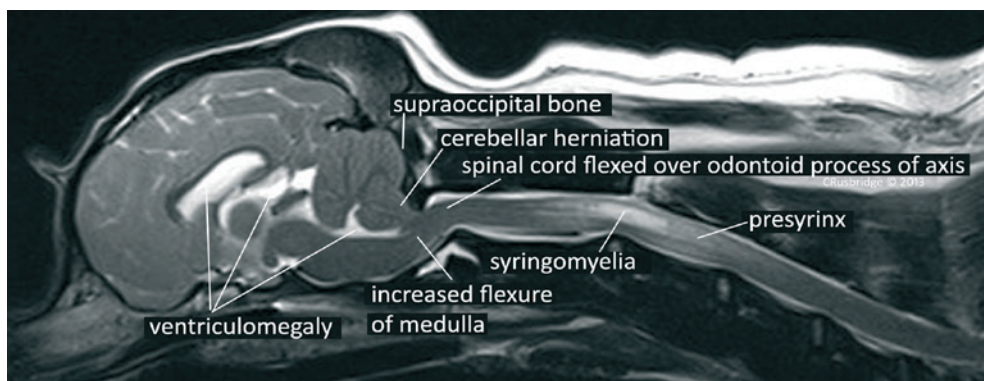
This paper was commissioned by FECAVA for The Special issue of EJCAP, Genetic/Hereditary Disease and Breeding.

## Pathophysiology of syringomyelia

A satisfactory explanation of how syringomyelia develops has yet to be elucidated. There is not even a consensus as to whether syrinx fluid is derived from extracellular or cerebrospinal fluid (CSF) <sup>[5-8]</sup>. Syringomyelia is a disorder of CSF and therefore understanding the pathogenesis of this enigmatic disorder is dependent on understanding CSF flow dynamics, biochemistry and factors that influence its absorption and production.

The majority of CSF is produced by the four choroid plexuses (one in each ventricle of the brain), which

circulates through the ventricular system and the subarachnoid spaces of the brain and spinal cord <sup>[9, 10]</sup>. Drainage of CSF is partly into the blood through arachnoid granulations and villi and partly along lymphatic drainage pathways, mostly associated with the cribriform plate of the ethmoid bone <sup>[11]</sup>. It has also been suggested that the spinal central canal may play a part in drainage of CSF and/or excess extracellular fluid as there is functional communication between the central canal and the subarachnoid space at the terminal ventricle <sup>[12, 13]</sup>. One of the major functions of CSF is as a mechanical buffer however it does not just provide a physical cushion and reduces tension on nerve roots but also accommodates the pressure of the systolic pulse and reduces the weight of this heavy organ. Without the CSF a human could not stand upright and within the CSF a 1500g brain weighs only 50g <sup>[14]</sup>.



**Figure 1**  
Midline sagittal T2-weighted MRI images of the brain and cervical spinal cord from 1 year old female CKCS with Chiari malformation and syringomyelia and presenting with pain.

1 Fitzpatrick Referrals, Halfway Lane, Eashing, Godalming, Surrey GB-GU7 2QQ

2 Reader in Veterinary Neurology, School of Veterinary Medicine, Faculty of Health & Medical Sciences, University of Surrey, Duke of Kent Building, University of Surrey, Guildford, Surrey, GB-GU2 7TE

According to the Munro-Kellie doctrine the central nervous system and its accompanying fluids are enclosed in a rigid container whose total volume remains constant. Therefore when the heart beats and there is increase in volume of intracranial blood, CSF is displaced from the cranial to the spinal subarachnoid space through the foramen magnum thus avoiding a deleterious increase in intracranial pressure. The spinal dural sac is distensible, further increasing the compliance of the system and minimising rises in central nervous system pressure<sup>[15]</sup>. Disturbance of the normal free flow of CSF through the foramen magnum appears to be a major factor responsible for the formation of a syrinx in the cervical spinal cord<sup>[2, 16, 17]</sup>. However there may be other possible factors influencing the pathogenesis of a syringomyelia such as failure of absorption or drainage of extracellular fluid<sup>[18]</sup>, intracranial hypertension<sup>[19-21]</sup>, imbalance in the production and absorption of CSF<sup>[22]</sup>, disruptions of the blood-spinal cord barrier or alterations of aquaporin expression<sup>[23]</sup>. The currently most accepted theory of pathogenesis of syringomyelia is that obstruction to CSF flow in the subarachnoid space results in a mismatch in timing between the arterial pulse peak pressure and CSF pulse peak pressure. Earlier arrival of peak CSF pressure compared to peak spinal arterial pressure encourages flow of CSF into the perivascular space. The perivascular space changes in size during the cardiac cycle and is widest when spinal arteriole pressure is low. If at that time peak CSF pressure is high then the perivascular space could act as a 'leaky' one-way valve<sup>[8, 24-27]</sup>. From the perivascular space, fluid flows into the central canal ultimately resulting in a syrinx<sup>[28-30]</sup>. However this theory also leaves many unanswered questions and further study is required.

In the dog syringomyelia is associated with a number of different pathologies with a common theme of CSF flow obstruction. The most common cause is Chiari-like malformation, which is a complex abnormality characterised by overcrowding of the craniocervical junction and obstruction of CSF flow through the foramen magnum. It is unclear why some dogs with Chiari-like malformation develop syringomyelia and some do not<sup>[31, 32]</sup>. Numerous studies, mostly in Cavalier King Charles spaniels (CKCS) and Griffon Bruxellois (Table 1) have identified many "pieces of the jigsaw" however key parts are still missing. No study has identified a single anatomical feature that consistently predicts syrinx development and it is likely that the pathogenesis of syringomyelia is a multifactorial process.

## Prevalence and incidence

### Chiari malformation

Brachycephalism and miniaturisation are risk factors for Chiari-like malformation<sup>[33]</sup>. The condition is most commonly reported in toy breed dogs, in particular CKCS, King Charles spaniels, Griffon Bruxellois, Affenpinschers, Yorkshire terriers, Maltese, Chihuahuas, Pomeranians, Boston terriers and Papillons<sup>[34]</sup>. Chiari-like malformation has also been recognised in cross-breed dogs particularly CKCS crosses. Partly because of its popularity as a pet, the CKCS is overrepresented and Chiari-like malformation is considered ubiquitous in this breed<sup>[1, 31, 35]</sup>. Up to 65% of the Griffon Bruxellois breed has Chiari-like malformation<sup>[21, 36]</sup>; data for other breeds is not available. Chiari-like malformation may also be seen in cats and is again more common in brachycephalic varieties such as the Persian. The incidence of symptomatic Chiari-like malformation is not known and is difficult to determine because the most common clinical sign is pain. Pain is a complex amalgamation of sensation, emotions and (in humans) thoughts and manifests itself as pain behaviour<sup>[37]</sup> which in a dog may not be recognised by owners or their veterinarians (Table 2). In addition pain associated with Chiari-like malformation is rarely constant or focal. In humans the key features of Chiari-related headaches are their relationship to any Valsalva-like manoeuvre, their brief duration - often lasting only seconds - and their posterior, suboccipital location<sup>[38]</sup>. In a dog this might manifest as a yelp on a rapid change of position, for example being picked up. It is difficult to attribute non-specific and brief signs to a specific aetiology especially when a condition is common in a breed and can be asymptomatic. The reported number of human patients with asymptomatic Chiari malformation type 1 varies between a third and a half of those diagnosed with the condition by MRI<sup>[39-43]</sup>.

### Syringomyelia

Due to the relationship with Chiari-like malformation, prevalence of syringomyelia is also high in brachycephalic toy-breeds<sup>[34]</sup>. Again not all animals with syringomyelia are symptomatic and like Chiari-like malformation it is difficult to obtain reliable incidence data. In humans the reported frequency of syringomyelia in people who have Chiari malformation type 1 ranges from 65 to 80%<sup>[44]</sup> and the frequency of asymptomatic syringomyelia has been

Table 1. Pathogenesis of Chiari-like malformation and syringomyelia: summary of the existing knowledge base.

Abbreviations used in tables: CKCS – Cavalier King Charles spaniel; SM – syringomyelia; CM – Chiari-like malformation; CCD – central canal dilatation.

Anatomical feature	Study Finding(s)	Significance relating to syringomyelia	Reference
Brachycephalicism	Brachiocephalic breeds have early closure of the spheno-occipital synchondrosis. In CKCS closure is even earlier	Premature closure of the spheno-occipital synchondrosis will result in a short cranial base predisposing brain overcrowding	[113, 114]
	CKCS have shorter braincase in relation to width compared to other brachycephalic dog breeds		[33]
	Griffon Bruxellois with CM have shortened basicranium and supraoccipital bone, with a compensatory lengthening of the cranial vault, especially the parietal bone	Basiscranial shortening results in compensatory changes in the rostral cranial fossa but caudal cranial fossa overcrowding persists	[21]
Caudal cranial fossa volume	CKCS with CM and SM have a shallower and smaller volume caudal cranial fossa compared to CKCS with CM only and other control breeds	Smaller caudal cranial fossa volume predisposes caudal cranial fossa overcrowding	[62, 115]
	CKCS have a strong relationship between hindbrain volume and volume of the rostral part of the caudal cranial fossa and a weak relationship between hindbrain volume and volume of the caudal part of the caudal cranial fossa. In Labrador retrievers and other small breed dogs this relationship is reversed.	Small breed dogs and Labrador retrievers compensate for variations in hindbrain volume by modifying growth of the occipital skull. In the CKCS, increased cerebellar size is not accommodated by increased occipital bone development and the tentorium cerebelli compensates by bulging in a rostral direction	[62, 116]
Parenchymal (brain) volume	The absolute and relative volume of the CKCS skull is similar to other brachycephalic toy dog breeds but CKCS have a greater volume of parenchyma within the caudal cranial fossa.	Mismatch in skull and brain volume is associated with development of SM.	[117]
	CKCS with early onset SM have a larger volume of parenchyma within a smaller caudal cranial fossa compared to older CKCS with CM only		[115, 118, 119]
Cerebellar volume	CKCS have relatively increased cerebellar volume compared to other control breeds and this is associated with development of SM.	Caudal cranial fossa overcrowding is associated with development of SM	[120]
	Increased cerebellar volume in CKCS is correlated with increased crowding of the cerebellum in the caudal part of the caudal cranial fossa		
Cerebellar herniation	Commonly seen but presence or size does not predict SM	Obstruction of CSF channels though the foramen magnum contributes to the pathogenesis of SM but there must also be other predisposing factors.	[31, 35]
	Positive association with the size of foramen magnum and size of cerebellar herniation	Overcrowding of the caudal cranial fossa causes supraoccipital bone resorption (occipital dysplasia)	[31]
	The length of the cerebellar herniation increases with time. The size of the foramen magnum also increases		[70, 121]
Cerebellar pulsation	CKCS with CM and SM have significantly greater pulsation of the cerebellum compared to CKCS with CM only and other control breeds	Abnormal cerebellar pulsation could lead to a mismatch in the timing of the arterial and CSF pulse waves predisposing to SM	[26, 27, 122]
CSF flow	Higher peak CSF flow velocity at the foramen magnum with a lower CSF flow velocity at C2–C3 predicts SM	Alterations in the CSF velocity profile predispose SM	[123]
	Turbulence at the foramen magnum and at the C2–C3 disc significantly associated with SM		



Table 1. Continued ...

Anatomical feature	Study Finding(s)	Significance relating to syringomyelia	Reference
Ventricle dimensions	In CKCS ventricle dimensions are positively correlated with syrinx width	SM is related to CSF disturbances	[115]
	Are not correlated with seizures (nor is caudal cranial fossa overcrowding)	Epilepsy and CM in CKCS should be considered unrelated	[50]
Jugular foramina	CKCS with CM and SM have narrowed jugular foramina in comparison with CKCS with CM only	Venous narrowing at the jugular foramina associated with small skull base can lead to elevated venous pressure and impaired CSF absorption	[21, 124]
Venous sinus volume	CKCS with CM and SM have reduced venous sinus volume in comparison with CKCS with CM only	Reduced venous sinus volume could result in intracranial hypertension and impaired CSF absorption	[119]
Site of syrinx	In CKCS, SM tends to develop first within the C2–C4, T2–T4 and T12–L2 spinal-cord segments. These are regions where the subarachnoid space narrows and/or there is a change in the angulation of the vertebral canal	According to the Venturi effect, increased fluid velocity through a narrowed flow channel decreases hydrostatic pressure in the fluid, meaning that there may be a tendency for the spinal cord to be “sucked” outward in these regions which may contribute towards SM. However other studies have suggested that the contribution of the Venturi effect is insignificant	[2, 27, 73]
	In CKCS, 76% of dogs with a syrinx at C1–C4 also had a syrinx in the C5–T1 and T2–L2 regions and 49% had a syrinx in the L3–L7 region	In CKCS MRI imaging of the cranial cervical region only has high sensitivity for detection of SM however the extent of the disease may be underestimated	[73]
Atlantoaxial subluxation	Occasional comorbidity with CM	No significant association with SM	[68]
Size of C2 spinous process	Significantly smaller in CKCSs than in non-CKCS breeds		
Atlanto-occipital overlapping	Commonly seen in association with CM especially in non-CKCS breeds (Fig 6)	Additional compression of CSF channels may contribute to development of SM but a consistent association has not been proven.	[34, 65]
Dorsal impingement subarachnoid space / spinal cord at C1–C2	Commonly seen in association with CM (Fig 7)		[31, 34, 62]
Ventral impingement of subarachnoid space / neural tissue by dens	Commonly seen in association with CM (Fig 1)		[31, 34, 62, 67]
Width of spinal canal	Increased width of spinal canal at C2–C3 and C3 in CKCS with SM	Questionable clinical significance	[125]
Angulation at C2–C3	No correlation		
Syrinx size and symmetry	Pain is positively correlated with SM transverse width and symmetry on the vertical axis,	Dogs with a wider asymmetrical SM more likely to experience discomfort	[54, 126]
	Positive correlation between maximum SM height (sagittal image) and clinical signs		[31]
	CKCS without clinical signs had symmetrical SM (on vertical axis). CKCS with pain may have symmetrical or asymmetrical SM.	A syndrome of neuropathic pain is more likely when there is asymmetrical dorsal horn involvement	[127]
	No significant difference between mean SM transverse width in CKCS with and without pain		
	Dogs with a wide syrinx and dorsal grey column damage are also more likely to have cervicothoracic scoliosis	Grey column damage can result in an imbalance of proprioceptive information and cervical dystonia	[54]

reported as being 23%<sup>[45]</sup>. Syringomyelia has a varying age of onset. There is 46% prevalence in (allegedly) asymptomatic breeding CKCS but prevalence (symptomatic and asymptomatic) increases with age and may be as high as 70% in dogs over six years of age<sup>[1]</sup>. In the Griffon Bruxellois 42- 52% of dogs have syringomyelia and this is not always in association with a classical Chiari-like malformation<sup>[21, 46]</sup>.

## Clinical signs

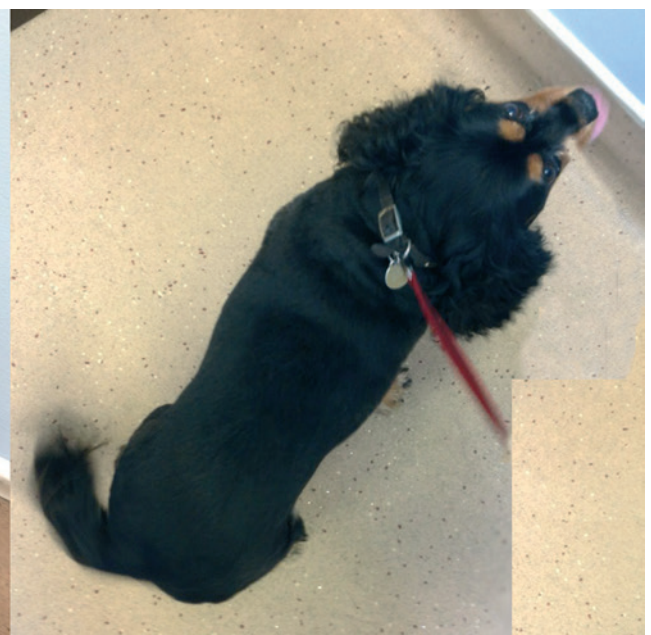
### Chiari like malformation

It is recognised increasingly that Chiari-like malformation alone can cause significant morbidity and reduced quality of life<sup>[47]</sup>. As with humans with Chiari type I malformation the most important clinical sign in affected dogs is behavioural signs of pain (Table 2). It is common for dogs with Chiari-like malformation to have exotropia (outward deviation of the eye) - typically a ventrolateral strabismus when gazing to the ipsilateral side (Fig 2). It is unclear whether this is oculomotor nerve/muscle palsy or related to orbit conformation. Some human craniosynostosis syndromes (premature fusion or abnormal development of one or more cranial sutures) with a high prevalence of Chiari malformation (for example Apert's and Crouzon's syndrome)<sup>[22]</sup> also have a high prevalence of strabismus<sup>[48]</sup>. Other neurological signs are detailed in Table 2. In



*Figure 2 It is common for dogs with Chiari – like malformation to have exotropia or outward deviation of the eye (in this case the right eye) when gazing to the ipsilateral side.*

some instances of neurological dysfunction it is difficult to be convinced of a true association with Chiari-like malformation. For example there is a high incidence of epilepsy in dogs with Chiari-like malformation, especially in CKCS. In one report, 32% of the study population had seizures<sup>[35]</sup> and in a long term study of 48 CKCS with syringomyelia associated neuropathic pain and where dogs with a history of seizures had been excluded from the original cohort, 12.5 % of the study population developed epilepsy in the follow up period<sup>[47]</sup>. Consequently it has been suggested that there may be an association between Chiari-like malformation and epilepsy



*Figure 3 A two year old female CKCS with cervicothoracic scoliosis and torticollis as a consequence of syringomyelia. The torticollis may be confused with a head tilt associated with vestibular dysfunction. This error of neurological localisation may result in a poor choice of diagnostic tests for example performing MRI of the brain and ears rather than the cervicothoracic spinal cord. It is thought that the abnormal posture is due to asymmetrical grey matter destruction by the expanding syrinx resulting in an imbalance of afferent proprioceptive information from the cervical neuromuscular spindles<sup>[54, 130]</sup>.*

Table 2 Clinical signs of Chiari-like malformation and syringomyelia

Clinical signs	CM	SM
Pain Behaviour		
Vocalisation	Owners may describe spontaneous vocalisation, especially when the dog stands up, jumps or when it is picked up. However the expression of pain by vocalisation is an unreliable sign as the absence of vocalisation is not a reliable indication that the dog is comfortable	
Withdrawn	Dogs with CM with or without SM may be described as “quiet” or “lazy” or may have decreased participation in activities such as playing and walking (Fig10)	
Avoidance of rapid changes in posture	It is common for dogs with CM with or without SM to avoid jumping, stairs and appear to dislike being picked up	
Reduced exercise	Signs may be exacerbated by excitement and exercise, it is thought because of increased systolic pulse pressure. Dogs with higher neuropathic pain score have decreased willingness to exercise <sup>[104]</sup>	
Scratching	Ear / back of skull scratching and/or rubbing	Dogs with a wide asymmetrical syrinx are more likely to have phantom scratching induced by excitement or from a non-noxious stimulus, such as touch or wearing a collar (Fig 5). Scratching is typically unilateral and to a small area on the neck and /or shoulder region. Often the dog does not make skin contact <sup>[55]</sup>
Fear / anxiety / excitability	Neuropathic pain has an important impact on an individual’s quality of life and neurobehaviour <sup>[28]</sup> . Dogs with higher neuropathic pain scores are more likely to have <sup>[104]</sup> 1) stranger-directed fear (act fearfully when approached by an unfamiliar person). 2) Non-social fear (act fearfully when in unfamiliar situations or when sudden loud noises occurred, e.g. thunderstorms). 3) Attachment behaviour (more ‘clingy’ to the owners) separation-related behaviour (more ‘afraid’ when left alone). 4) Excitability (increased attention-seeking behaviour and more excitable in positive, reward-associated situations).	
Sleep disturbance	Dogs with higher neuropathic pain score are more likely to have disturbed sleep <sup>[104]</sup> . Sleeping with the head in unusual positions may be reported (Fig 11)	
Other neurological signs		
Sensitivity	Dogs with symptomatic CM often appear to have sensitivity to palpation of the cervical and thoracolumbar spine	As with CM but dogs with spinal dorsal horn damage may have allodynia, i.e. signs of discomfort from a non-noxious stimulus, such as touch or grooming
Scoliosis	No	Dogs with a wide syrinx and dorsal grey column damage may have cervical torticollis and cervicothoracic scoliosis (Fig 3)
Gait abnormalities	CKCS with CM may have subtle gait abnormalities, relating to cerebellar or spinocerebellar tract dysfunction <sup>[129]</sup> .	Dogs with a wide syrinx may have thoracic limb weakness and muscle atrophy (due to ventral horn cell damage) and pelvic limb ataxia and weakness (due to white matter damage or involvement of the lumbar spinal cord by the syrinx) <sup>[2]</sup>
Exotropia	Common	Common (related to CM)

in the dog. An association has also been suggested in humans but again it is unclear whether the association is coincidental<sup>[49]</sup>. A recent study compared ventricle size and caudal cranial fossa overcrowding in CKCS with and without seizures and found no significant differences <sup>[50]</sup>. Electroencephalogram evaluation performed in three epileptic CKCS suggested paroxysmal abnormalities were mainly located over the frontal and temporal regions

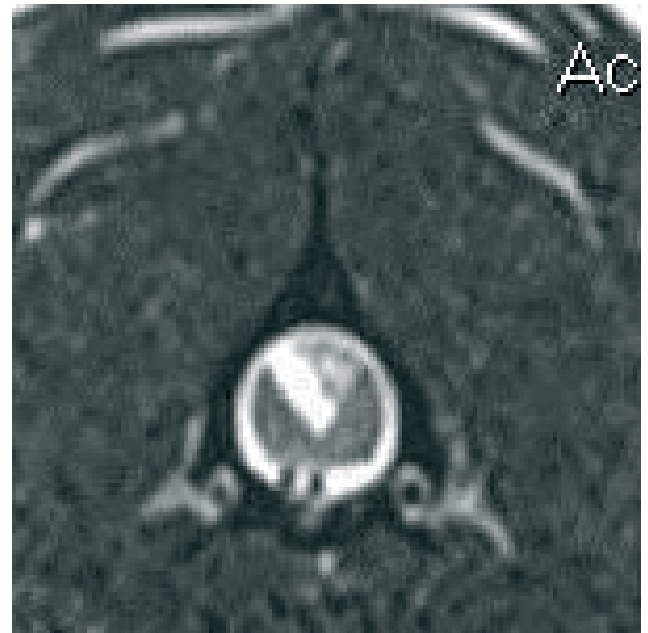
<sup>[50]</sup>. Similar changes have been reported in humans with seizures and Chiari type I malformation <sup>[51]</sup>. Further study is required to investigate if there is a connection between Chiari malformation and epilepsy. Vestibular dysfunction, facial nerve paralysis and deafness may also be seen but, as with epilepsy, no direct relationship has been proven and this association may also be circumstantial.



## Syringomyelia

Enlarging syrinxes cause progressive neurological damage through a combination of direct pressure on neural tissue, and ischemia. The location of functional impairment depends on the site of neuronal damage and may include scoliosis (Fig 3), gait abnormalities and other signs, which are detailed in Table 2. However the most important and consistent clinical sign of syringomyelia is neuropathic pain. Pain is positively correlated with syrinx transverse width and symmetry on the vertical axis, i.e. dogs with a wider asymmetrical syrinx are more likely to experience discomfort, and dogs with a narrow symmetrical syrinx may be asymptomatic. Pain is particularly associated with asymmetrical dorsal horn involvement especially when there is extension into the superficial lamina I and II (Fig 4) which receive primary afferents for nociception [52] and itch [53]. Axons from projection neurons with cell bodies in lamina I cross the midline and ascend in the contralateral white matter (for example the spinothalamic tracts) to brain stem and thalamic targets. Different types of excitatory and inhibitory interneurons selectively innervate these projection neurons. They are also influenced by descending serotonergic axons originating from the raphe nuclei [52]. It is hypothesised that disruption to the complex synaptic circuitry in the dorsal horn is primarily responsible for the development of neuropathic pain in syringomyelia [54, 55].

The pathogenesis of the phantom scratching (Fig 5) is not well understood. It has been presumed it is a response to allodynia (discomfort or pain from a non-noxious stimulus) and/or dysaesthesia (a spontaneous or evoked unpleasant sensation) and part of the neuropathic pain that these dogs appear to experience [54, 55]. However it is possible that damage to inhibitory neuron circuits has permitted overexpression of a hyperactive reflex. This may explain why mutilation is not a feature of the disease and why a minority of dogs with phantom scratching do not appear to suffer pain. The lack of purposeful contact with the skin and the rhythmic action is reminiscent of the “scratch reflex” described by Sherrington in 1906 [56]. He induced this in dogs that had undergone complete transection of the caudal cervical spinal cord. After approximately three months, stimulation of the skin in the scapular region induced a scratching action in the ipsilateral pelvic limb. The rhythmic action had a frequency of 4-8 times per



*Figure 4 Transverse T2 weighted MRI at the level of C2 from a CKCS presenting with scratching to the right cranial cervical region and signs of neuropathic pain. There is an asymmetrical syrinx involving the area of the right spinal cord dorsal horn and extending into the area of the superficial lamina I and II.*



*Figure 5 “Phantom scratching” in a CKCS. This is typically unilateral and to the neck and shoulder region. Here the scratching left hind limb can be seen as a movement blur. The dog does not make skin contact. This action can be elicited or exacerbated by excitement, exercise, touch and wearing of neck collars and harnesses. (Picture courtesy of Ms J Harrison, Passionate Productions.)*

second with the limb scratching towards but not making contact with the skin. Like dogs with syringomyelia there was a receptive field where stimulation of the skin induced ipsilateral pelvic limb action. Sherrington hypothesised that there was a spinal cord central pattern generator for scratching and that this had evolved as a protective response against clinging parasites and other irritants [56]. It is now well established that there are spinal cord central pattern generators for scratching [57]. Similar scratching action can be elicited in cats by the

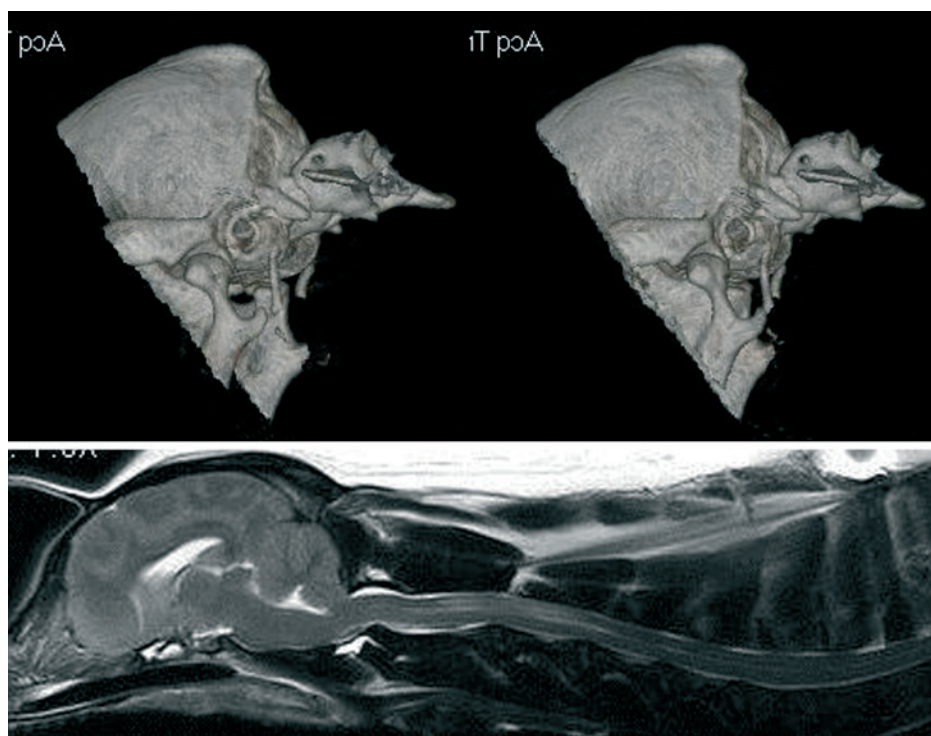


application of tubocurarine to the dorsal surface of the cervical cord at C1 (and to a lesser extent C2) with the scratch being elicited by rubbing the pinna and the skin behind the ear<sup>[58]</sup>. Tubocurarine blocks Renshaw cells - inhibitory interneurons found in the spinal cord ventral horn<sup>[59]</sup> that are rhythmically active during activity such as locomotion and scratching<sup>[60]</sup>, innervate motor neurons and receive inhibitory and excitatory synaptic inputs from commissural interneurons and from ipsilateral locomotor networks<sup>[61]</sup>. Hypothetically a syrinx, particularly in the C1/C2 region could lead to damage to these intricate networks resulting in a scratch reflex when the appropriate dermatome is tactily stimulated.

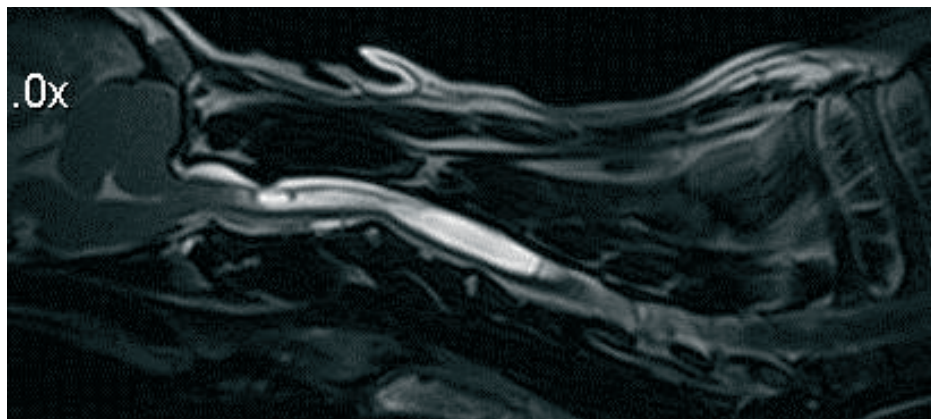
## Diagnosis

MRI is essential for diagnosis and determining the cause and extent of syringomyelia (Fig 1). Chiari-like malformation is a complex disorder and although there is less phenotypic variation than with humans, there can be differences between breeds and individuals within the same breed. In particular the conformation of the craniocervical junction varies. A consistent feature is hindbrain and sometimes forebrain overcrowding with narrowing or obstruction of the CSF channels. The caudal fossa is small and has a more horizontally orientated tentorium cerebelli<sup>[62, 63]</sup>. The medulla often has a kinked appearance<sup>[63]</sup>. The supraoccipital bone indents the cerebellum which loses its normal rounded shape<sup>[62, 63]</sup>. Dilatation of the entire ventricular

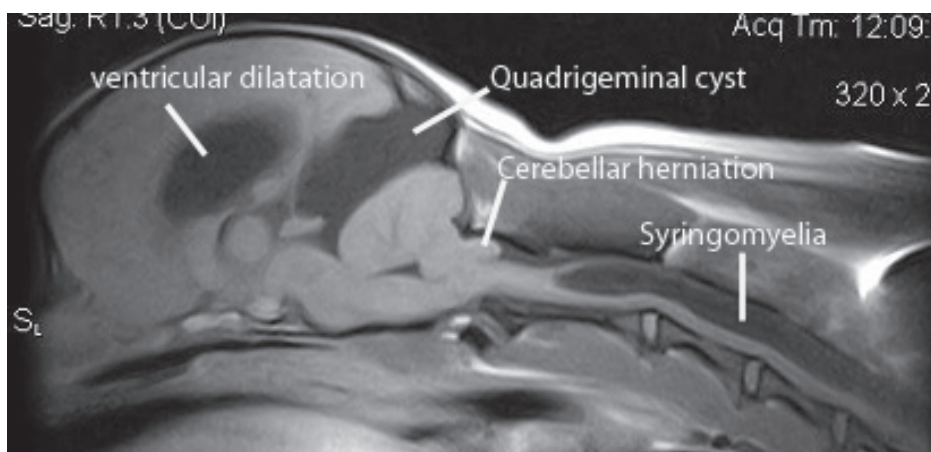
system secondary to cerebrospinal fluid obstruction is common<sup>[63]</sup>. In classical Chiari-like malformation the cerebellum and medulla extend into or through the foramen magnum, which is occluded with little or no CSF around the neural structures. However in some individuals the size of cerebellar herniation may be minimal<sup>[21]</sup>. A flexed head position increases the size of cerebellar herniation and is useful to determine the extent of disease<sup>[64]</sup>. However care is essential when obtaining these dynamic views in case there is concomitant atlanto-axial subluxation and/or airway obstruction. The most important craniovertebral junction abnormality associated with Chiari-like malformation is atlanto-occipital overlapping which has been reported as similar to basilar invagination in humans<sup>[34, 65]</sup> (Fig 6). Both conditions are characterized by increased proximity of the cranial cervical spine to the base of the skull;<sup>[66]</sup> however, a defining characteristic of basilar invagination is displacement of the odontoid process of the axis through the foramen magnum with compression of the medulla by the dens<sup>[66]</sup>. In the dog there may be flexure of the cranial cervical spinal cord over the odontoid process but this is more subtle than the human condition. (Fig 1)<sup>[31, 34, 62, 67]</sup>. Other less common canine craniovertebral junction anomalies include atlantoaxial subluxation<sup>[68, 69]</sup> and dorsal angulation of the dens<sup>[67]</sup>. Occipital dysplasia (i.e. widened foramen magnum) also may be seen;<sup>[70]</sup> however, this is probably an acquired condition due to overcrowding of the caudal cranial fossa, mechanical pressure from the cerebellum and



*Figure 6 Computer tomography (CT) of the caudal skull and atlas (top) and midline sagittal T2 weighted MRI of the brain and cervical spinal cord (bottom) of a 3.5 year old male CKCS presenting with pain. The MRI reveals Chiari-like malformation, ventriculomegaly with a mild syringomyelia and suggested atlanto-occipital overlapping. This was confirmed by CT. It can be seen that in the extended position the atlas is over riding the dorsal rim of the foramen magnum.*



*Figure 7 Midline 3D T2-weighted SPACE (sampling perfection with application optimized contrasts sequence with different flip angle evolutions) MRI of the caudal skull and cervical spinal cord. There is dorsal impingement of the spinal cord at C1-C2. The syringomyelia appears to start at the level of spinal cord impingement.*



*Figure 8 Midline sagittal T1-weighted MRI images of the brain and cervical spinal cord from 1 year old female Cavalier King Charles spaniels presenting with pain. There is a large quadrigeminal cyst in an already crowded caudal cranial fossa. There is a large hindbrain herniation and holochord syringomyelia.*

supraoccipital bone resorption<sup>[71]</sup>. It is also common to see dorsal impingement of the subarachnoid space and/or spinal cord at C1-C2 due to fibrosis and proliferation of the ligamentum flavum and dura<sup>[31, 34, 62]</sup> (Fig 7). Brachycephalic dogs are also predisposed to quadrigeminal cysts<sup>[72]</sup>. By occupying space within an already crowded caudal cranial fossa this may aggravate the obstruction at the foramen magnum and increase the likelihood of syringomyelia developing, although most quadrigeminal cysts are incidental findings (Fig 8). Syringomyelia is indicated by fluid-containing cavities within the cervical spinal cord. When evaluating the patient with syringomyelia then the spinal cord from C1-L4 should be imaged otherwise the extent of disease may be underestimated<sup>[73]</sup>. The cranial cervical and cranial thoracic segments are typically most severely affected. Maximum syrinx transverse width is the strongest predictor of pain, scratching behaviour and scoliosis<sup>[54]</sup>.

## Differential Diagnosis

The most important differential diagnoses are other causes of pain and spinal cord dysfunction such as intervertebral disc disease, central nervous system inflammatory diseases such as granulomatous meningoencephalomyelitis, vertebral abnormalities such as atlantoaxial subluxation,

neoplasia, and discospondylitis. Intervertebral disc disease would be a less likely cause of pain in a brachycephalic toy breed aged less than 4 years old. When scratching or facial/ear rubbing is the predominant clinical sign, ear and skin disease should be ruled out. The classic scratching behaviour for syringomyelia is to one distinct area. It is a common incidental finding for CKCS to have a mucoïd material in one or both tympanic bullae and in the majority of cases this is not associated with clinical signs of pain although it may cause hearing loss<sup>[35, 74]</sup>. Some cases with scoliosis appear to have a head tilt which could be confused with vestibular dysfunction<sup>[75]</sup> (Fig 3). CSF analysis may be abnormal in dogs with syringomyelia possibly due to syrinx induced cell damage and an inflammatory response in these dogs. A comparative study of CSF in CKCS with syringomyelia showed a higher protein and cell content, as compared to those with a Chiari-like malformation and no syrinx<sup>[76]</sup>.

## Treatment

### Surgical management

Medical and surgical treatment options exist for dogs with Chiari-like malformation with syringomyelia and a possible approach to management is illustrated in Fig 9.

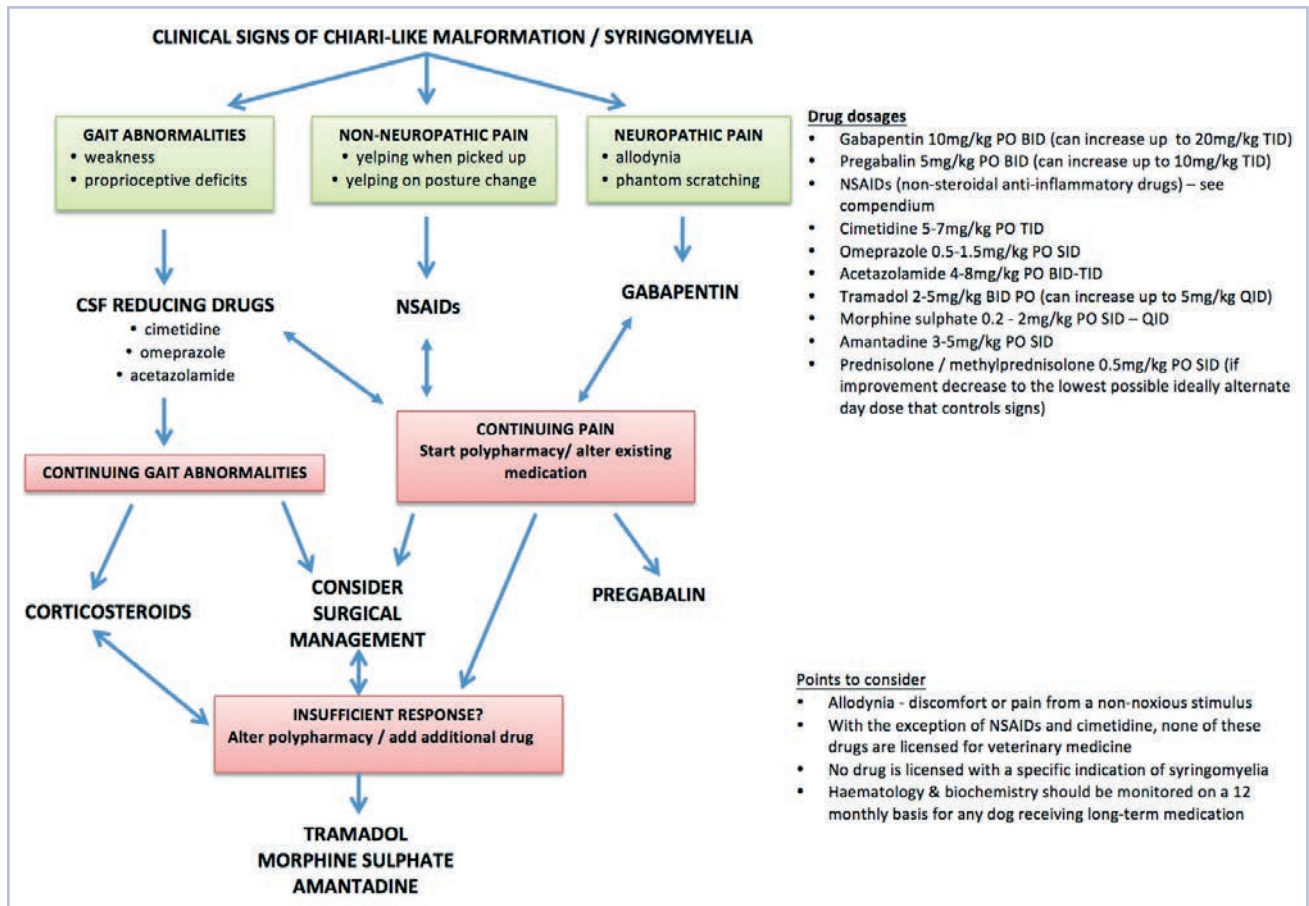


Figure 9 – Treatment algorithm for medical management of Chiari-like malformation and syringomyelia  
PO by mouth, SID once daily, BID twice daily, TID three times daily, QID four times daily

The main treatment objective is pain relief. There are no clear guidelines as to when surgery is indicated over medical management because robust outcome studies have not been performed. Some authors have suggested that early surgical intervention may improve prognosis but this hypothesis has not been vigorously tested<sup>[77]</sup>. The author is most likely to recommend surgery for painful dogs with Chiari-like malformation but without marked syringomyelia and/or dogs with syringomyelia where medical management does not give adequate pain relief. The reason why surgery has not been recommended universally is that no technique reported thus far has resulted in long term syrinx resolution<sup>[77-81]</sup>. In addition surgery does not necessarily improve long-term prognosis as 25-47% of the operated dogs have recurrence or deterioration of the clinical signs within 0.2-3 years of surgery<sup>[77-79]</sup>. However it should be remembered that it is probable that previous reports of surgically managed cases include dogs with more severe clinical signs so a valid comparison between medical and surgical management cannot be made at this time. The most common surgical management is craniocervical decompression, establishing a CSF pathway via the

removal of part of the supraoccipital bone and dorsal arch of C1<sup>[79, 80]</sup>. Depending on the surgeon this may be combined with a durotomy, with or without patching with a suitable graft material and with or without a cranioplasty, using titanium mesh or other prosthesis<sup>[77, 78]</sup>. Craniocervical decompression surgery is successful in reducing pain and improving neurological deficits in approximately 80% of cases and approximately 45% of cases may have a satisfactory quality of life two years postoperatively. The clinical improvement is probably attributable to improvement in CSF flow through the foramen magnum. A syringosubarachnoid shunting procedure using a five French equine ocular lavage catheter has also been described. Clinical improvement in approximately 80% of cases was reported but like other reported surgeries there was no evidence of long-term syrinx resolution on post-operative MRI and dogs still expressed signs of neuropathic pain post-operatively<sup>[81]</sup>.

## Medical management

Due to the persistence of syringomyelia and/or spinal cord dorsal horn damage it is likely that the post-



operative patient will require continuing medical management for pain relief. Also, in the majority of canine patients, medical management alone may be chosen for financial reasons or owner preference. There are three main type of drugs used for treatment of Chiari-like malformation with syringomyelia: drugs that reduce CSF production (acetazolamide, cimetidine, omeprazole or furosemide), analgesics (non-steroidal anti-inflammatory drugs and anti-epileptic drugs that have analgesic properties) and corticosteroids. As yet there are no scientific studies to prove the efficacy of these drugs in the management of neuropathic pain in dogs and recommended management is based on anecdotal evidence only (Fig 9).

### Drugs reducing cerebrospinal fluid production

The process of CSF production by the choroid plexus epithelial cells involves the enzymes carbonic anhydrase C, sodium and potassium ATPases, and aquaporin-1 and results in the net transport of water, sodium chloride, potassium and bicarbonate ions from the blood into the ventricles<sup>[82]</sup>. Acetazolamide reduces CSF production by inhibiting carbonic anhydrase C and by reducing the amount of aquaporin-1 through an alteration in protein transcription<sup>[83]</sup>. The use of acetazolamide for management of Chiari-like malformation and syringomyelia has been described<sup>[55, 63]</sup> and is also used in management of benign intracranial hypertension in humans<sup>[84]</sup>. However long term use of acetazolamide is often limited by adverse effects including lethargy, abdominal pain and bone marrow suppression<sup>[63]</sup>. Omeprazole is a specific inhibitor of H(+)-K(+)-activated ATPase however it is not clear if this is the mechanism by which it reduces CSF production<sup>[85]</sup>. In experimental models using a ventriculocisternal perfusion technique, omeprazole reduces canine CSF production by 26%<sup>(86)</sup>. Histamine (H<sub>2</sub>)-receptor antagonists such as cimetidine and ranitidine are proposed to reduce CSF production by competitive inhibition of H<sub>2</sub> receptors located on the choroid plexus epithelial cell or by a direct effect on the capillaries of the choroid plexus<sup>[87]</sup>. However there is also evidence that histamine may act physiologically by increasing the electrical activity of vasopressin-secreting neurons<sup>[88]</sup>. Vasopressin reduces blood flow to the choroid plexus thereby decreasing CSF production<sup>[89]</sup>. Cimetidine has been shown to be superior to ranitidine in reducing CSF production in an experimental cat model<sup>[87]</sup>. The usefulness of omeprazole or cimetidine for Chiari-like

malformation, with or without syringomyelia, is unclear. They are often prescribed in the hope that this may limit disease progression, a variable that is difficult to assess in a scientific study of clinical cases. Some owners report a significant improvement in clinical signs of pain. Adverse effects from these drugs are infrequently reported. Cimetidine retards P450 oxidative hepatic metabolism so caution is advised if using this preparation concurrently with other drugs metabolised by the liver and with both cimetidine and omeprazole, periodic monitoring of haematology and serum biochemistry is advised. Absorption of gabapentin may be reduced with concurrent cimetidine administration however the effect is thought to be clinically insignificant<sup>(90)</sup>. It has been suggested that chronic hypergastrinaemia, caused by omeprazole, may increase the risk of gastric carcinomas, at least in laboratory rodent models, but this has not been reported in any other species<sup>[91, 92]</sup>.

Use of the diuretic furosemide for management of Chiari-like malformation and syringomyelia has also been described<sup>[55, 63]</sup> and is also used in management of benign intracranial hypertension in humans<sup>[84]</sup>. Furosemide may not be ideal in toy breed dogs that also have a high likelihood of mitral valve disease<sup>[93]</sup> and where the most common cause of death is congestive heart failure<sup>[94]</sup>. Furosemide can result in significant increase in plasma aldosterone concentration and renin activity in healthy dogs<sup>[95]</sup>. This early activation of the renin-angiotensin-aldosterone system might be deleterious in an animal predisposed to heart disease<sup>[96]</sup>. Moreover, long-term use of diuretics can lead to a diuretic-resistant state which necessitates the use of higher doses, further activating the renin-angiotensin-aldosterone system<sup>[97]</sup>.

### Analgesics

NSAIDs are inhibitors of cyclooxygenase-1 and/or cyclooxygenase-2 and suppress inflammatory pain by reducing generation of prostanoids, in particular prostaglandin E<sub>2</sub>. Prostaglandin E<sub>2</sub> also contributes to the genesis of neuropathic pain<sup>[98]</sup>. Anecdotally, non-steroidal anti-inflammatory drugs (NSAIDs), e.g. meloxicam, carprofen, firocoxib, mavacoxib, can be useful in management of Chiari-like malformation and syringomyelia. However monotherapy with NSAIDs is unlikely to provide sufficient analgesia if there are signs of neuropathic pain. Therefore, in these situations, the addition of drugs with an anti-allodynic effect is



recommended<sup>[55]</sup>. All primary afferents in the spinal cord dorsal horn use glutamate as their main fast excitatory neurotransmitter. Nociceptive afferents are divided in two groups - those that contain neuropeptide (for example substance P and calcitonin gene related peptide) and those that do not<sup>[52]</sup>. Substance P containing primary afferents play an important part in nociception and neuropathic pain and have a high density in laminae I and II of the spinal cord dorsal horn<sup>[52]</sup>. Therefore drugs that affect the firing of these neurons are useful in the management of neuropathic pain. Gabapentin and pregabalin modulate voltage-gated calcium channels resulting in a reduction of glutamate and substance P<sup>[99]</sup>. Anecdotally, pregabalin is most efficacious for treating Chiari-like malformation and syringomyelia in dogs but gabapentin can also be useful and is more economic. In severe cases that still have clinical signs despite polypharmacy, the addition of opioids, tramadol or amantadine can be useful. It should be borne in mind that, with the exception of NSAIDs, there are no licensed oral analgesics in veterinary medicine.

## Corticosteroids

Corticosteroids are believed to provide long-term pain relief because of their ability to inhibit the production of phospholipase-A-2<sup>[100]</sup> and to inhibit the expression of multiple inflammatory genes coding for cytokines, enzymes, receptors and adhesion

molecules<sup>[101]</sup>. Corticosteroids are also reported to reduce sympathetically mediated pain<sup>[102]</sup> and decrease substance P expression<sup>[103]</sup>. Anecdotally, oral drugs such as methylprednisolone and prednisolone provide relief for some dogs with syringomyelia and can also be useful where there are significant neurological deficits but adverse effects limit their usefulness for long-term therapy<sup>[63]</sup>.

## Progression and prognosis

The clinical signs of Chiari-like malformation and syringomyelia are often progressive. A long term study over a mean of 39±14.3 months, found that approximately three-quarters of CKCS with Chiari-like malformation and syringomyelia associated neuropathic pain will deteriorate when managed medically whereas one quarter remain static or improved<sup>[47]</sup>. However, despite this progression, all the owners of the alive dogs in this study reported that their dog's quality of life was not severely compromised<sup>[47]</sup>. 15% of dogs were euthanased because of severe neuropathic pain. Morphometric values (volume of the caudal cranial fossa, parenchyma within the caudal cranial fossa, and the sizes of the ventricles and syrinxes) were not correlated with prognosis. Dogs with higher neuropathic pain scores are more likely to have fear-related behaviour (Table 2) which can have a negative impact on the owner-perceived quality of life of a dog<sup>[104]</sup>. Obesity is also positively

Table 3

### British Veterinary Association (BVA) / Kennel Club (KC) CMSM Scheme

Chiari-like malformation (CM):

Grade 0 - No Chiari malformation

Grade 1 - Cerebellum indented (not rounded)

Grade 2 - Cerebellum impacted into, or herniated through, the foramen magnum

Syringomyelia (SM)

Grade 0 - Normal (no central canal dilation, no presyrinx, no syrinx)

Grade 1 - Central canal dilation (Fig 12) or a separate syrinx, which has an internal diameter of less than 2mm or a pre-syrinx alone.

Grade 2 - Syringomyelia (central canal dilation which has an internal diameter of 2mm or greater, a separate syrinx, or pre-syrinx with central canal dilation).

The grade is qualified with a letter indicating the age group at the time of scanning as follows: a = more than five years of age; b = three to five years of age; c = one to three years of age. The grade is not valid without the qualifying letter.

Syringomyelia is defined as a fluid-filled cavity that includes, or is distinct from, the central canal of the spinal cord and is graded according to its maximum internal diameter in a transverse plane.

Pre-syrinx is defined as spinal cord oedema, and may be a transitional state prior to development of syringomyelia.

Pre-syrinx has the appearance of high signal intensity on T2W images consistent with marked increased fluid content within the spinal cord substance but not of free fluid. On T1W images the spinal cord is either normal or has a slightly hypointense signal



Figure 10 It is common for dogs with CM with or without SM to be described as “quiet” or to have decreased participation in activities. This syringomyelia affected dog’s depressed demeanour is apparent. In a veterinary consultation room there may be decreased interaction with the dog preferring to lay in sternal recumbency with their head on the floor.



Figure 11 Unusual sleeping positions. Left panel CKCS with Chiari malformation and syringomyelia that routinely slept with his head flexed and wedged behind a solid object. (Picture courtesy of Ms P Persson)  
Right panel CKCS with Chiari malformation and syringomyelia that preferred to sleep with her hindquarters lower than her head and with her head on a cooler surface. To achieve this, her head is on a wooden table and her hindquarters are balanced on a cushion and the back of a sofa. (Picture courtesy of Mrs S Smith)

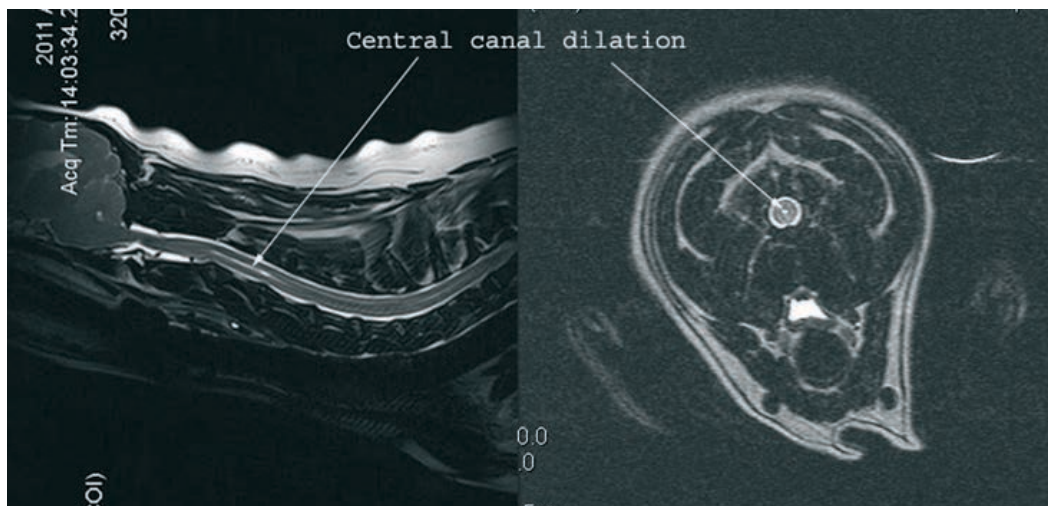


Figure 12 Midline sagittal T2 weighted MRI images from a 3 year old CKCS with Chiari-like malformation. A prominent central canal (arrow), or early syrinx, is seen particularly in the C2-C4 region. This dog was not reported to have any associated clinical signs. The MRI was performed with a view to assessment for breeding.

Table 4 Breeding guidelines (based on syringomyelia only)

			NORMAL			CCD			SM		
	AGE (years)	SM GRADE	0a	0b	0c	1a	1b	1c	2a*	2b*	2c
NORMAL	>5	0a	yes	yes	yes	yes	yes	yes	yes	yes	DO NOT BREED
	3-5	0b	yes	yes	yes	yes					
	1-3	0c	yes	yes		yes					
CCD	>5	1a	yes	yes	yes	yes	yes	yes	yes	yes	
	3-5	1b	yes			yes					
	1-3	1c	yes			yes					
SM	>5	2a*	yes			yes					
	3-5	2b*	yes			yes					
	1-3	2c	DO NOT BREED								
Dog with clinical signs CM &/ or SM			DO NOT BREED								

CM – Chiari malformation, SM – syringomyelia, CCD – central canal dilatation.

The aim of these breeding guidelines is to remove dogs with early onset SM from the breeding programme. Please note: it is believed that due to the complex nature of inheritance of CM/SM it is still possible that affected offspring may arise from parents which are clear from or are only mildly affected by SM.

No breeding guidelines for CM are available as yet. For toy breeds other than CKCS and King Charles, breeders should aim to breed from CM1 and CM0 dogs. For breeds with almost universal CM affectedness (i.e. CKCS, King Charles and possibly other breeds such as the Griffon Bruxellois) then the table above applies.

correlated with a reduced quality of life but not greater neuropathic pain<sup>[104]</sup>. In humans there is also a known association between increasing body mass index and CSF disorders such as idiopathic intracranial hypertension<sup>[105]</sup> and syringomyelia secondary to Chiari type 1 malformation<sup>[106]</sup>. It has not been established if obesity is the cause or effect of disease, however in humans reducing weight can reduce syrinx size after unsuccessful surgical decompression and reduction in body weight is recommended for all overweight and obese patients<sup>[106]</sup>.

## Genetic factors and breeding advice

The high prevalence, within closely related populations, suggests that syringomyelia is inherited in the dog and studies in the CKCS have shown it to be a complex trait with a moderately high heritability ( $h^2 = 0.37 \pm 0.15$  standard error)<sup>[107]</sup>. Since the early 2000s it has been

recommended that dogs of breeds predisposed to Chiari-like malformation and/or syringomyelia be MRI screened at least twice in their lifetime. Breeding recommendations based on syringomyelia status and ages were formulated in 2006. These guidelines concentrated on removing dogs with early onset syringomyelia from the breeding pool whilst maintaining genetic diversity<sup>[3]</sup>. Early results from this breeding program indicated that offspring without syringomyelia were more common when the parents were both clear of syringomyelia (offspring syringomyelia free; CKCS 70%, Griffon Bruxellois 73%). Conversely offspring with syringomyelia were more likely when both parents had syringomyelia (offspring syringomyelia affected; CKCS 92%, Griffon Bruxellois 100%). A mating of one syringomyelia-free parent with an syringomyelia-affected parent was risky for syringomyelia affectedness with 77% of CKCS and 46% of Griffon Bruxellois offspring being syringomyelia affected<sup>[108]</sup>.



In the UK there is a British Veterinary Association / Kennel Club Canine Health Scheme to MRI screen potential breeding stock for Chiari-like malformation and/or syringomyelia<sup>[109]</sup>. MRI images are assessed by two scrutineers and graded for severity for both Chiari-like malformation and syringomyelia and, as syringomyelia is a late onset condition, the age of onset (Table 3). Results are submitted to a central database, in order to generate estimated breeding values for the UK Kennel Club Mate Select Computer program<sup>[110]</sup>. As an accurate estimated breeding value database may take some time to compile, the recommended breeding guidelines have been revised<sup>[111]</sup> (Table 4). European health schemes for Chiari-like malformation and syringomyelia also exist<sup>[112]</sup>.

## Conclusion

Chiari-like malformation and syringomyelia is an inherited disorder with a high morbidity in many brachycephalic toy breeds. It is characterised by overcrowding of the craniocervical junction, obstruction of CSF flow through the foramen magnum and development of fluid filled cavities in the central spinal cord. Although some cases are asymptomatic, dogs with Chiari-like malformation and syringomyelia can present with neurological signs of which the most important is pain. Surgical and medical treatment options are available but these have limited success and from a welfare point of view it would be better to implement a breeding program limiting the occurrence of this disabling disease.

## Acknowledgements

The author thanks Penny Knowler for her valued assistance in preparation of many of the figures in this paper. Additional thanks to Taimur Alavi for his considerable help in preparation of Figure 9. Finally the author is grateful to Colin Driver for critically reading this manuscript and for his constructive comments.

## References

- [1] Parker JE, Knowler SP, Rusbridge C, Noorman E, Jeffery ND. Prevalence of asymptomatic syringomyelia in Cavalier King Charles spaniels. *The Veterinary Record*. 2011; 168(25): 667. Epub 2011/06/16.
- [2] Rusbridge C, Greitz D, Iskandar BJ. Syringomyelia: current concepts in pathogenesis, diagnosis, and treatment. *Journal of Veterinary Internal Medicine / American College of Veterinary Internal Medicine*. 2006; 20(3): 469-79. Epub 2006/06/01.
- [3] Cappello R, Rusbridge C. Report from the Chiari-Like Malformation and Syringomyelia Working Group Round Table. *Veterinary Surgery : VS*. 2007; 36(5): 509-12. Epub 2007/07/07.
- [4] Markunas CA, Tubbs RS, Moftakhar R, Ashley-Koch AE, Gregory SG, Oakes WJ, et al. Clinical, radiological, and genetic similarities between patients with Chiari Type I and Type O malformations. *Journal of Neurosurgery Pediatrics*. 2012; 9(4): 372-8. Epub 2012/04/03.
- [5] Greitz D. Unraveling the riddle of syringomyelia. *Neurosurgical Review*. 2006; 29(4): 251-63; discussion 64. Epub 2006/06/06.
- [6] Chang HS, Nakagawa H. Hypothesis on the pathophysiology of syringomyelia based on simulation of cerebrospinal fluid dynamics. *Journal of Neurology, Neurosurgery, and Psychiatry*. 2003; 74(3): 344-7. Epub 2003/02/18.
- [7] Stoodley MA, Gutschmidt B, Jones NR. Cerebrospinal fluid flow in an animal model of noncommunicating syringomyelia. *Neurosurgery*. 1999; 44(5): 1065-75; discussion 75-6. Epub 1999/05/08.
- [8] Stoodley MA. Pathophysiology of syringomyelia. *Journal of Neurosurgery*. 2000; 92(6): 1069-70; author reply 71-3. Epub 2000/06/06.
- [9] Gomez DG, Potts DG. The lateral, third, and fourth ventricle choroid plexus of the dog: a structural and ultrastructural study. *Annals of Neurology*. 1981; 10(4): 333-40. Epub 1981/10/01.
- [10] Bering EA, Jr. Choroid plexus and arterial pulsation of cerebrospinal fluid; demonstration of the choroid plexuses as a cerebrospinal fluid pump. *AMA Archives of Neurology and Psychiatry*. 1955; 73(2): 165-72. Epub 1955/02/01.
- [11] Johnston M, Zakharov A, Papaiconomou C, Salmasi G, Armstrong D. Evidence of connections between cerebrospinal fluid and nasal lymphatic vessels in humans, non-human primates and other mammalian species. *Cerebrospinal Fluid Research*. 2004; 1(1): 2. Epub 2005/02/01.
- [12] Storer KP, Toh J, Stoodley MA, Jones NR. The central canal of the human spinal cord: a computerised 3-D study. *Journal of Anatomy*. 1998; 192 ( Pt 4): 565-72. Epub 1998/09/02.



- [13] Radojicic M, Nistor G, Keirstead HS. Ascending central canal dilation and progressive ependymal disruption in a contusion model of rodent chronic spinal cord injury. *BMC Neurology*. 2007;7:30. Epub 2007/09/08.
- [14] Kimelberg HK. Water homeostasis in the brain: basic concepts. *Neuroscience*. 2004; 129(4): 851-60. Epub 2004/11/25.
- [15] Ambarki K, Baledent O, Kongolo G, Bouzerar R, Fall S, Meyer ME. A new lumped-parameter model of cerebrospinal hydrodynamics during the cardiac cycle in healthy volunteers. *IEEE Transactions on Bio-medical Engineering*. 2007; 54(3): 483-91. Epub 2007/03/16.
- [16] Heiss JD, Patronas N, DeVroom HL, Shawker T, Ennis R, Kammerer W, et al. Elucidating the pathophysiology of syringomyelia. *Journal of Neurosurgery*. 1999; 91(4): 553-62. Epub 1999/10/03.
- [17] Williams B. Experimental communicating syringomyelia in dogs after cisternal kaolin injection. Part 2. Pressure studies. *Journal of the Neurological Sciences*. 1980; 48(1): 109-22. Epub 1980/10/01.
- [18] Koyanagi I, Houkin K. Pathogenesis of syringomyelia associated with Chiari type 1 malformation: review of evidences and proposal of a new hypothesis. *Neurosurgical Review*. 2010; 33(3): 271-84; discussion 84-5. Epub 2010/06/10.
- [19] Moritani T, Aihara T, Oguma E, Makiyama Y, Nishimoto H, Smoker WR, et al. Magnetic resonance venography of achondroplasia: correlation of venous narrowing at the jugular foramen with hydrocephalus. *Clinical Imaging*. 2006; 30(3): 195-200. Epub 2006/04/25.
- [20] Levine DN. The pathogenesis of syringomyelia associated with lesions at the foramen magnum: a critical review of existing theories and proposal of a new hypothesis. *Journal of the Neurological Sciences*. 2004; 220(1-2): 3-21. Epub 2004/05/14.
- [21] Rusbridge C, Knowler SP, Pieterse L, McFadyen AK. Chiari-like malformation in the Griffon Bruxellois. *The Journal of Small Animal Practice*. 2009; 50(8): 386-93. Epub 2009/08/20.
- [22] Cinalli G, Spennato P, Sainte-Rose C, Arnaud E, Aliberti F, Brunelle F, et al. Chiari malformation in craniosynostosis. *Child's Nervous System: ChNS: Official journal of the International Society for Pediatric Neurosurgery*. 2005; 21(10): 889-901. Epub 2005/05/06.
- [23] Hemley SJ, Bilston LE, Cheng S, Stoodley MA. Aquaporin-4 expression and blood-spinal cord barrier permeability in canalicular syringomyelia. *Journal of Neurosurgery Spine*. 2012; 17(6): 602-12. Epub 2012/10/23.
- [24] Bilston LE, Fletcher DF, Brodbelt AR, Stoodley MA. Arterial pulsation-driven cerebrospinal fluid flow in the perivascular space: a computational model. *Computer Methods in Biomechanics and Biomedical Engineering*. 2003; 6(4): 235-41. Epub 2003/09/10.
- [25] Bilston LE, Stoodley MA, Fletcher DF. The influence of the relative timing of arterial and subarachnoid space pulse waves on spinal perivascular cerebrospinal fluid flow as a possible factor in syrinx development. *Journal of Neurosurgery*. 2010; 112(4): 808-13. Epub 2009/06/16.
- [26] Clarke EC, Stoodley MA, Bilston LE. Changes in temporal flow characteristics of CSF in Chiari malformation Type I with and without syringomyelia: implications for theory of syrinx development. *Journal of Neurosurgery*. 2013; 118(5): 1135-40. Epub 2013/03/19.
- [27] Clarke EC, Fletcher DF, Stoodley MA, Bilston LE. Computational fluid dynamics modelling of cerebrospinal fluid pressure in Chiari malformation and syringomyelia. *Journal of Biomechanics*. 2013. Epub 2013/06/19.
- [28] Rennels ML, Blaumanis OR, Grady PA. Rapid solute transport throughout the brain via paravascular fluid pathways. *Advances in Neurology*. 1990; 52: 431-9. Epub 1990/01/01.
- [29] Rennels ML, Gregory TF, Blaumanis OR, Fujimoto K, Grady PA. Evidence for a 'paravascular' fluid circulation in the mammalian central nervous system, provided by the rapid distribution of tracer protein throughout the brain from the subarachnoid space. *Brain Research*. 1985; 326(1): 47-63. Epub 1985/02/04.
- [30] Stoodley MA, Jones NR, Brown CJ. Evidence for rapid fluid flow from the subarachnoid space into the spinal cord central canal in the rat. *Brain Research*. 1996; 707(2): 155-64. Epub 1996/01/29.
- [31] Cerda-Gonzalez S, Olby NJ, McCullough S, Pease AP, Broadstone R, Osborne JA. Morphology of the caudal fossa in Cavalier King Charles Spaniels. *Veterinary Radiology & Ultrasound: the official journal of the American College of Veterinary Radiology and the International Veterinary Radiology Association*. 2009; 50(1): 37-46. Epub 2009/02/27.
- [32] Rusbridge C, Knowler SP. Inheritance of occipital bone hypoplasia (Chiari type I malformation) in Cavalier King Charles Spaniels. *Journal of Veterinary Internal Medicine / American College of Veterinary Internal Medicine*. 2004; 18(5): 673-8. Epub 2004/11/02.
- [33] Schmidt MJ, Neumann AC, Amort KH, Failing K, Kramer M. Cephalometric measurements and determination of general skull type of Cavalier King Charles Spaniels. *Veterinary Radiology & Ultrasound: the official journal of the American College of Veterinary Radiology and the International Veterinary Radiology Association*. 2011; 52(4): 436-40. Epub 2011/04/28.
- [34] Marino DJ, Loughin CA, Dewey CW, Marino LJ, Sackman JJ, Lesser ML, et al. Morphometric features of the craniocervical junction region in dogs with suspected Chiari-like malformation determined by combined use of magnetic resonance imaging and computed tomography.

- American Journal of Veterinary Research. 2012; 73(1): 105-11. Epub 2011/12/30.
- [35] Lu D, Lamb CR, Pfeiffer DU, Targett MP. Neurological signs and results of magnetic resonance imaging in 40 cavalier King Charles spaniels with Chiari type 1-like malformations. *The Veterinary Record*. 2003; 153(9): 260-3. Epub 2003/09/17.
- [36] Freedman D. Preliminary morphometric evaluation of syringomyelia in American Brussels Griffon dogs. *Journal of Veterinary Internal Medicine*. 2011; 25(3).
- [37] Tripp DA, Nickel JC. Psychosocial aspects of chronic pelvic pain. *International Association for the Study of Pain: Pain Clinical Updates* 2013; XXI(1): 1-7.
- [38] Mueller DM, Oro JJ. Prospective analysis of presenting symptoms among 265 patients with radiographic evidence of Chiari malformation type I with or without syringomyelia. *Journal of the American Academy of Nurse Practitioners*. 2004; 16(3): 134-8. Epub 2004/05/08.
- [39] Benglis D, Jr., Covington D, Bhatia R, Bhatia S, Elhammady MS, Ragheb J, et al. Outcomes in pediatric patients with Chiari malformation Type I followed up without surgery. *Journal of Neurosurgery Pediatrics*. 2011; 7(4): 375-9. Epub 2011/04/05.
- [40] Elster AD, Chen MY. Chiari I malformations: clinical and radiologic reappraisal. *Radiology*. 1992; 183(2): 347-53. Epub 1992/05/01.
- [41] Meadows J, Kraut M, Guarnieri M, Haroun RI, Carson BS. Asymptomatic Chiari Type I malformations identified on magnetic resonance imaging. *Journal of Neurosurgery*. 2000; 92(6): 920-6. Epub 2000/06/06.
- [42] Novegno F, Caldarelli M, Massa A, Chieffo D, Massimi L, Pettorini B, et al. The natural history of the Chiari Type I anomaly. *Journal of Neurosurgery Pediatrics*. 2008; 2(3): 179-87. Epub 2008/09/02.
- [43] Wu YW, Chin CT, Chan KM, Barkovich AJ, Ferriero DM. Pediatric Chiari I malformations: do clinical and radiologic features correlate? *Neurology*. 1999; 53(6): 1271-6. Epub 1999/10/16.
- [44] Speer MC, George TM, Enterline DS, Franklin A, Wolpert CM, Milhorat TH. A genetic hypothesis for Chiari I malformation with or without syringomyelia. *Neurosurgical Focus*. 2000; 8(3): E12. Epub 2006/05/09.
- [45] Sakushima K, Tsuboi S, Yabe I, Hida K, Terae S, Uehara R, et al. Nationwide survey on the epidemiology of syringomyelia in Japan. *Journal of the Neurological Sciences*. 2012; 313(1-2): 147-52. Epub 2011/09/29.
- [46] Knowler SP, McFadyen AK, Rusbridge C. Effectiveness of breeding guidelines for reducing the prevalence of syringomyelia. *Veterinary Record*. 2011; 169(26): 681-.
- [47] Plessas IN, Rusbridge C, Driver CJ, Chandler KE, Craig A, McGonnell IM, et al. Long-term outcome of Cavalier King Charles spaniel dogs with clinical signs associated with Chiari-like malformation and syringomyelia. *The Veterinary Record*. 2012. Epub 2012/10/27.
- [48] Lehman S. Strabismus in craniosynostosis. *Current Opinion in Ophthalmology*. 2006; 17(5): 432-4. Epub 2006/08/26.
- [49] Granata T, Valentini LG. Epilepsy in type 1 Chiari malformation. *Neurological Sciences : official journal of the Italian Neurological Society and of the Italian Society of Clinical Neurophysiology*. 2011; 32 Suppl 3: S303-6. Epub 2011/07/29.
- [50] Driver CJ, Chandler K, Walmsley G, Shihab N, Volk HA. The association between Chiari-like malformation, ventriculomegaly and seizures in Cavalier King Charles spaniels. *Vet J*. 2012. Epub 2012/07/04.
- [51] Elia M, Biondi R, Sofia V, Musumeci SA, Ferri R, Capovilla G, et al. Seizures in Chiari I malformation: a clinical and electroencephalographic study. *Journal of Child Neurology*. 1999; 14(7): 446-50. Epub 1999/11/26.
- [52] Todd AJ, editor. *Neuronal circuits and receptors involved in spinal cord pain processing* Seattle: ISAP Press 2009.
- [53] Ross SE, Mardinly AR, McCord AE, Zurawski J, Cohen S, Jung C, et al. Loss of inhibitory interneurons in the dorsal spinal cord and elevated itch in Bhlhb5 mutant mice. *Neuron*. 2010; 65(6): 886-98. Epub 2010/03/30.
- [54] Rusbridge C, Carruthers H, Dube MP, Holmes M, Jeffery ND. Syringomyelia in Cavalier King Charles spaniels: the relationship between syrinx dimensions and pain. *The Journal of Small Animal Practice*. 2007; 48(8): 432-6. Epub 2007/07/05.
- [55] Rusbridge C, Jeffery ND. Pathophysiology and treatment of neuropathic pain associated with syringomyelia. *Vet J*. 2008; 175(2): 164-72. Epub 2007/02/24.
- [56] Sherrington CS. Observations on the scratch-reflex in the spinal dog. *The Journal of Physiology*. 1906; 34(1-2): 1-50. Epub 1906/03/13.
- [57] Frigon A. Central pattern generators of the mammalian spinal cord. *The Neuroscientist : a review journal bringing neurobiology, neurology and psychiatry*. 2012; 18(1): 56-69. Epub 2011/04/27.
- [58] Dömer FR, Feldberg W. Scratching movements and facilitation of the scratch reflex produced by tubocurarine in cats. *The Journal of Physiology*. 1960; 153: 35-51. Epub 1960/08/01.
- [59] al-Zamil Z, Bagust J, Kerkut GA. Tubocurarine and strychnine block Renshaw cell inhibition in the isolated mammalian spinal cord. *General Pharmacology*. 1990; 21(4): 499-509. Epub 1990/01/01.
- [60] Deliaquina TG, Feldman AG. [Modulation of Renshaw cell activity during scratching]. *Neirofiziolgiia* 1978; 10(2): 210-1. Epub 1978/01/01. Moduliatsiia aktivnosti kletok Renshou pri chesanii.

- [61] Nishimaru H, Restrepo CE, Kiehn O. Activity of Renshaw cells during locomotor-like rhythmic activity in the isolated spinal cord of neonatal mice. *The Journal of Neuroscience : the official journal of the Society for Neuroscience*. 2006; 26(20): 5320-8. Epub 2006/05/19.
- [62] Carrera I, Dennis R, Mellor DJ, Penderis J, Sullivan M. Use of magnetic resonance imaging for morphometric analysis of the caudal cranial fossa in Cavalier King Charles Spaniels. *American Journal of Veterinary Research*. 2009; 70(3): 340-5. Epub 2009/03/04.
- [63] Rusbridge C, MacSweeney JE, Davies JV, Chandler K, Fitzmaurice SN, Dennis R, et al. Syringohydromyelia in Cavalier King Charles spaniels. *Journal of the American Animal Hospital Association*. 2000; 36(1): 34-41. Epub 2000/02/10.
- [64] Upchurch JJ, McGonnell IM, Driver CJ, Butler L, Volk HA. Influence of head positioning on the assessment of Chiari-like malformation in Cavalier King Charles spaniels. *The Veterinary Record*. 2011; 169(11): 277. Epub 2011/08/10.
- [65] Cerda-Gonzalez S, Dewey CW, Scrivani PV, Kline KL. Imaging features of atlanto-occipital overlapping in dogs. *Veterinary Radiology & Ultrasound : the official journal of the American College of Veterinary Radiology and the International Veterinary Radiology Association*. 2009; 50(3): 264-8. Epub 2009/06/11.
- [66] Botelho RV, Ferreira ED. Angular craniometry in craniocervical junction malformation. *Neurosurgical Review*. 2013. Epub 2013/05/04.
- [67] Bynevelt M, Rusbridge C, Britton J. Dorsal dens angulation and a Chiari type malformation in a Cavalier King Charles Spaniel. *Veterinary Radiology & Ultrasound : the official journal of the American College of Veterinary Radiology and the International Veterinary Radiology Association*. 2000; 41(6): 521-4. Epub 2000/12/29.
- [68] Stalin CE, Rusbridge C, Granger N, Jeffery ND. Radiographic morphology of the cranial portion of the cervical vertebral column in Cavalier King Charles spaniels and its relationship to syringomyelia. *American Journal of Veterinary Research*. 2008; 69(1): 89-93. Epub 2008/01/03.
- [69] Rusbridge C. Neurological diseases of the Cavalier King Charles spaniel. *The Journal of Small Animal Practice*. 2005; 46(6): 265-72. Epub 2005/06/24.
- [70] Rusbridge C, Knowler SP. Coexistence of occipital dysplasia and occipital hypoplasia/syringomyelia in the Cavalier King Charles spaniel. *The Journal of Small Animal Practice*. 2006; 47(10): 603-6. Epub 2006/09/29.
- [71] Driver CJ, De Risio L, Hamilton S, Rusbridge C, Dennis R, McGonnell IM, et al. Changes over time in craniocerebral morphology and syringomyelia in Cavalier King Charles spaniels with Chiari-like malformation. *BMC Veterinary Research*. 2012; 8(1): 1-7.
- [72] Matiassek LA, Platt SR, Shaw S, Dennis R. Clinical and magnetic resonance imaging characteristics of quadrigeminal cysts in dogs. *Journal of Veterinary Internal Medicine / journal of the American College of Veterinary Internal Medicine*. 2007; 21(5): 1021-6. Epub 2007/10/18.
- [73] Loderstedt S, Benigni L, Chandler K, Cardwell JM, Rusbridge C, Lamb CR, et al. Distribution of syringomyelia along the entire spinal cord in clinically affected Cavalier King Charles spaniels. *Vet J*. 2011. Epub 2011/01/11.
- [74] Harcourt-Brown TR, Parker JE, Granger N, Jeffery ND. Effect of middle ear effusion on the brain-stem auditory evoked response of Cavalier King Charles spaniels. *Vet J*. 2011; 188(3): 341-5. Epub 2011/01/05.
- [75] Rusbridge C. Neurological diseases of the Cavalier King Charles spaniel. *Journal of Small Animal Practice*. 2005; 46(6): 265-72.
- [76] Whittaker DE, English K, McGonnell IM, Volk HA. Evaluation of cerebrospinal fluid in Cavalier King Charles spaniel dogs diagnosed with Chiari-like malformation with or without concurrent syringomyelia. *Journal of Veterinary Diagnostic Investigation : official publication of the American Association of Veterinary Laboratory Diagnosticians, Inc*. 2011; 23(2): 302-7. Epub 2011/03/15.
- [77] Dewey CW, Berg JM, Barone G, Marino DJ, Stefanacci JD. Foramen magnum decompression for treatment of caudal occipital malformation syndrome in dogs. *Journal of the American Veterinary Medical Association*. 2005; 227(8): 1270-5, 50-1. Epub 2005/11/04.
- [78] Dewey CW, Marino DJ, Bailey KS, Loughin CA, Barone G, Bolognese P, et al. Foramen magnum decompression with cranioplasty for treatment of caudal occipital malformation syndrome in dogs. *Veterinary Surgery : VS*. 2007; 36(5): 406-15. Epub 2007/07/07.
- [79] Rusbridge C. Chiari-like malformation with syringomyelia in the Cavalier King Charles spaniel: long-term outcome after surgical management. *Veterinary Surgery : VS*. 2007; 36(5): 396-405. Epub 2007/07/07.
- [80] Vermeersch K, Van Ham L, Caemaert J, Tshamala M, Taeymans O, Bhatti S, et al. Suboccipital craniectomy, dorsal laminectomy of C1, durotomy and dural graft placement as a treatment for syringohydromyelia with cerebellar tonsil herniation in Cavalier King Charles spaniels. *Veterinary Surgery : VS*. 2004; 33(4): 355-60. Epub 2004/07/03.
- [81] Motta L, Skerrett GC. Syringosubarachnoid shunt as a management for syringohydromyelia in dogs. *The Journal of Small Animal Practice*. 2012; 53(4): 205-12. Epub 2012/03/16.
- [82] Brown PD, Davies SL, Speake T, Millar ID. Molecular mechanisms of cerebrospinal fluid production. *Neuroscience*. 2004; 129(4): 957-70. Epub 2004/11/25.

- [83] Ameli PA, Madan M, Chigurupati S, Yu A, Chan SL, Pattisapu JV. Effect of acetazolamide on aquaporin-1 and fluid flow in cultured choroid plexus. *Acta Neurochir Suppl.* 2012; 113: 59-64.
- [84] Phillips PH. Pediatric pseudotumor cerebri. *International Ophthalmology Clinics.* 2012; 52(3): 51-9, xii. Epub 2012/06/07.
- [85] Lindvall-Axelsson M, Nilsson C, Owman C, Winblad B. Inhibition of cerebrospinal fluid formation by omeprazole. *Experimental Neurology.* 1992; 115(3): 394-9. Epub 1992/03/01.
- [86] Javaheri S, Corbett WS, Simbartl LA, Mehta S, Khosla A. Different effects of omeprazole and Sch 28080 on canine cerebrospinal fluid production. *Brain Research.* 1997; 754(1-2): 321-4. Epub 1997/04/18.
- [87] Naveh Y, Kitzes R, Lemberger A, Ben-David S, Feinsod M. Effect of histamine H2 receptor antagonists on the secretion of cerebrospinal fluid in the cat. *Journal of Neurochemistry.* 1992; 58(4): 1347-52. Epub 1992/04/01.
- [88] Armstrong WE, Sladek CD. Evidence for excitatory actions of histamine on supraoptic neurons in vitro: mediation by an H1-type receptor. *Neuroscience.* 1985; 16(2): 307-22. Epub 1985/10/01.
- [89] Faraci FM, Mayhan WG, Heistad DD. Effect of vasopressin on production of cerebrospinal fluid: possible role of vasopressin (V1)-receptors. *The American Journal of Physiology.* 1990; 258(1 Pt 2): R94-8. Epub 1990/01/01.
- [90] National Library of Medicine. GABAPENTIN solution <http://dailymed.nlm.nih.gov/dailymed/lookup.cfm?setid=c64c09c9-0567-4a4f-b2c6-8f667986c9af>: U.S. National Library of Medicine; 2013 [updated March 2013; cited 2013 8th July ].
- [91] Hagiwara T, Mukaisho K, Nakayama T, Sugihara H, Hattori T. Long-term proton pump inhibitor administration worsens atrophic corpus gastritis and promotes adenocarcinoma development in Mongolian gerbils infected with *Helicobacter pylori*. *Gut.* 2011; 60(5): 624-30. Epub 2010/11/26.
- [92] Chapman DB, Rees CJ, Lippert D, Sataloff RT, Wright SC, Jr. Adverse effects of long-term proton pump inhibitor use: a review for the otolaryngologist. *Journal of Voice : official journal of the Voice Foundation.* 2011; 25(2): 236-40. Epub 2010/02/11.
- [93] Lewis T, Swift S, Woolliams JA, Blott S. Heritability of premature mitral valve disease in Cavalier King Charles spaniels. *Vet J.* 2011; 188(1): 73-6. Epub 2010/03/30.
- [94] Adams VJ, Evans KM, Sampson J, Wood JL. Methods and mortality results of a health survey of purebred dogs in the UK. *The Journal of Small Animal Practice.* 2010; 51(10): 512-24. Epub 2010/10/30.
- [95] Pedersen HD. Effects of mild mitral valve insufficiency, sodium intake, and place of blood sampling on the renin-angiotensin system in dogs. *Acta Veterinaria Scandinavica.* 1996; 37(1): 109-18. Epub 1996/01/01.
- [96] Connell JM, MacKenzie SM, Freel EM, Fraser R, Davies E. A lifetime of aldosterone excess: long-term consequences of altered regulation of aldosterone production for cardiovascular function. *Endocrine Reviews.* 2008; 29(2): 133-54. Epub 2008/02/23.
- [97] Parrinello G, Torres D, Paterna S. Salt and water imbalance in chronic heart failure. *Internal and Emergency Medicine.* 2011; 6 Suppl 1: 29-36. Epub 2011/11/02.
- [98] Kawabata A. Prostaglandin E2 and pain--an update. *Biological & Pharmaceutical Bulletin.* 2011; 34(8): 1170-3. Epub 2011/08/02.
- [99] Tremont-Lukats IW, Megeff C, Backonja MM. Anticonvulsants for neuropathic pain syndromes: mechanisms of action and place in therapy. *Drugs.* 2000; 60(5): 1029-52. Epub 2000/12/29.
- [100] Nolan AM. Pharmacology of Analgesic Drugs. In: Flecknell PA, Waterman-Pearson A, editors. *Pain Management in Animals.* London: W.B. Saunders; 2000. p. 21-52.
- [101] Barnes PJ. Anti-inflammatory actions of glucocorticoids: molecular mechanisms. *Clin Sci (Lond).* 1998; 94(6): 557-72. Epub 1998/12/17.
- [102] Gellman H. Reflex sympathetic dystrophy: alternative modalities for pain management. *Instructional Course Lectures.* 2000; 49: 549-57. Epub 2000/06/01.
- [103] Wong HK, Tan KJ. Effects of corticosteroids on nerve root recovery after spinal nerve root compression. *Clinical Orthopaedics and Related Research.* 2002; (403): 248-52. Epub 2002/10/03.
- [104] Rutherford L, Wessmann A, Rusbridge C, McGonnell IM, Abeyesinghe S, Burn C, et al. Questionnaire-based behaviour analysis of Cavalier King Charles spaniels with neuropathic pain due to Chiari-like malformation and syringomyelia. *Vet J.* 2012. Epub 2012/06/29.
- [105] Hannerz J, Ericson K. The relationship between idiopathic intracranial hypertension and obesity. *Headache.* 2009; 49(2): 178-84. Epub 2009/02/19.
- [106] Arnautovic KI, Muzevic D, Splavski B, Boop FA. Association of increased body mass index with Chiari malformation Type I and syrinx formation in adults. *Journal of Neurosurgery.* 2013. Epub 2013/05/15.
- [107] Lewis T, Rusbridge C, Knowler P, Blott S, Woolliams JA. Heritability of syringomyelia in Cavalier King Charles spaniels. *Vet J.* 2010; 183(3): 345-7. Epub 2009/11/17.
- [108] Knowler SP, McFadyen AK, Rusbridge C. Effectiveness of breeding guidelines for reducing the prevalence of syringomyelia. *Veterinary Record.* 2011. Epub 2011/10/15.
- [109] BVA T. Chiari Malformation/Syringomyelia Scheme (CM/SM Scheme). [http://www.bva.co.uk/canine\\_health\\_schemes/hiariMalformationSyringomyeliaSchemeCMSMScheme.aspx](http://www.bva.co.uk/canine_health_schemes/hiariMalformationSyringomyeliaSchemeCMSMScheme.aspx): BVA, The; 2013 [cited 2013 8th July ].



- [110] Club TK. Mate Select Online Services <http://www.the-kennel-club.org.uk/services/public/mateselect/test/Default.aspx>: Club, The Kennel; 2012 [cited 2013 8th July].
- [111] BVA T. Appendix 1 Breeding recommendations until relevant EBVs are available. [PDF] [http://www.bva.co.uk/public/documents/CM-SM\\_breeding\\_recommendations.pdf](http://www.bva.co.uk/public/documents/CM-SM_breeding_recommendations.pdf): BVA, The; 2012 [cited 2013 8th July].
- [112] Jacques A. Cavaliers for Life. [http://www.cavaliers.be/newsite/populatieonderzoek/e\\_home.htm](http://www.cavaliers.be/newsite/populatieonderzoek/e_home.htm) 2012 [cited 2013 8th July].
- [113] Schmidt MJ, Volk H, Klingler M, Failing K, Kramer M, Ondreka N. Comparison of closure times for cranial base synchondroses in mesaticephalic, brachycephalic, and Cavalier King Charles Spaniel dogs. *Veterinary Radiology & Ultrasound: the official journal of the American College of Veterinary Radiology and the International Veterinary Radiology Association*. 2013. Epub 2013/06/21.
- [114] Stockyard CR. The genetic and endocrinic basis for differences in form and behaviour. *Anatomical Memoirs*. Philadelphia: Wistar Institute of Anatomy and Biology; 1941. p. 40 - 357.
- [115] Driver CJ, Rusbridge C, Cross HR, McGonnell I, Volk HA. Relationship of brain parenchyma within the caudal cranial fossa and ventricle size to syringomyelia in Cavalier King Charles spaniels. *The Journal of Small Animal Practice*. 2010; 51(7): 382-6. Epub 2010/06/12.
- [116] Shaw TA, McGonnell IM, Driver CJ, Rusbridge C, Volk HA. Caudal cranial fossa partitioning in Cavalier King Charles spaniels. *The Veterinary Record*. 2013; 172(13): 341. Epub 2013/02/07.
- [117] Cross HR, Cappello R, Rusbridge C. Comparison of cerebral cranium volumes between Cavalier King Charles spaniels with Chiari-like malformation, small breed dogs and Labradors. *The Journal of Small Animal Practice*. 2009; 50(8): 399-405. Epub 2009/08/20.
- [118] Driver CJ, Rusbridge C, McGonnell IM, Volk HA. Morphometric assessment of cranial volumes in age-matched Cavalier King Charles spaniels with and without syringomyelia. *The Veterinary Record*. 2010; 167(25): 978-9. Epub 2011/01/26.
- [119] Fenn J, Schmidt MJ, Simpson H, Driver CJ, Volk HA. Venous sinus volume in the caudal cranial fossa in Cavalier King Charles spaniels with syringomyelia. *Vet J*. 2013. Epub 2013/06/13.
- [120] Shaw TA, McGonnell IM, Driver CJ, Rusbridge C, Volk HA. Increase in cerebellar volume in Cavalier King Charles spaniels with Chiari-like malformation and its role in the development of syringomyelia. *PloS one*. 2012; 7(4): e33660. Epub 2012/04/17.
- [121] Driver CJ, De Risio L, Hamilton S, Rusbridge C, Dennis R, McGonnell IM, et al. Changes over time in craniocerebral morphology and syringomyelia in Cavalier King Charles spaniels with Chiari-like malformation. *BMC Veterinary Research*. 2012; 8(1): 215. Epub 2012/11/10.
- [122] Driver CJ, Watts V, Bunck AC, Van Ham LM, Volk HA. Assessment of cerebellar pulsation in dogs with and without Chiari-like malformation and syringomyelia using cardiac-gated cine magnetic resonance imaging. *Vet J*. 2013. Epub 2013/06/19.
- [123] Cerda-Gonzalez S, Olby NJ, Broadstone R, McCullough S, Osborne JA. Characteristics of cerebrospinal fluid flow in Cavalier King Charles Spaniels analyzed using phase velocity cine magnetic resonance imaging. *Veterinary Radiology & Ultrasound: the official journal of the American College of Veterinary Radiology and the International Veterinary Radiology Association*. 2009; 50(5): 467-76. Epub 2009/10/01.
- [124] Schmidt MJ, Ondreka N, Rummel C, Volk H, Sauerbrey M, Kramer M. Volume reduction of the jugular foramina in Cavalier King Charles spaniels with syringomyelia. *BMC Veterinary Research*. 2012; 8(1): 158. Epub 2012/09/08.
- [125] Carruthers H, Rusbridge C, Dube MP, Holmes M, Jeffery N. Association between cervical and intracranial dimensions and syringomyelia in the Cavalier King Charles spaniel. *The Journal of Small Animal Practice*. 2009; 50(8): 394-8. Epub 2009/08/20.
- [126] Hu HZ, Rusbridge C, Constantino-Casas F, Jeffery N. Histopathological investigation of syringomyelia in the Cavalier King Charles spaniel. *Journal of Comparative Pathology*. 2012; 146(2): 192-201.
- [127] Schmidt MJ, Roth J, Ondreka N, Kramer M, Rummel C. A potential role for substance P and interleukin-6 in the cerebrospinal fluid of Cavalier King Charles spaniels with neuropathic pain. *Journal of Veterinary Internal Medicine. official journal of the American College of Veterinary Internal Medicine*. 2013; 27(3): 530-5. Epub 2013/05/11.
- [128] Gustorff B, Dorner T, Likar R, Grisold W, Lawrence K, Schwarz F, et al. Prevalence of self-reported neuropathic pain and impact on quality of life: a prospective representative survey. *Acta Anaesthesiologica Scandinavica*. 2008; 52(1): 132-6. Epub 2007/11/03.
- [129] Suiter EJ, E. O, Pfau T, Volk HA, editors. Objective quantification of gait deficits in Cavalier King Charles spaniels with Chiari-Like Malformation and syringomyelia. 25th Annual Symposium of ESVN and ECVN; 2012; Ghent
- [130] Van Biervliet J, de Lahunta A, Ennulat D, Oglesbee M, Summers B. Acquired cervical scoliosis in six horses associated with dorsal grey column chronic myelitis. *Equine Veterinary Journal*. 2004; 36(1): 86-92. Epub 2004/02/06.



## COMMISSIONED PAPER (NL)

# Screening for Orthopaedic Genetic defects

## Part 1 Patella Luxation in dogs

*Herman Hazewinkel<sup>1\*</sup> Bernd Tellhelm<sup>2</sup> Peter Leegwater<sup>1</sup>*

### INTRODUCTION

Unlike the screening for Hip Dysplasia or Elbow Dysplasia, this skeletal disease has to be screened by physical examination of the animal, not by reading the radiographs, since patellar luxation can occur (grade 1,2 or 3) where the patella can be positioned inside the trochlea as well as overt luxation. (Figure 1)

During skeletal development, the contact between patella and trochlea is important for proper development of both structures with a perfect fit between the concave trochlea groove and the convex patella. Stifle joint extension and flexion is accomplished by the extensor mechanism of the stifle joint. This includes the quadriceps muscles, the straight patellar tendon and patella, the trochlear groove and the tibial tuberosity, the latter being the insertion point of the patellar tendon. During extension of the stifle joint the patella is not forced into the trochlea by the quadriceps as is the case during flexion, however, the patella is kept within the trochlear groove by the joint capsule and the retinaculum (the thickened tissue running from patella to fabellae), and the trochlea with its ridges.

This paper was commissioned by FECAVA for the special issue of EJCAP, Genetic/Hereditary Disease and Breeding.

### Aetiology of patella luxation

Non-traumatic patella luxation can develop due to a congenital or developmental malalignment of the extensor mechanism of the stifle joint <sup>[1]</sup>. In the case of non-traumatic patella luxations the fascia lata and retinaculum progressively become stretched due to malalignment of the extensor mechanism of the stifle joint. It has been suggested <sup>[2]</sup> that the patella can luxate or subluxate for

two reasons: (1) malposition of the patella due to medial or lateral traction of the distal insertion of the patellar tendon (tibial tuberosity); or (2) malposition of the distal femur in either its frontal (distal varus or valgus) or transverse plane (i.e. internal or external femoral torsion).

Other causes of medial patella luxation are described by Putman in his original thesis in 1968. Based on his investigations he hypothesized that coxa vara (ie a decreased angle of inclination of the femoral neck, together with a decreased femoral neck anteversion, ie relative retroversion can be responsible for a medial patella luxation <sup>[3]</sup>.

1 Department of Companion Animal Sciences, Faculty of Veterinary Medicine, Utrecht University, PO box 80.154, NL-3508 TD Utrecht, The Netherlands.

2 Justus-Liebig- Universität Giessen, Klinik für Kleintiere-Chirurgie, Frankfurterstrasse 108, D-35392 Giessen, Germany.

\*Corresponding author: Prof. Dr. H.A.W. Hazewinkel, DVM, PhD, Dipl. ECVS & ECVCN,

E-mail: H.A.W.Hazewinkel@uu.nl

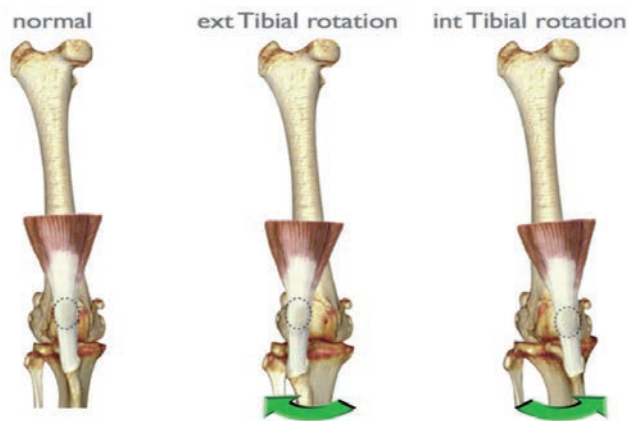


Figure 1. Drawings adapted from M. Petazzoni (2011) of normal, lateral and medial patella luxation (left to right) According to Petazzoni (2011) a medial patellar luxation, together with a normal femur, can occur only because of (1) internal rotation of the tibia related to the femur or (2) external tibial torsion. Likewise, a lateral patella luxation together with a normal femur can occur only because of two reasons: (1) external tibial rotation of the tibia related to the femur or (2) internal tibial torsion.<sup>[2]</sup>

## Consequences of patella luxation

Patella luxation may have severe consequences for locomotion of the dog, depending on the age of onset and the degree of luxation.

Immature dogs have open physal growth plates in the distal femur and proximal tibia until the age of 330 (range 136-392) days and 249 (range 143-435) days respectively<sup>[4]</sup>. The effect of compression on the physis is generally defined by the Hueter-Volkman principle: there is decreased linear growth of the physis resulting from increased compression, but growth rate is undisturbed at the lateral side where static pressure is decreased (Figure 2)<sup>[5]</sup>. Hypoplasia of the distal femoral epiphysis has been found to occur in dogs with patellar luxation (Fig. 2), and was held responsible for bowing of the distal femur (Putman, 1968), however this can also be considered a cause of the eccentric quadriceps loading<sup>[6]</sup>.

The degree of varus malformation of the femur depends on the duration of the luxation and the growth rate of the dog [Hulse and Shires, 1986]. In addition, the tibial tuberosity will rotate in a medial direction together with varus deformation of the proximal tibia and external rotation of the distal tibia.<sup>[7]</sup> (Figure 2).

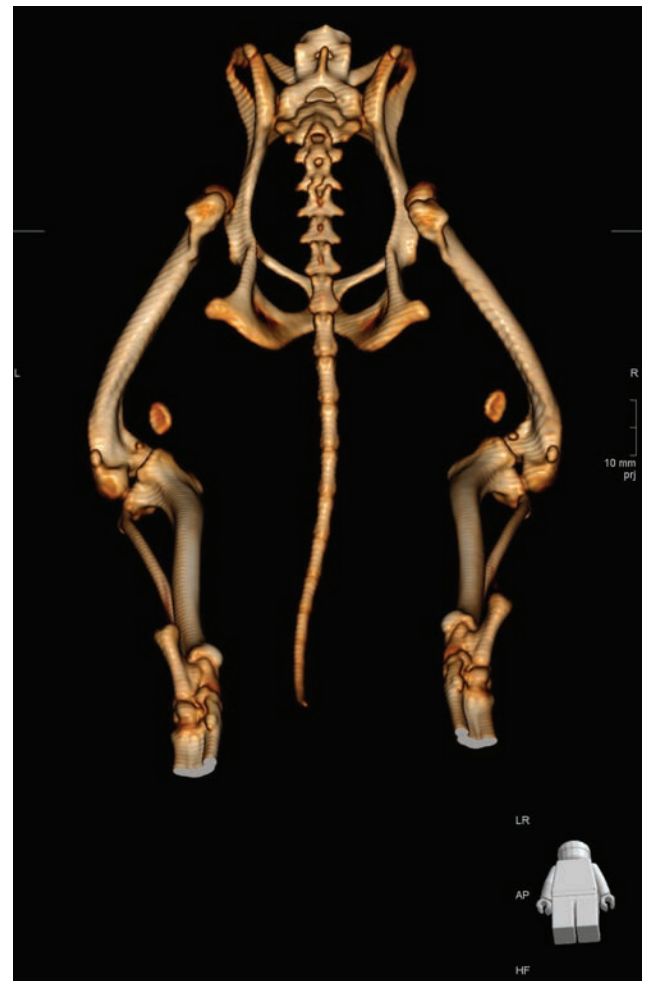

Figure 2: 3-D reconstruction of a 6 month old Chihuahua with inability to bear weight on both hind legs or to straighten the stifle joints. Severe bowing of both hind legs, based on the Hueter-Volkman principle (see text). Notice bilateral hip luxation, patellar luxation, internal rotation of both tibias and external rotation of both calcanei (courtesy Division Radiology, Prof.dr. G. Voorhout).

In addition to the inability to use the leg for weight bearing and jumping, the following consequences of patella luxation play a role:

In immature dogs, the severity of the grading of patella luxation can progress from grade 2 to grade 3, and from grade 3 to grade 4 (for grading see below)<sup>[6]</sup> due to the following aspects:.

- The trochlear ridge will be lowered and the shape of the patella changed due to repeated luxations with the consequence that the patella will luxate even more easily<sup>[6]</sup>. In cases of medial patellar luxation in mature dogs with closed growth plates, the whole tibia will internally rotate, whereas with lateral patellar luxation there will be external rotation with lateral displacement of the tibial tuberosity<sup>[8]</sup>.

- The patella (whose correct development depends on contact with the trochlea) will be malformed. In cases of permanent patella luxation in immature dogs the patella will stay flat or might even not be formed<sup>[8]</sup>. The trochlea groove develops according to the Hueter-Volkman's principle under the constant pressure of the patella. In cases of patella luxation at a very young age, the trochlea groove will not develop and the joint cartilage in the trochlea is convex rather than concave. With plain radiological investigation, even with a special skyline view, this aspect can be missed since the thickening is only cartilage<sup>[8]</sup>.

Also, in mature dogs, in cases of low grade (i.e. grade 2) patella luxation, as the patella moves out of the trochlear groove there will be damage to the articular cartilage of the patella and of the trochlear ridge. As cartilage is damaged, the subchondral bone is exposed to inflammatory substances and osteoarthritis will develop. In this situation the dog is not only lame, but also has a painful condition<sup>[9]</sup>.

## Factors which may influence luxation of the patella

The phenotype of patella luxation may be influenced by a variety of factors, including:

- Excessive contraction or hypertrophy of the quadriceps muscle can keep the patella inside the trochlea whereas if the muscle is more relaxed (for example if the dog is under sedation) the patella can be luxated manually (i.e. Grade 1 or 2 patella luxation) in some cases. Therefore muscle tension should be taken into account during screening: in cases of extreme muscle contraction re-investigation under sedation is advocated.
- In cases of torsion of the femur along its long axis, hip luxation or mal-union of a femoral fracture, the patella can luxate out of the trochlea. It is therefore important to obtain a full history and consider the whole limb during screening.
- In cases of rupture of the lateral or medial retinaculum due to trauma, the patella can reveal a medial or lateral grade 1 or 2 patellar luxation. Iatrogenic patella luxation following stifle joint arthrotomy [Brinker, personal communication] can be caused due to dehiscence of retinacular sutures.
- Weakness of collagen can occur, for example in Cushing's disease and Ehlers Danlos syndrome and

can coincide with weakness of the retinaculum. Even without additional trauma, the laxity of the collagen structure may allow for patella luxation in these two disease states. In cases of Cushing's disease weight gain can aggravate the symptoms, especially in cases of bilateral stationary luxation<sup>[10]</sup>. Since both diseases can be diagnosed also with other characteristic findings, a secondary patella luxation is unlikely to be overlooked. (Fig 3)



*Figure 3: Two year old chocolate Labrador Retriever with remarkable loose skin, which appeared very vulnerable to lacerations due to the Ehlers Danlos Syndrome. The dog suffered from bilateral patella luxation from a young age, even though no malalignment of the extensor mechanism of the stifle could be found.*

## Screening for patella luxation

1. Screening for patella luxation starts with obtaining a detailed history: is there evidence of lameness, or an inability to jump? Has this been repeatable? Has the dog previously had surgery on the leg?
2. With the dog in a standing position on the investigation table and the investigator caudal to the dog, the patella is located by following the patellar tendon proximally, starting at the tibial crest. Effusion of the stifle joint is mainly detectable medial and lateral to the patellar tendon (Fig 4a); new bone formation can be detected in more chronic cases of osteoarthritis at the edges of the trochlea (with the thumb on the lateral edge and the forefinger on the medial edge), whereas a broadening of the stifle joint due to buttress formation can be an indication of cruciate ligament rupture. The stability of the patella is checked by pushing the patella medially and laterally with the thumb and forefinger, respectively,



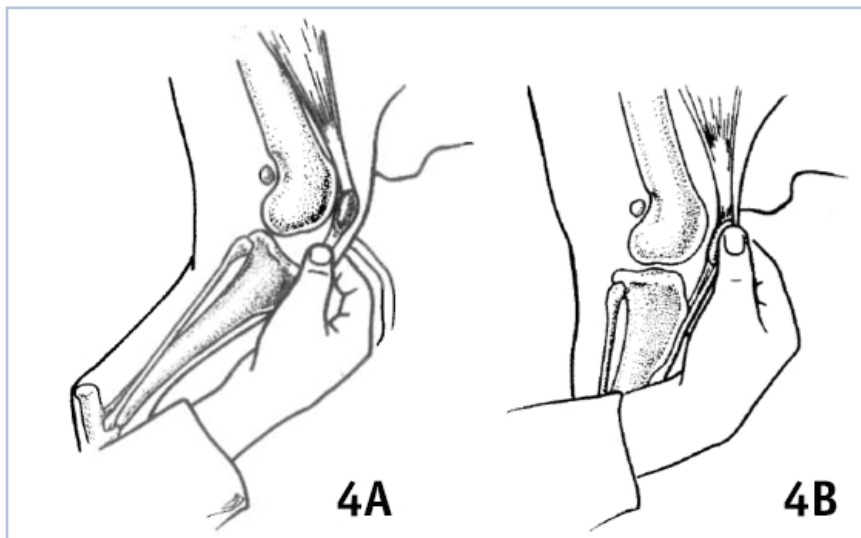


Figure 4) With the dog in standing position A. The patella can be located inside the patella tendon by following the latter from the tibial tubercle. B While the stifle joint is hyperextended, the patella is pushed medially and laterally in a horizontal direction, in order to check for patella luxation.<sup>[11]</sup>

while the stifle is held extended (Fig. 4b)<sup>[11]</sup>. Finally each leg should be extended and flexed allowing the investigator to palpate whether or not the patella spontaneously luxates or repositions. In the normal dog it should not be possible to move the patella over the edge of the trochlea, or for spontaneous luxation of the patella to occur, and there should be no crepitation.

So far the following findings should have been determined and noted:

1. The position of the patella relative to the trochlea. The shape and the depth of the trochlea should have been palpated and noted. If the patella is luxated, whether it can be reduced into the trochlea or not.
2. Whether there are overt signs of osteoarthritis(OA) and any evidence for concurrent cruciate ligament rupture.
3. If the patella is "loose", i.e. movable within the trochlea in a horizontal line but not outside the trochlea. When the patella cannot be luxated in

lateral recumbency (see later) this finding should be recorded as a "loose patella".

4. When the patella luxates during extension and flexion of the stifle joint or can deliberately be luxated, laterally and/or medially, the shape and depth of the trochlea should be evaluated and attention given to the occurrence of crepitation; these findings should be registered.
3. With the dog in lateral recumbency, the investigator should stand caudal to the dog with one hand placed over the stifle joint, and the other hand round the distal tibia. The stifle should be extended and flexed and, in the context of screening for patella luxation, note is taken of signs of crepitation and possible luxation or repositioning of the patella. Next, the examiner holds the metatarsus and uses it as a lever to rotate the tibia first internally (5a), then externally, whilst flexing and extending the stifle and feels for the ability to luxate the patella with the other hand. (Fig. 5b)<sup>[11]</sup>.

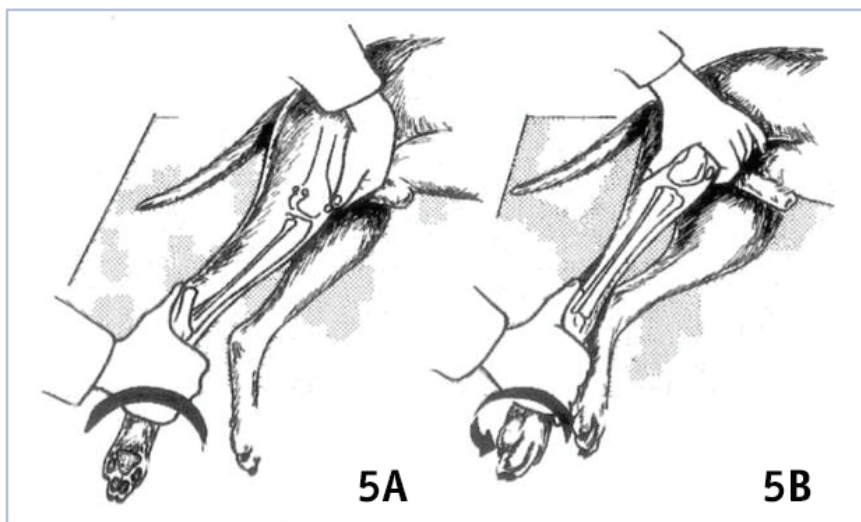


Figure 5) Investigation with the dog in lateral recumbency. A With the stifle held in extension the tibia is internally rotated while the patella is pushed in a medial direction with the left thumb to check for medial patella luxation. B With the stifle joint still in hyperextension, the tibia is externally rotated and the stifle assessed for lateral patella luxation. (from: Hazewinkel et al, 2009)<sup>[11]</sup>

Following this part of the investigation the following additional findings can be observed and should be noted:

5. With flexion and extension, crepitation can be noticed in advanced cases of OA due to articular cartilage damage.
6. With flexion and extension it might be possible to palpate the patella luxating and repositioning outside or inside the trochlea, respectively, in case of patellar luxation grade 3
7. During internal or external rotation of the tibia, the tibia tuberosity will also be displaced in a medial or lateral direction, respectively, and therefore displace the patella tendon with the patella in it, also in a medial and lateral direction, respectively. When patellar luxation occurs this will be registered as patella luxation grade 2.
8. During internal or external rotation of the tibia, if the patella can be luxated manually and reduce immediately and spontaneously it is grade 1, whereas if manual reduction is required it is grade 2. When the patella luxates, but reduces after repositioning the tibia then a grade 3 can be registered. Only in cases where the patella is luxated during investigation and cannot be repositioned at all is a grade 4 patella luxation registered.<sup>[3]</sup>

The form should be completed when both stifle joints have been investigated in the standing and lying position. The dog will score according to the highest detected grade, although the findings of the right and the left stifle joint should be registered separately.

All the findings as stated above are relevant to the following scoring form:

## Patella luxation screening form

### I: General information

Identification of dog, owner, and screening authority; date of investigation (>12 months of age), undersigned by investigating veterinarian, undersigned by owner to declare that the dog has not been operated on for patella luxation and allowing further notice to Kennel Club.

### II: Patella luxation score

Patella luxation grade 0 (= bilateral free from patella luxation)

*Table 1: Grading of patella luxation with corresponding findings*

Patella Luxation scoring	Characteristics during investigation
PL – grade 0	Patellae are moving inside trochlear groove and cannot be manually luxated.
PL – loose	patella can be manually positioned on the ridges of the trochlear groove, but not out of the groove completely
PL – grade 1	manually luxatable patella with spontaneous repositioning
PL – grade 2	spontaneous luxation with repositioning upon active extension (with or without concurrent rotation of the tibia)
PL – grade 3	constant spontaneous patellar luxation which can be manually reduced
PL – grade 4	constant spontaneous patellar luxation which cannot be manually reduced

*The scheme is the version of Putnam's scoring system<sup>[3]</sup>.*

*Grades 1-4 can occur in a medial and/or lateral direction: the grade as well as the direction of the luxation (medial, lateral or both) should be recorded for each stifle,, and recorded separately.*

**Loose patella:** right and/or left patella can be horizontally displaced more than usually found in dogs, but does not luxate beyond the trochlear ridge

**Patella luxation grade 1:** The patella can be luxated by horizontally directed force in a medial and/or lateral direction over the edge of the trochlear ridge, and will reposition immediately and spontaneously without supportive rotation of the tibia.

**Patellar luxation grade 1:** The patella can be luxated by horizontal directed force in a medial and/or lateral direction over the edge of the trochlear ridge while the tibia is internally or externally rotated, respectively, and will reposition immediately spontaneously without supportive rotation of the tibia.

**Patellar luxation grade 2:** During joint movement the patella will spontaneously luxate, or the patella will luxate without horizontal directed force out of the trochlea during rotation of the tibia in relation to the femur and will not reposition spontaneously, i.e. without supportive force or without tibial rotation.

**Patellar luxation grade 3:** The patella is luxated or can easily be luxated, and reluxates immediately after manual repositioning of the patella inside the trochlear groove.

**Patellar luxation grade 4:** The patella is luxated laterally or medially, and it is impossible to reposition the patella inside the trochlear groove.

It is very unusual that dogs should require sedation for patella screening. All findings as given above, are scored the same as in dogs without sedation. It should be noted that in most cases patella luxation is not painful. Only in cases of loose patella when too excessive force is applied, will the dog react with extreme pain and this must be avoided.

The consistency of screening quality both in an individual investigator and between investigators warrants both experience and fine tuning. In the Netherlands the official scoring is performed by certified companion animal surgical specialists.

*Table 2. Number of dogs from a variety of breeds screened for patella luxation in the U.S.A.*

Breed	Rank number	Number of evaluated dogs between January 1974 and Dec. 2011	Percent dogs affected with patella luxation
Pomeranian	1	559	41.1
Yorkshire Terrier	2	333	24.3
Cocker spaniel	4	742	15.8
Chow chow	9	352	10.2
Shetland sheepdog	12	67	9.0
Labrador	15	555	6.8
Schipperke	32	336	4.5
Flatcoated retriever	71	1833	1.6
Newfoundland	95	1371	0.6
Belgian Malinois	98	93	0.0

*Results from screening in the United States of America as presented by the Orthopaedic Foundation for Animals of more than 100 breeds (www.ofa.org)*

## Incidence and effect of screening

### Incidence of patella luxation in Flatcoated Retrievers

The Flatcoated Retriever, whose breed standard was accepted by the British Kennel Club in 1923, is officially bred in The Netherlands with offspring documentation since 1960. The annual birth rate of Flatcoated Retrievers (FR) in The Netherlands is approximately 700. In a pilot study performed in 1989 including 354 Flatcoated Retrievers, all standardized investigated by the same orthopedic specialist (Prof Meutstege), it revealed that 40% of the Flatcoated Retrievers were not free of patella luxation and that only 11% of these dogs were bilaterally affected. Luxations included grade 1 to 4 and were in 19% medial, 13% lateral, and in 8% both medial and lateral. It was remarkable that both genders were equally represented and that the incidence of patella luxation in this breed is three times of what is registered in the USA (Table 2). This can be explained by the large percentage of grade 1 and 2 patella luxations, which can only be notified on patella screening. When 10-times more Flatcoated Retrievers were investigated two decades later the analysis showed (see Table 3)

Table 4 shows a remarkable finding that the lateral patellar luxation is diagnosed more frequently than the medial patellar luxation, this is contrary to what has

*Table 3. Incidence of patella luxation in Flatcoated retrievers and dividing in gender*

Flatcoated retrievers	% Males (n= 1898)	% Females (n=1936)	% All (n=3834)
Patella luxation negative	83.0	70	76.4
• Normal	62	50.5	
• Loose	21	19.5	
Patella luxation	17.0	30	23.6
• Grade 1	15.7	28.2	
• Grade 2	0.9	1.2	
• Grade 3	0.1	0.1	
• Grade 4 (surgery) <sup>#</sup>	0.3	0.5	

<sup>#</sup>When owners report that the dog has been surgically treated for patellar luxation, it is automatically a "grade 4 patellar luxation"

Table 4. Direction of patella luxation

Direction of luxation	Males	Females	
Medial	165	113	31%
Lateral	281	257	61%
Medial & lateral	4	63	8%
unknown	11	9	2

been reported in small samples in veterinary practices in large<sup>[12]</sup> or small breed<sup>[13]</sup> dogs.

### The incidence over the years.

The total number of Flatcoated retrievers with a patella luxation decreased gradually over the first 10 years of investigation and has since then tended to stay at the same incidence of 20%. (Fig. 5)

The incidence of patella luxation is depicted (Fig. 6b) for the Flatcoated Retriever (FCR), the Kooiker Dog (KK), the

Jack Russell (JR) and the Chihuahua (CHI)<sup>[14]</sup>. For the FCR and KK registration of organised screening started in 1994, with the incidence of patella luxation in the FCR at an unexplainable high level. In the FCR there was a fast decrease in patella luxation between 1995 and 1997 and a gradual decrease thereafter till an incidence of 6% in 2011.

In the KK the course was less gradual. There were small decreases and increases in some years, resulting in a 14% incidence in 2011. The JR patella luxation screening started in 2002, with an incidence for patella luxation of 33% and a fast decrease thereafter with 8% in 2011. For the Chihuahua however, patella luxation screening started in 2006 with a registered incidence of more than 50%, with scattering since then but with 50% again in 2006.

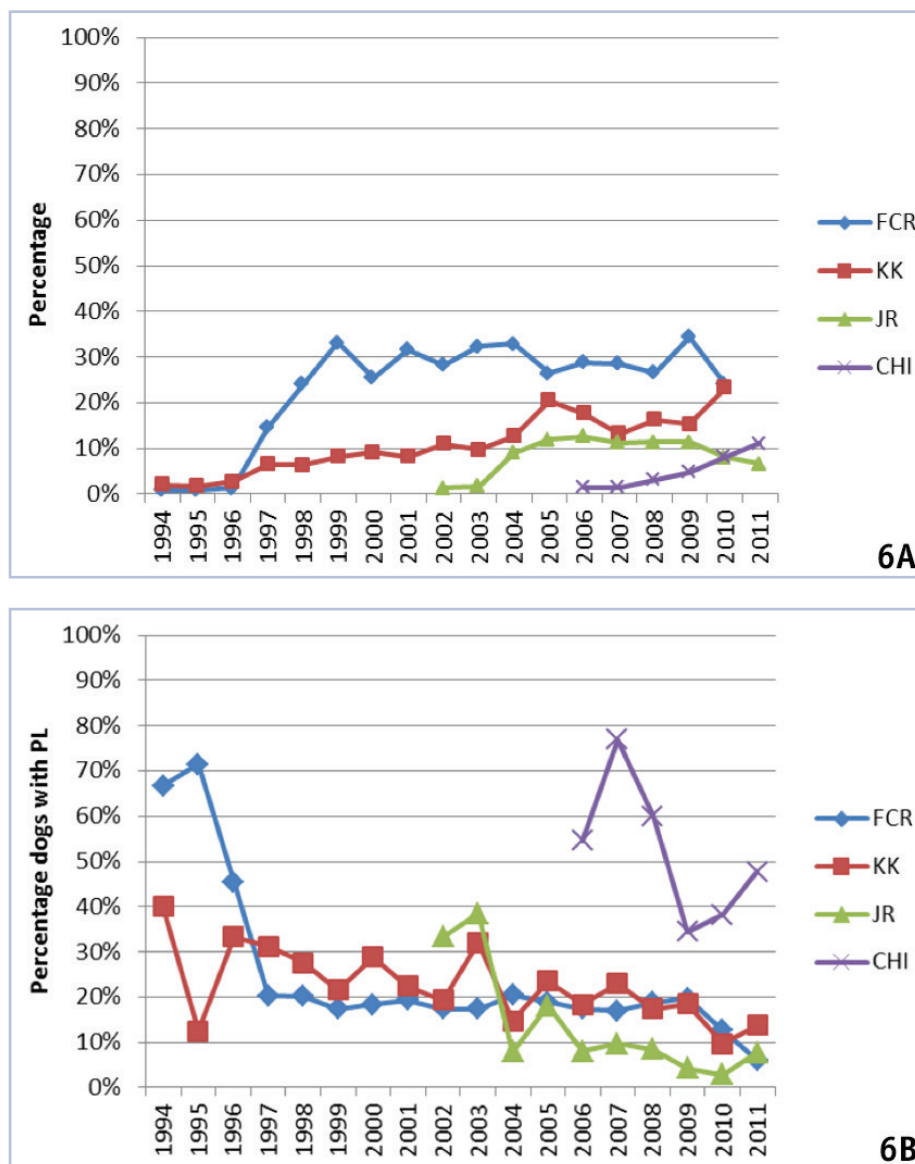


Fig 6. a: Percentage tested dogs from total number of registered dogs at Dutch Kennel Club per breed in time<sup>[14]</sup>. b: Incidence of patella luxation between 1994-2011 in 4288 screened dogs of four different breeds. Dog breeds: FCR= Flat-Coated Retriever; KK= Dutch Kooiker dog; JR= Jack Russell Terrier; CHI= Chihuahua.<sup>[14]</sup>



## For the interpretation of the incidence of patella luxation, the following aspects should be taken into account:

### - age at screening:

the minimal age for screening is set at 12 months, since at that age the skeleton is considered to be mature in most small and medium size dogs. However, young and mature dogs with grade 2 or 3 patellar luxation, and especially dogs with grade 4 patella luxation, will exhibit abnormal, intermittent (grade 2 and 3) or even permanent (grade 3 and 4) lameness, and thus will seldom be offered for patella luxation screening tests, unless there are very strict breeder club regulations.

In most cases the diagnosis can be made within the first 6 months of life <sup>[4,15]</sup>. Older animals with grades 1 and 2 may reveal clinical signs due to further breakdown of soft tissues and trochlear ridge damage and may develop OA, whereas at an earlier stage these dogs could have stayed unnoticeable during patella luxation screening at one year of age. So increasing age can coincide with an increase in the grading for patella luxation.

### - size of the mature dog

There is a breed predisposition for patella luxation, with a registered incidence up to 43% in Pomeranians (OFA). In general, smaller breeds are more likely to develop PL than larger breeds <sup>[12,13,16]</sup>. Medial and lateral PL both occur in dogs, with medial PL more common than lateral PL in all breed sizes, and lateral PL more common in large and giant breeds<sup>[13]</sup>. In congenital PL involvement of both stifles is common <sup>[13]</sup>, although evaluation of large groups is lacking (see Table 2) There are still no actual publications about the incidence of patella luxation in different breeds or types of dog and the different manifestations in Europe. Medial patella luxation is more common (70-80%) than lateral luxation in all breeds, with bilateral involvement in 20-25% <sup>[12]</sup>

### - sex

A sex predisposition of females being 1.4-1.9 times more affected than males <sup>[12,13,17]</sup>. In the four breeds presented here the ratio for patella luxation for males : females is for FCR 1:1.73, for KK 1:1.25, for JR 1:2.53 and for CHI 1:1.25<sup>[14]</sup>.

### - genetics

The breed predisposition for patella luxation, together with an early age of onset, has led to the

assumption that patella luxation is a heritable trait with the pattern of segregation pointing towards a polygenic, multi-factorial disorder. Although there are several theories about the pathophysiology of patella luxation, no underlying mechanism has yet been identified to explain the susceptibility of certain dogs to this disorder.

## Molecular genetic findings.

The breed selection process has consequences on the health status of dogs, with high rates of specific diseases in certain breeds due to increased frequencies of risk alleles. Disease frequency is therefore a breed characteristic phenotype that can be used for genetic analysis <sup>[16]</sup>. It was shown earlier that the size of purebred dogs is related with a single variant of the IGF1 gene for which a very high percentage of dogs of small size are homozygous <sup>[18]</sup>. Because of the apparent relation between dog size and the occurrence of patellar luxation, Chase et al. (2009) investigated the correlation between the allele frequency of a variant of a Single Nucleotide Polymorphism (SNP) in IGF1 in the DNA of a variety of dog breeds and the prevalence of the condition in those breeds. Indeed there was a significant relation between the entities across breeds. The result implies that IGF1, through its effect on size, influences the development of patellar luxation. It will be interesting to see whether IGF1 variants are also associated with the occurrence of patellar luxation within breeds. Preliminary results of genome wide association studies in the Dutch Kooikerdog and Flatcoated Retrievers do not point to a role for IGF1 in the condition in these breeds.

Genetic association studies are based on the principle that animals with the same phenotype have a high chance of sharing a responsible gene variant that they inherited from a common ancestor. In an association study, the frequency of a DNA marker variants is compared between groups of cases and controls from a single breed. Variants that are located close to genes that contribute to the phenotype will have a higher frequency in the group of cases if these variants originate from a single ancestor.

An association study with DNA markers close to collagen candidate genes COL6A1, COL6A3, COL9A1, COL9A2 and COL9A3 in Pomeranian dogs from Thailand indicated that these genes are not involved in patellar luxation in this population <sup>[19]</sup>. Genome wide association studies

of patellar luxation in Flatcoated Retrievers and Dutch Kooikerdogs with 20 000 and 170 000 SNPs, respectively, did not conclusively identify chromosome regions of interest. The preliminary results indicate that the genetic background of the disorder is probably highly complex with involvement of a large number of genes, each with a small effect. This means that large cohorts of more than 100 affected dogs from a single breed are needed to localize responsible genes.

## References

- [1] Harasen G. Patellar luxation: Pathogenesis and surgical correction. *Can Vet J.* 2006 Oct;47(10):1037-9.
- [2] Petazzoni M. 2011. Patellar luxation: when the tibia is guilty (Assessment of the tibia in dogs with MPL). *Proceedings of the Seminar on Patellar Luxation ESVOT, Lyon (France)*, pp. 3-7.
- [3] Putman RW. 1968. Patellar luxation in the dog. *MSc thesis Ontario Vet. Coll., Guelph, Ontario, Canada.*
- [4] Newton CD. 1985. Canine and feline epiphyseal plate closure and appearance of ossification centers; appendix C in: *Textbook of small animal orthopaedics.* Newton CD and Nunamaker DM (eds), Lippincott Philadelphia, pp. 1107-1113.
- [5] Bries AD, Weiner DS, Jacquet R, Adamczyk MJ, Morscher MA, Lowder E, Askew MJ, Steiner RP, Horne WI, Landis WJ. 2012. A study in vivo of the effects of a static compressive load on the proximal tibial physis in rabbits. *J Bone Joint Surg Am* 94:1111-1110.
- [6] Hulse D. 2011 Treatment of patellar luxation in immature dogs *Proceedings of the Seminar on Patellar Luxation. ESVOT, Lyon (France)*, pp. 55-56.
- [7] Hulse DA, Shires PK. 1986 Multiple ligament injuries of the stifle joint in the dog. *J Am Anim Hosp Assoc* 22: 105-110
- [8] Bonath KH, Prieur WD Patellaluxation in: *Kleintierkrankheiten Band 3: Orthopädische chirurgie und Traumatologie* Ulmer Verlag Stuttgart 1998, pp. 672-680
- [9] Piermattei DL, Flo GL, DeCamp CE. The stifle joint. In: Piermattei DL, Flo GL, DeCamp CE, eds. *Handbook of Small Animal Orthopedics and Fracture Repair.* 4th ed. St. Louis: Saunders; 2006. pg. 562-632.
- [10] Hazewinkel HAW, Nap RC. Hyperadrenokortizismus in: *Kleintierkrankheiten Band 3: Orthopädische chirurgie und Traumatologie* Ulmer Verlag Stuttgart 1998, pp.437-438
- [11] Hazewinkel HAW, Meij BP, Theyse LFH, van Rijssen B. Locomotor system Ch. 17 in: *Medical history and physical examination in companion animals* 2nd ed. Rijkberk A, van Sluijs FJ (eds) Saunders Toronto 2009 pp. 135-160
- [12] Priester WA. Sex, size and breed as risk factors in canine patella luxation *JAVMA* 160; 740-742, 1972
- [13] Hayes AG, Boudrieau RJ, Hungerford LL. Frequency and distribution of medial and lateral 286 patellar luxation in dogs: 124 cases (1982-1992). *J Am Vet Med Assoc.* 1994; 205: 716-720.
- [14] Bruinen TES 2013 Patellar luxation in four dog breeds in The Netherlands , student thesis Utrecht University.
- [15] Nunamaker M. 1985. Petallar luxation Ch 81 in: *Textbook of small animal orthopaedics,* Newton CD and Nunamaker DM (eds), Lippincott Philadelphia, pp. 941- 947.
- [16] Chase K, Jones P, Martin A, Ostrandere EA, Lark KG (2009) Genetic mapping of fixed phenotypes: Disease frequency as a breed characteristic. *J Hered*100 (Supp1): S37-S41.
- [17] Alam MR, Lee JI, Kang HS, Kim IS, Park SY, Lee KC, Kim NS. 2007 Frequency and distribution of patellar luxation in dogs. 134 cases (2000 to 2005). *Vet Comp Orthop Traumatol.* 20(1):59-64
- [18] Sutter MB, Bustamente CD, Chase K, Gray MM, Zhao K, Zhu L, Padhukasahasram B, Karlins E, Davis S, Jones PG, Quignon P, Johnson GS, Parker HG, Fretwell N, Mosher DS, Lawler DF, Satyaraj E, Nordborg M, Lark KG, Wayne RK, Ostrander EA. (2007) A single IGF1 allele is a major determinant of small size in dogs. *Science* 316: 112-115.
- [19] Soontornvipart K, Wangdee C, Kalpravidh M, Brahmasa A, Sarikaputi M, Temwichitr J, Lavrijsen IC, Theyse LF, Leegwater PA, Hazewinkel HA (2013) Incidence and genetic aspects of patellar luxation in Pomernanian dogs in Thailand. *Vet J* 196: 122-125.

## Part 2 Elbow Dysplasia

Herman Hazewinkel<sup>1\*</sup> Bernd Tellhelm<sup>2</sup> Peter Leegwater<sup>1</sup>

### INTRODUCTION

Elbow dysplasia (ED) is a term used to describe a group of lesions. Several of these lesions can be present concomitantly. In order to understand this phenomenon, it is thought that pathological incongruence in the elbow joint <sup>[1]</sup> plays a key role.

#### Categories of elbow joint incongruity

**A relatively too-long ulna.** This can either be caused by a growth plate disturbance of the radius (i.e. short radius syndrome) or by a hereditary disturbance as is seen especially in Bernese Mountain dogs. It has been demonstrated that the medial coronoid process develops exclusively by appositional ossification and is completed earlier in smaller than in larger dogs. This is unlike the anconeal process <sup>[2]</sup>, which develops as a separate centre of ossification. The ossification of the coronoid process is completed at 16 weeks in small breed dogs but not till 20 weeks in large breed dogs <sup>[2]</sup>. Fragmented medial coronoid process is probably due to overload of the coronoid process in the cartilage stage, as this type of incongruity coincides in 80% of the cases with a fragmentation of the apex of the medial coronoid process <sup>[3,3,5]</sup>(MCP)

**A relatively too-long radius.** This can either be due to a disturbed growth in length of the distal growth plate of the ulna (which may result either from trauma, or due to over-supplementation of the diet with calcium <sup>[6]</sup> or vitamin D <sup>[7]</sup>, or due to breed specific chondrodysplasia, as in Bassett hounds. The latter form of incongruity can coincide with a separation of the anconeal process from the ulna (when occurring < 5 months of age) (Fig. 2a) or with focal increasing pressure between the anconeal process and the humerus (i.e. distractio cubiti; Fig.2b) during growth when the anconeal process has fused with the olecranon (>5 months till maturity), the latter with severe lameness as a consequence.

#### An elliptical configuration of the humeral notch, instead of a circular notch, running parallel with the humeral condyle.

This type of incongruity has been described by Wind et al. (1986),<sup>[8]</sup> with an increased incidence in German Shepherd dogs: 16.3% in a French study in German shepherd dogs <sup>[9]</sup>. When severe enough at a young age, it might be the cause of a FCP together with an UAP.

**An incongruity between the radius and ulna in the radio-ulnar joint .**This leads to focal pressure between radius and ulna and thus causing a chip fracture of the ulna. Due to technical limitations, this etiology for medial coronoid disease (MCD) has not yet been proven to occur. In vivo investigation of the radio-ulnar joint is hampered by its location, whereas on CT imaging the alignment of the subchondral bone, rather than of the joint surface can be made visible.

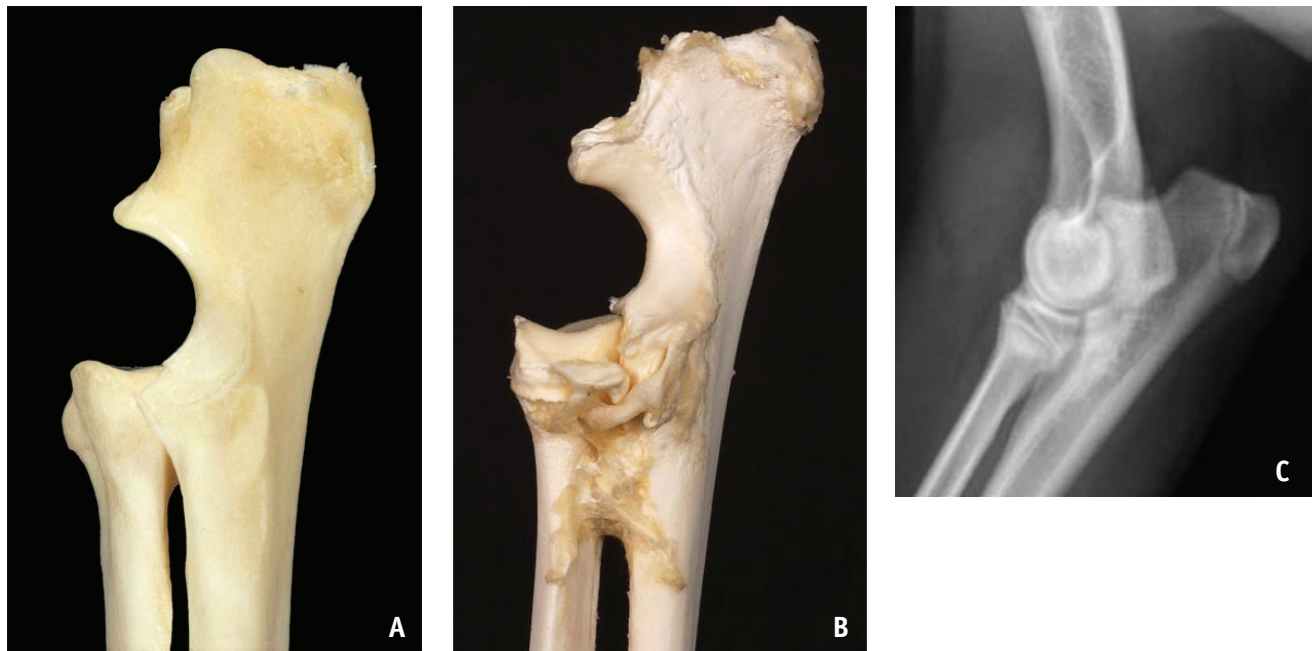
As a consequence, these incongruities can all lead to altered pressure points within the joint during weight-bearing, leading to cartilage trauma at different locations and thereby causing the following lesions: fragmented coronoid process (FCP), ununited anconeal process (UAP) and osteochondritis dissecans (OCD) (Fig. 5) of the medial part of the humeral condyle. According to the International Elbow Working Group [IEWG] incongruity is a fourth disorder (in addition to UAP, FCP, and OCD) of the elbow joint, which is also included under the term ED, without making assumptions as to cause and effect.

1 Department of Companion Animal Sciences, Faculty of Veterinary Medicine, Utrecht University, PO box 80.154, NL-3508 TD Utrecht, The Netherlands.

2 Justus-Liebig- Universität Giessen, Klinik für Kleintiere-Chirurgie, Frankfurterstrasse 108, D-35392 Giessen, Germany.

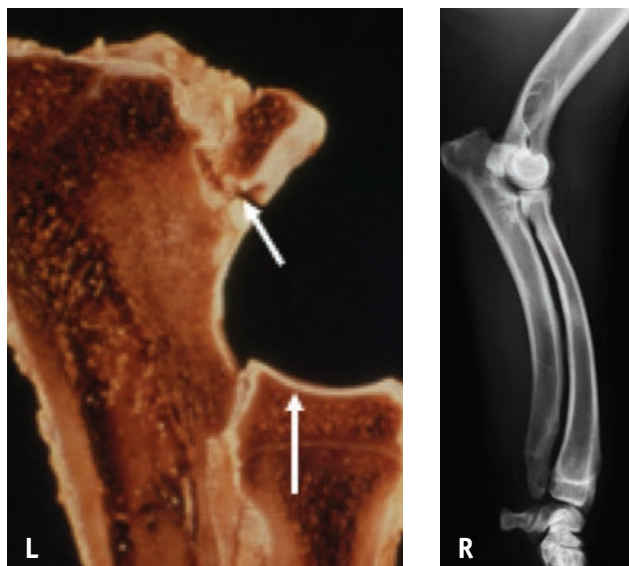
\* Corresponding author: Prof. Dr. H.A.W. Hazewinkel, DVM, PhD, Dipl. ECVS & ECVCN,

E-mail: H.A.W.Hazewinkel@uu.nl



*Fig. 1 Medial view of two elbow joints (A: normal, B: Bernese Mountain dog of 12 months of age with elbow dysplasia). The right specimen demonstrates roughening at the borders of the joint, at the tip of the anconeal process, and at the cranial tip of the radial head (due to osteophytes). While the normal joint (A) shows a smooth transition from radius to ulna in the weight bearing area, in the abnormal joint a step formation between radius and ulna reflects the relative shortage of the radius. The increased weight-bearing of the tip of the medial coronoid that is a consequence of this, may have been the cause of the apical fracture of the coronoid; i.e. fractured coronoid process [FCP] together with joint incongruity [INC]. The radiograph (C) is of a Bernese Mountain dog, 8 months of age with right front leg lameness: there is joint incongruity, irregularities at the dorsal margin of the anconeal process, sclerosis of the subchondral bone and a poor alignment of the medial coronoid can be noticed.*

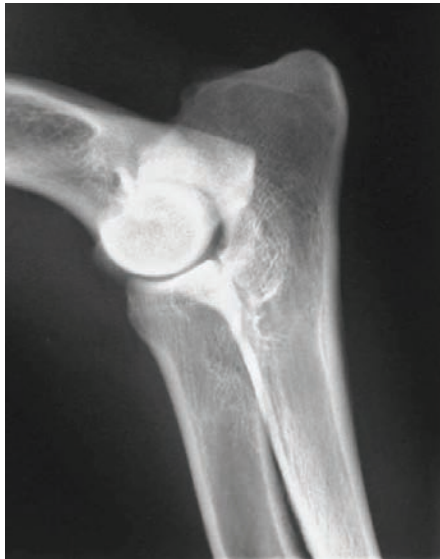FCP and INC<sup>[12]</sup>. In Labradors, the most frequent form of ED is the fragmented medial coronoid process (FMCP), whereas OCD and elbow incongruity are diagnosed less frequently. Ununited anconeal process very seldom occurs in this breed<sup>[10]</sup> but is especially common in German shepherd dogs although only in 4.5% of the cases in a French population (Table 1).



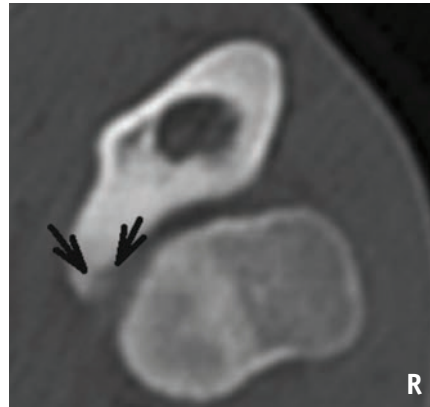
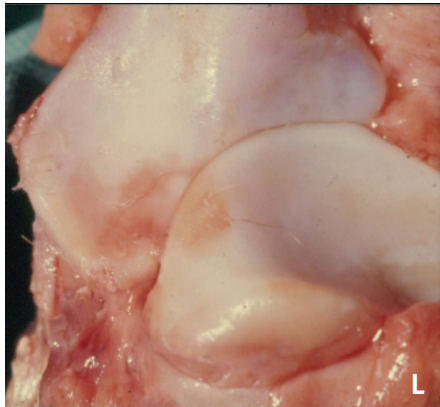
*Fig. 2 : (Left) German shepherd dog 4-months of age: due to a relatively too-long radius, the humeral condyle is pressed against the anconeal process (which is connected with a cartilaginous layer to the olecranon in selected breeds until the age of 5½ months), allowing the anconeal process to become separated from its attachment (oblique arrow], i.e. ununited anconeal process (UAP).*

*(Right) The radiograph shows the mediolateral view of an antebrachium of an 8-month old Jack Russell Terrier with severe front leg lameness: notice the elbow incongruity with pressure of the radius against the humeral condyle, and as a consequence a pressure point between humerus and the completely attached anconeal process: i.e. distractio cubiti.*

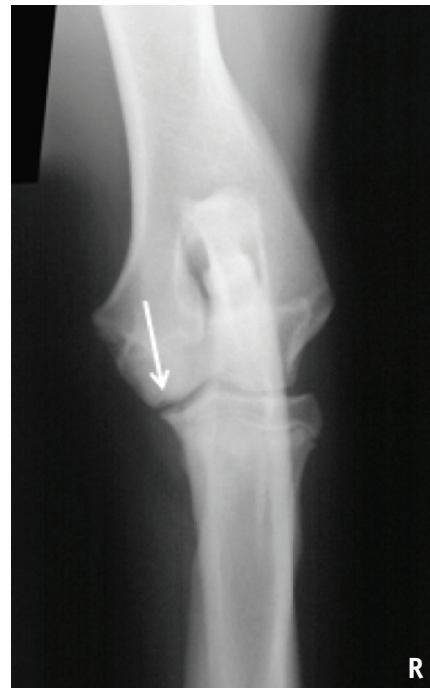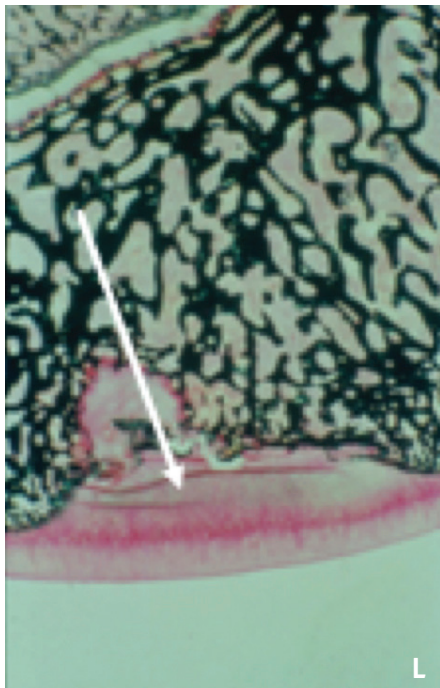




*Fig 3 An elliptical semilunar notch of the ulna is surrounding the humeral condyle. The pressure points at the proximal and distal sites of the trochlear notch are held responsible for the combined UAP and FCP as can occur in dogs, especially German Shepherds*



*Fig. 4: (left) Right elbow joint of a 10 months old Labrador. The red line in the medial coronoid process represents a fracture line in the joint cartilage and in the subchondral bone (MCD). (Right) The CT scan demonstrates the irregular radio-ulnar joint space and the fragmentation of the coronoid process (arrows), i.e. fragmented coronoid process.*



*Fig 5. Left: Thickening of the cartilage at the joint surface responsible for proportional growth of the epiphysis reveals focal thickening: due to disturbance of the process of endochondral ossification cartilage is not transformed into bone. This can be visualized on AP and APMO views of the elbow joint (right) as an indentation of the contour at the medial side of the humeral condyle. NB Erosion of this cartilage (due to contact with a fragmented coronoid process – the so-called “kissing lesion”) during an early stage of growth, will prevent correct development of bone focally, causing a similar kind of indentation. The indentation (either due to OC or OCD, or due to cartilage erosion) at this location is therefore registered as an “OCD-like lesion” (at location ‘h’ on the radiograph in Fig.8)*

Table 1 Primary lesions and correlation with degree of OA in 154 dysplastic elbow joints of German Shepherd dogs

			Importance of osteoarthritic lesions		
			MILD OA	MODERATE OA	SEVERE OA
% (Number) dysplastic elbows	INC alone	42.8% (66)	100% (66)	0	0
	INC associated with other lesion(s)	42.2% (65)	44.6% (29)	52.3% (35)	3.1% (2)
	FCP D	19.5%	20% (6)	76.6% (23)	3.4% (1)
	FCP S	30.4%	78.7% (37)	19.1% (9)	2.2% (1)
	MCPD alone	11% (17)	88.2% (15)	11.8% (2)	0
	MCPD associated	38.9% (60)	46.6% (26)	50% (30)	3.4% (2)
	OCD alone	1.2% (2)	100% (2)	0	0
	OCD associated	5.8% (9)	22.2% (2)	66.7% (6)	11.1% (1)
	UAP alone	2.6% (4)	25% (1)	50% (2)	25% (1)
	UAP associated	1.9% (3)	0	100% (3)	0
	only one primary lesion	57.8% (89)	94.4% (84)	4.5% (4)	1.1% (1)
	more than one primary lesion	42.2% (65)	44.6% (29)	52.3% (34)	3.1% (2)

INC = incongruity, FCP D = Fragmented Coronoid Process diagnosed, FCP S = Fragmented Coronoid Process suspected, MCPD = Medial Coronoid Process Disease, OCD = Osteochondrosis, UAP = Ununited Anconeal Process, OA = Osteoarthritis  
(Adapted from: Elbow dysplasia in German Shepherds. D. Remy, P. Maitre, C Carozzo, E Viguier, D. Fau, JP. Genevois IEWG proceedings 2008 Dublin pp. 29-30.)

## Imaging techniques

### Radiography

Radiographs play a major role in the diagnosis of ED in a clinical setting, to determine the phenotype in cases of (DNA-) research, and in screening the population. "More views will give more insight" holds true in most cases of radiological investigation, especially in cases where it is important to diagnose the primary lesion. The results of a large study in 447 Bernese Mountain Dogs by Lang et al (1998)<sup>[12]</sup> showed that 12% had a primary form of ED with as yet no OA. Therefore, screening for ED in Bernese Mountain dogs should include at least two orthogonal views. This is especially true in breeds where OCD is anticipated to be the primary cause of ED (table 1). In cases where the secondary signs only are of importance, a limited number of views can be sufficient. In a recent article on screening elbow dysplasia in Labrador retrievers originating from the Nordic countries, the sensitivity of registration of the specific signs of coronoid disease (i.e. blurring of the cranial border of the MCP and subtrochlear sclerosis) was 79% when only ML 45 degree flexion views were used. The inclusion of a craniocaudal oblique view increases the specificity of

the diagnosis, and it therefore recommended that it be included in the screening protocol.

In addition to the ML and AP views, other views have been developed including a ML view with 15 degree supination (exo-rotation) of the antebrachium<sup>[14]</sup>, and a distomedial-proximolateral oblique view<sup>[15]</sup>.

### Arthroscopy

With arthroscopy a sensitivity of 94% and a specificity of 82% has been recorded<sup>[16]</sup> and thus this has a higher diagnostic value than radiography or CT, because it enables the clinician to visualise cartilage lesions. However, due to its invasive nature and to the fact that damage to the joint cartilage can occur, and also that one's vision can be obscured by synovial villi and haemorrhages, arthroscopy does not have a place in the screening process of a population.

Striking differences were revealed in these two age groups: less fragmentation visible, with more chondromalacia as revealed during arthroscopy, and an absence of sclerosis in the ulnar subtrochlear area in the > 12 months of age group, and thus as a consequence a lower sensitivity to detect MCD with CT or with plain radiography plus CT. (Table 2)

*Table 2 CT findings in Labradors with front leg lameness where the first clinical signs were at the age of either  $\leq$  or  $> 12$  months of age [Lau et al, 2013]*

	<b>Group I : 16 Labradors,  <math>\leq 12</math> months at onset, 11 males, 5 females</b>	<b>Group II: 15 Labradors  <math>&gt; 12</math> months at onset ,9 males, 6 females</b>
Fragmentation of MCP	93.8%	66.7%
Change in contour of MCP	6.2%	6.7%
Osteophytosis	75%	60.0%
Sclerosis	56.2%	absent
Cyst-like lesions	56.2%	26.7%
OCD-like lesions	50.0%	26.7%
Sensitivity of CT [based on fragmentation of MCP]	93.8%	66.7%
Based on radiological and CT findings Detection sensitivity of MCD	100%	80%

**Computed tomography** (for site of a-h see Fig 8)  
Computed tomography (CT) has a high accuracy (86.7%), sensitivity (88.2%), and negative predictive value (84.6%) for screening of medial coronoid disease. Coronoid disease incorporates fragmentation of a mineralised part of the MCP as well as chondromalacia of the MCP. Neither radiographs nor CT can be used to assess cartilage integrity, when that is the only pathology in the joint. In a recent comparative study, plain radiographs, CT and arthroscopy were undertaken in 31 Labradors (16 dogs  $\leq 12$  months of age at first onset (group I), and 15 dogs  $> 12$  months of age at first onset (group

II) - all with front leg lameness. Group I showed blurring of the cranial edge (site "c") in 75.0% of the cases, ulnar sclerosis (site "e") in 87.6% of the cases, and osteophytosis (most commonly at site "g" and site "a"). On CT however, in 93.8% of the cases a fragmentation of the coronoid process could be detected, which could be confirmed as a displaced fragment by arthroscopy in 68.8% of the cases in group I. Dogs which showed the first signs when older age (mean age  $51.6 \pm 26.4$  months of age with a duration of lameness of  $5.9 \pm 3.5$  months) had the blunt cranial edge of the coronoid ("c" site) as the most common finding (66.7%), together with mild-obvious sclerosis ("e" site) in 53.3% and only 40% of the affected elbows of dogs of group II showed evidence of periarticular osteophytosis (especially site "g" and site "b"). Only 46.7% revealed radiographically detectable fragmentation of the MCP. Sensitivity of radiography in detecting MCD was 93.8% in group II dogs and for CT this was 66.7%. Combining primary and secondary (i.e. signs of OA) taken together, the sensitivity of radiology in detecting MCD was 93.8% in group I, and 73.3% in dogs of group II.<sup>[17]</sup>

## Incidence of elbow dysplasia

### The prevalence of ED differs significantly between dog breeds (table 3)

The disease is known to be heritable in many dog breeds ( $h^2 = 0.25$  to  $0.28$ )[17] and a breeding programme to control it has been successful in Rottweilers and Bernese Mountain dogs<sup>[19]</sup>. Also, in The Netherlands, the incidence of elbow dysplasia (regarding FCP and INC) in a selective cohort of Bernese Mountain dogs of 12-14 months of age decreased from 64%. of animals assessed in 1992 to 45% in 1995. In the Scandinavian countries, United Kingdom

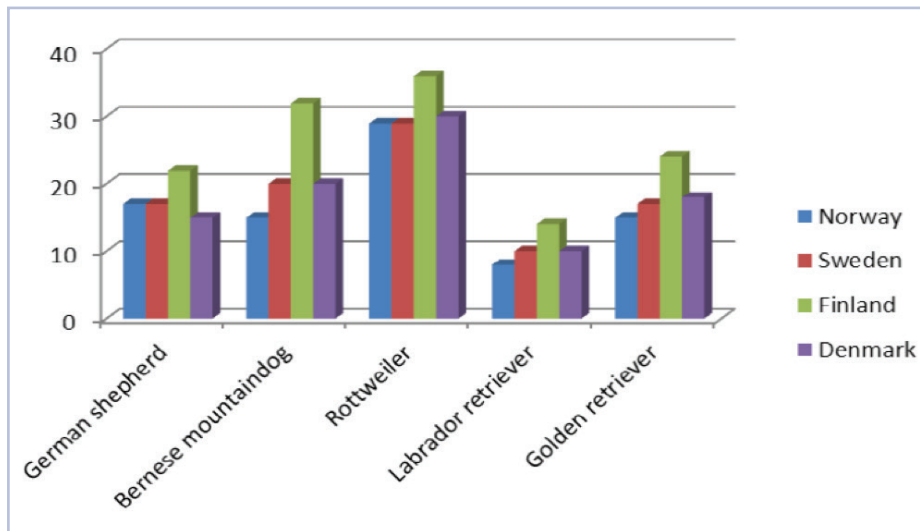
*Table 3. Breed specific prevalence (in %) of Elbow Dysplasia*

	<b>Belgium<sup>1</sup></b>	<b>%</b>	<b>USA<sup>2</sup></b>	<b>%</b>	<b>Germany<sup>3</sup></b>	<b>%</b>
Bernese Mountain dogs	266	20	11,685	28.3		
Labrador	227	13	59,832	10.7	6,038	10.2
Golden Retriever	126	18	28,923	11.0	4,986	13.6
German Shepherd dog	130	12	32,937	19.1	20,961	16.0
Rottweiler	135	33	14,172	39.7	1,592	32.3
German Shepherd dog	130	12	32,937	19.1	20,961	16.0
Rottweiler	135	33	14,172	39.7	1,592	

<sup>1</sup> Coopmans et al., 2008 Incidence in Belgium in the period 2002-2006[22]

<sup>2</sup> Orthopedic Foundation for Animal [OFA] period January 1974- December 2011[23]

<sup>3</sup> Germany Period 2009 – 2012 [Communication Dr B. Tellhelm]



*Fig 6 Acknowledgement for this figure to Dr. H.K. Skogmo Elbow screening in the Nordic countries - past, present and future. Proceedings IEWG 2012<sup>[24]</sup>*

and in the USA, dogs are only diagnosed with the disease if they are deemed positive on account of secondary lesions<sup>[21]</sup>, whereas in Germany, the Netherlands, Switzerland, Belgium and France, dogs with a primary defect (but still no signs of OA) may also be diagnosed with the disease.

All the Nordic countries have a relatively similar percentage of dogs with radiographical ED diagnosis. Figure 6 shows the percentage of dogs within these five breeds with positive ED diagnosis on screening radiographs in 2011<sup>[24]</sup>.

## Screening organisation for ED

More than 25 years ago, in Davis (CA, USA) an International Elbow Working Group was founded by veterinarians and breeders with the intention of investigating and combating elbow dysplasia. Fifteen years ago a screening scheme was introduced which is available on the internet and is in use in many countries. Only a few conditions are prescribed by IEWG for screening, these are:

- (1) The dog should be mature (minimum 12 months of age)
- (2) It should be properly identified.
- (3) At least one radiograph (mediolateral flexed view) of good quality has to be available for judging.

These simple conditions encourage as many owners and breeder clubs of breeds at risk to participate.

In The Netherlands, ED-screening is organised by the Dutch Kennel Club, which requires four views in selected breeds (including Labrador and Golden Retriever) and two views for other breeds where ED does not form a selection criteria for breeding. The four views include:

the 90° flexed mediolateral, the extended mediolateral, the craniocaudal, and the craniolateral-caudomedial radiographic views of both elbows taken using the technique previously described<sup>[25]</sup>.

In Germany, ED-Screening is organised by the breed club responsible for each breed under the umbrella of the "Verein für das Deutsche Hundewesen – (VDH)". The standard views are the 40° to 70° flexed mediolateral and the craniolateral-caudomedial radiographic views of both elbows. In German Shepherd dogs only the 40° to 70° flexed mediolateral view is obligatory because OCD is a rare problem in this breed and the mediolateral view is most important for the diagnosis of MCD.

In the UK the ED- grading scheme is based on that of IEWG: Grade 0 = normal; Grade 1 = osteophytes at any site ≤2mm; Grade 2 = osteophytes 2-5mm OR a primary lesion [OCD, FCP, UAP] with no osteophytes; Grade 3 = osteophytes >5mm OR a primary lesion [OCD, FCP, UAP] with osteophytes. However, in the UK-grading scheme joint incongruity and sclerosis are not graded as lesions, as these warrant high quality radiographs and is considered as too subjective and dependent on image quality. There is no borderline grade: there would probably be significant owner discontent at a grade requiring repeat radiography due to the requirement for chemical restraint for elbow radiography (cost and perceived risk to patient). Therefore only two ML views are included in the judging.<sup>[21]</sup>

The Scandinavian countries started scoring for ED in the early 1980s prior to the foundation of the IEWG. Based on the assumption that degenerative changes are

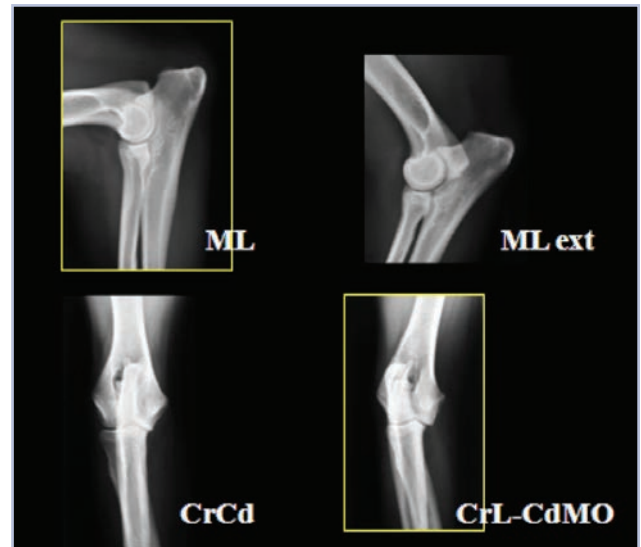

readily visible at the age of screening <sup>[26,27]</sup> the Nordic classification is based on the degree of OA, while of the primary lesions only UAP is recorded. Breeding is not recommended from dogs graded 2 or 3.

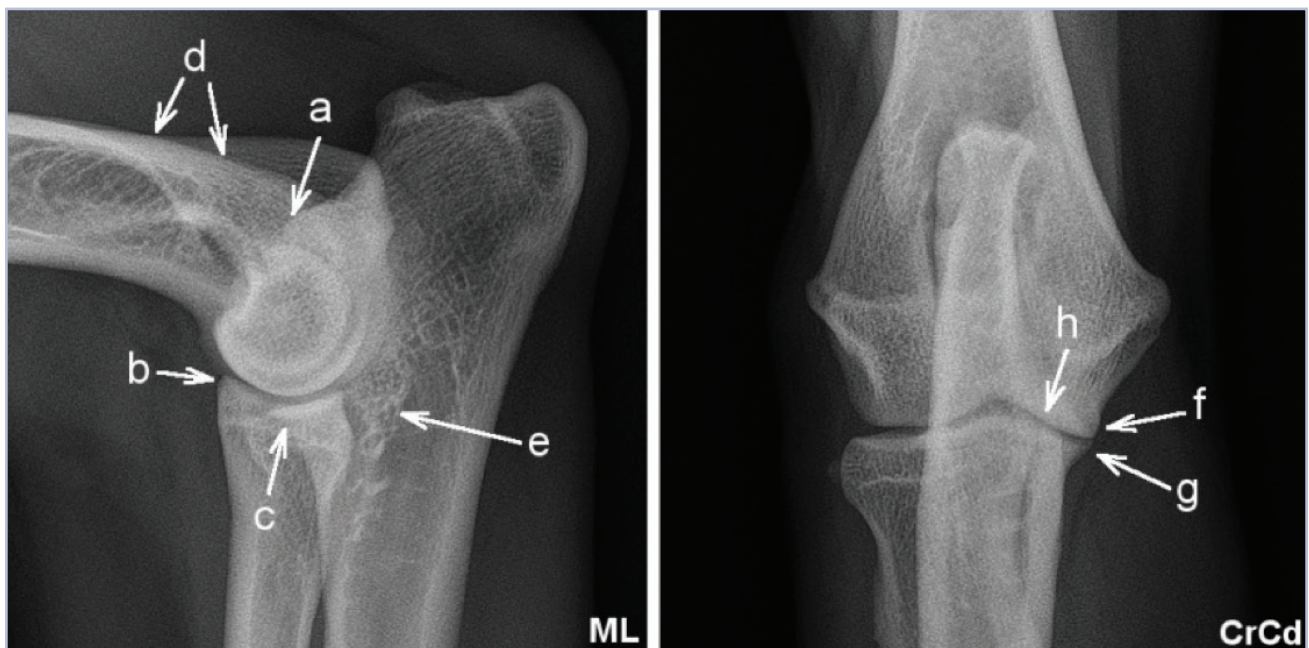
Depending on the organisation of the responsible Kennel Club, one or more scrutinisers, together or in sequence judge the views for abnormalities, i.e. primary entities and/or OA are scored.

## Method of screening for ED

For OA, the height of the osteophytes are estimated and graded as follows: 0 (no OA), 1 (<2 mm), 2 (2-5 mm), or 3 (>5 mm) at sites a, b, d, f and g as described by the IEWG (Fig. 8). Sclerosis is assessed at the trochlear notch at the base of the coronoid process (site e). The presence of indentation in the medial part of the humeral condyle is recorded (site h) (Fig. 5). Site c is an important criterion to be included in the final decision. The primary diseases are categorised and coded as: absent (0), suspect (1), or present (2) for UAP, OC(-like lesion), FCP, and INC. In the category 'suspect', the primary disease causing ED is not explicitly visible, but its presence is suspected based on secondary changes <sup>[28]</sup>.



*Fig. 7 Different views in use for ED screening*  
 ML = mediolateral view with 90-degree flexed elbow. ML ext = Mediolateral view with a normal extended elbow joint, CrCd = craniocaudal view or dorsoventral view with the olecranon projected in the middle of the elbow joint. CrL-CdMO = Craniolateral to caudomedial oblique where at this projection, the olecranon touches the lateral cortex of the humerus. In selected cases or as part of the legislation of screening authorities it may be decided to limit the amount of views to just one (ML) or two (ML and CrL-CdMO or CrCd)



*Fig. 8. Anatomical places of interest which are used to score for the grade of OA (a,b,d,f,g), for the outline of the medial coronoid process(c), the presence of sclerosis (e) and/or of an indentation in the subchondral bone (h). a = dorsal margin of the anconeal process; b = tip of the radial head, c = contour and contrast of medial coronoid process, d = contour medial humeral condyle, e = intramedullary cavity just caudal to the coronoid region; f = medial margin of humeral condyle; g = medial tip of the ulna; h = subchondral bone of medial area of humeral condyle (Acknowledgement to Dr Lau)*

In a few dogs a radiopaque margin on top of the anconeal process can be seen. This is not osteophytosis and should therefore not be considered as a first sign of OA, especially not when there are no other indications of joint pathology<sup>[29]</sup>

## Radiograph evaluation for ED screening

The diagnosis of canine elbow dysplasia (ED) in screening programmes is based on the evaluation of radiographs according to the protocol of the International Elbow Working Group (IEWG). The most recent update of this protocol is available on the IEWG web site [<http://www.vet-iewg.org/joomla>]. A mediolateral flexed projection of each elbow joint is mandatory for interpretation and an additional craniocaudal or oblique view is highly recommended (Fig. 8). Although sedation may help with positioning the animal during the taking of radiographs, there is no obligation for sedation during this procedure.

The IEWG protocol registers signs of joint disease and the presence of the major forms of primary lesions (FCP, OCD, UAP, Incongruity). The films are evaluated in a two-stage process: a) to assess the degree of secondary joint disease (OA, sclerosis, indentation, alignment of bony contour) and b) to check for signs of a primary lesion. Any other abnormal finding should also be reported including avulsion and abnormal mineralisation.

### OA score (a, b, d, f, and/or g in Fig. 8)

The status of the elbow joint regarding secondary joint disease [OA] is scored as either

Grade 0: normal

Grade 1: mild; osteophytes less than 2 mm high anywhere in the joint (see Fig. 8),

Grade 2: moderate, osteophytes 2 – 5 mm high

Grade 3: severe, osteophytes higher than 5 mm.

**Point c (fig 8):** Grade 0 = normal; Grade 1 = blurring, and deformed cranial edge of the medial coronoid process (MCP), a reduced opacity of its tip, an increased opacity of the ulnar notch at the level of the coronoid process.

**Point e (fig.8):** An increased subchondral bony opacity (sclerosis) in distal part of semilunar notch, and loss of trabecular pattern.

In addition the ML radiograph should be assessed for a step between radius and ulna and/or an uneven or increased joint space width between humerus and radius

The Cranio-caudal view should be assessed for:

**Points f & g (fig.8):** New bone formation on the medial articular border of humerus and ulna, **Point h (fig. 8):** a subchondral bone defect in the medial humeral condyle (OCD or contact lesion) with or without subchondral sclerosis is seen, but a bony flap is rare.

In addition on the Cr-Cd view there may be a step between radial and ulnar subchondral bone plate, particularly medially, or that the humeroradial joint space is wider medially than laterally, (the latter especially in Bernese Mountain dogs)<sup>[30]</sup>

## ED-scoring

The grading in size of the osteophytes is very much influenced by the age of the dog and the type of dysplastic entity, and is therefore not the only criterion which determines the final ED-score. However, the OA-score (grade 0-3) is included in the scoring and the certificate is completed with a numerical grade 0-3 for each elbow, with the overall grade being the higher of the two.

To arrive at a final ED score, the primary signs are scored, whether absent, suspect present (i.e. indirect signs are present to make the elbow suspect for the primary

*Table 4: Explanation of scoring for Elbow Dysplasia (ED) where radiographic findings regarding osteoarthritis score (1-3 OA) and primary scores (UAP, FCP (or MCD), OCD and INC), suspect or evident, are integrated<sup>[31]</sup>*

Elbow Dysplasia Scoring		Radiographic Findings
ED 0 =	Normal elbow joint	Normal elbow joint, no evidence of incongruity, sclerosis or arthrosis
ED 1 =	Mild arthrosis (grade 1 OA)	Presence of osteophytes < 2 mm high, sclerosis of the base of the coronoid processes - trabecular pattern still visible
ED 2 =	Moderate arthrosis [grade 2 OA] or suspect primary lesion	Presence of osteophytes of 2 - 5 mm high Obvious sclerosis [no trabecular pattern] of the base of the coronoid processes Step of 3-5 mm between radius and ulna (INC) Indirect signs for a primary lesion (UAP, FCP/ Medial Coronoid Disease, OCD)
ED 3 =	Severe arthrosis [grade 3 OA] or evident primary lesion	Presence of osteophytes of > 5 mm high Step of > 5 mm between radius and ulna [obvious INC] Obvious presence of a primary lesion [UAP, FCP, OCD]

disease), or obviously present, according to the criteria as given in Table 4.<sup>[31]</sup>

### Explanation of wording in the ED scoring scheme in Table 4

Sclerosis is the loss of trabecular structure, just caudal to the coronoid area, due to local bone formation inside the ulnar medullary cavity. Since this finding is very well linked with medial coronoid disease, especially in dogs which start to show a problem at an early age (Table 2), it is considered as an important radiological finding. Although attempts have been made, so far no objective criteria have been developed to differentiate between normal, light and obvious changes and the grading of the sclerosis is dependent on the experience of the scrutineer(s).

Indirect signs of primary lesions include blunt alignment of the cranial edge of the medial coronoid process and/or a reduced opacity of its tip, an increased opacity of the ulnar notch at the level of the coronoid processes, an increased and/or incongruent joint space between humerus and radius (site "c"), and slight indentation of the medial site of the humeral condyle (site "h"). (Fig 5 arrow)

A dark area, coinciding with the original line of cartilage that separated the anconeal process from the ulna, is not considered to be a moderate sign, but separately registered as an incomplete UAP, (Fig 2 left) often with (minimal or) no OA. It is therefore scored as a ED grade 2.

Obvious sign of UAP is a total separation of the AP, obvious sign of FCP is a separated bony particle displaced from its origin, obvious OCD is a mineralised cartilage flap covering the indentation.

However, it is important for proper interpretation of the radiographs to realise that even minimal changes are usually pathognomonic for FCP and therefore would qualify an elbow for at least an ED grade 2 (moderate ED, Coronoid disease/ FCP indicated ) according to the current IEWG protocol, regardless of the height of osteophytic new bone formation. The degree of OA is quite variable and some dogs may not show any new bone formation at all (Fig 4b)<sup>[17,32,33]</sup>. If grading was based on the size of the osteophytes only, elbows with FCP would be underscored and may (erroneously) even be considered free of ED<sup>[31]</sup>

Table 5 illustrates that both in Rottweilers and Labradors (as an example) the prevalence of OA in the elbow joints of the offspring is seen twice as much when two ED-affected parents are mated rather than two non-affected

*Table 5 Breeding results of ED-unaffected screened Labradors and Rottweilers in the Swedish population(2003)*

	Screened amount of dogs	Prevalence of ED
Unaffected x Unaffected Rottweilers	6,153	30%
Unaffected x Unaffected Labradors	11,550	11%
Unaffected x Arthrosis Rottweilers	3,163	46%
Unaffected x Arthrosis Labradors	703	19%
Arthrosis x Arthrosis Rottweilers	567	60%
Arthrosis x Arthrosis Labradors	25	32%

*Hedhammar A, Genetic aspects of ED and efficacy of breeding programs at: IEWG meeting, Dublin 2008 [proceedings pp. <sup>[24-25]</sup>*

parents. Due to a variety of reasons (including the limited sensitivity of the screening method, the polygenetic nature of ED, environmental influences) the prevalence of OA in the offspring of two unaffected parents is not reduced to 0%.<sup>[34]</sup>

Little difference is seen in the degree of OA in the positive offspring, illustrating the fact that the degree of OA is more a reflection of age, activity, body condition score and other environmental factors, rather than the degree or specific condition causing the OA (Table 6)

### The role of CT in the screening procedure

The accuracy (86.7%), sensitivity (88.2%) and negative predictive value (84.6%) for medial coronoid disease with CT is higher than with other non-invasive investigation techniques<sup>[36]</sup>, although as with standard radiography, CT is insensitive for abnormalities in joint cartilage alone (i.e. chondromalacia) and therefore cases are sometimes missed. Chondromalacia is especially found in older dogs with sudden elbow lameness, and can readily be diagnosed by palpation during arthroscopy or open arthrotomy<sup>[17]</sup>. CT-scanning allows for inspection of the radioulnar joint and the alignment of the medial coronoid process without superimposition of other bony structures. Fragmentation of the coronoid process, especially when displaced, can be recognised with CT scanning<sup>[36]</sup>. The presence of intramedullary ossification in the ulna just caudal to the coronoid process (i.e. "sclerosis") can also be identified and even quantified and OCD lesions can be identified.<sup>[16,17,37,42]</sup> Incongruity of the elbow joint can be recognized from the widened joint space of the humero-ulnar, humero-radial, and radio-ulnar joint space, or the elliptic shape of the trochlear notch can be seen (Fig. 3). All these bones fit perfectly in normal joints<sup>[42]</sup> In addition to fragmentation of the apex of

Table 6 Progeny results of matings between parents with known elbow scores

Sire rating	Dam rating				Total
	Normal (1)	Grade I (2)	Grade II (3)	Grade III (4)	
<b>Normal (1)</b>					
Dysplastic (%)	10.1	24.1	29.4	28.1	
Total	55,867	4,309	875	167	61,218
<b>Grade I (2)</b>					
Dysplastic (%)	22.0	41.0	46.9	52.2	
Total	3,917	591	145	23	4,676
<b>Grade II (3)</b>					
Dysplastic (%)	32.6	55.4	65.8	57.1	
Total	1,121	222	38	14	1,395
<b>Grade III (4)</b>					
Dysplastic (%)	23.9	38.1	14.3	0.0	
Total	251	42	14	3	310
<b>Total</b>	<b>61,156</b>	<b>5,164</b>	<b>1,072</b>	<b>207</b>	<b>67,599</b>

Acknowledgement: How the OFA is tackling inherited disorders in the USA: using hip and elbow dysplasia as examples GG Keller, E. Dzuik, JS Bell. *The Vet J* 189:197-2-2; 2011<sup>[35]</sup>

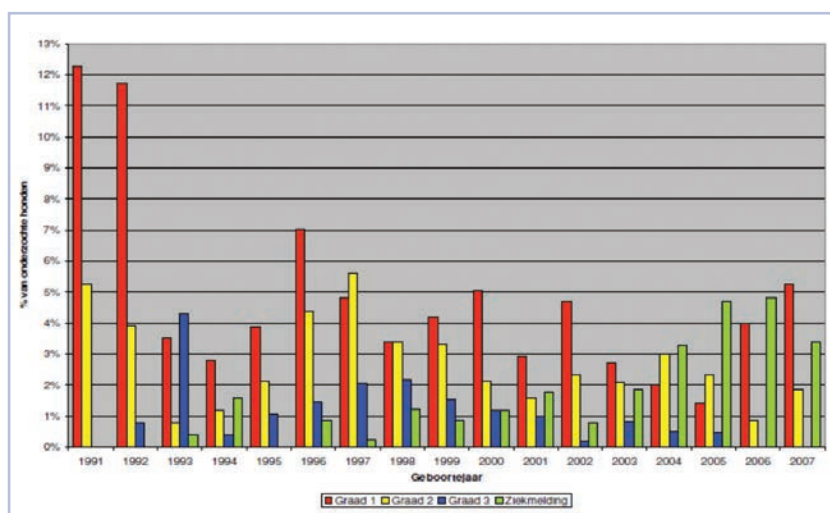


Table 7: Incidence of OA grade I,II,III in birth groups of Labradors in The Netherlands based on screening results (Red=grade I, yellow=grade II blue=grade III) or reported to be affected (green): gradual decrease of more severe cases were registered during screening, however an increasing amount of dogs were reported as surgically treated for ED. This illustrates that it is of paramount importance to identify all cases, whether the animal was treated, non-treated, or if euthanasia was performed, to get a proper impression of the progress made.

the medial coronoid pseudocystic lesions at the radio-ulnar transition were seen in 78% and 97% of the cases, respectively, in severely incongruent joints <sup>[3]</sup>.

Because of these advantages, CT-scanning is frequently used where CT equipment and personnel are available. In Germany, CT scanning is commonly used in screening procedures<sup>[31]</sup>. This is especially the case where an owner appeals against a judgment by the official screening committee. As part of the appeal procedure the owner is obliged to present the results of a CT scan to prove that the elbow joints are free from dysplasia.

It is to be expected that with growing concern amongst breeders in Europe, and with increased availability of CT-equipment in the veterinary field, many more screening officials will offer this possibility to their breeders.

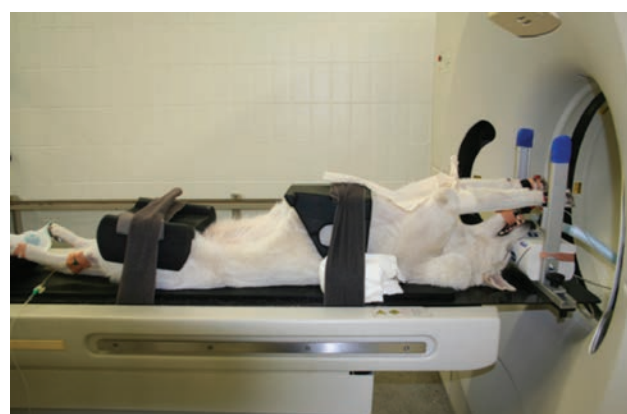

Fig. 9 For CT-screening the dog is anaesthetised and positioned in dorsal recumbency on the scanner table with the forelimbs extended and the antebrachia parallel to each other during scanning procedure (Fig 4 a & b) Transverse views are made perpendicular to the antebrachia in 1 mm thick slices with 120 kV, 120 mA, and 1 sec scanning time. (Acknowledgement Dr S.F. Lau)



## Genetic aspects of ED

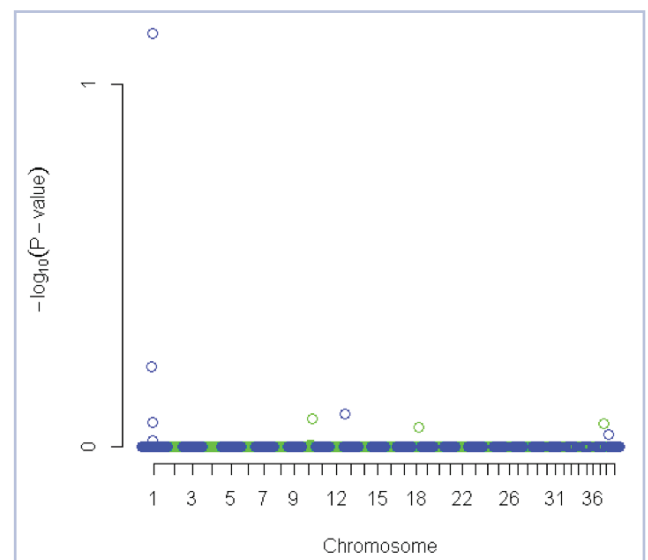
Elbow dysplasia is a disorder of complex etiology with genetic and environmental factors contributing to the disease. The heritability estimate for ED ranges from 0.1-0.77 depending on breed and population [18, 43 - 46]. Specifically for FCP, heritabilities were found of 0.06, 0.17 and 0.24 in Bernese Mountain Dogs, Labrador Retrievers and Golden Retrievers from The Netherlands, respectively [5]. In a cohort of German Shepherd Dogs from Germany, a high heritability of 0.54 for FCP was observed [47]. It should be noted that the heritability expresses the fraction of the phenotypic variance in a population that is determined by genetic factors. It does not express a possible basic genetic susceptibility that may be invariantly high for the population as a whole.

From the genetic studies it has become clear that FCP is a polygenic trait. Using an affected sibling pair approach, 14 collagen candidate genes and the gene for vitamin D receptor could be excluded from involvement in the disorder in Labrador Retrievers [48]. The approach is based on the expectation that affected siblings will have a greater chance to share a gene variant that contributes to the phenotype than the at random 50% allele sharing between siblings. A genome wide scan using the same approach with a limited set of DNA markers indicated the possible involvement of loci on chromosomes 1 and 13 [49]. This approach was abandoned because the number of sib-pairs could not be expanded.

A more straightforward case-controlled comparison was performed in a small cohort of 71 unrelated Labrador retrievers. Thirty of the dogs were affected by FCP which is a small number for this type of study. The DNA of the dogs was genotyped with arrays of 22 000 SNPs evenly spread over the genome. The results showed a large difference between the groups of dogs in a region on chromosome 1 (Figure 10). This result suggested involvement of a gene in the region, but follow up research with larger groups of dogs and a more dense set of SNP markers is needed for confirmation.

## Efficacy of ED screening programmes

The success rate of screening is influenced by the number of dogs which are screened and the penalties breed clubs will impose on breeders who do not offer all their breeding stock for screening. The discipline of owners, breeders and veterinarians not to pre-screen (i.e. unofficial screening) and/or not including the dogs operated on for ED in the register is also important. Breeders will sign in for screening programmes when the consequences of not participating are considered to be more serious than the benefits, the costs, and the trouble of participating. Breeders will quit the programme when they have the impression that the costs and trouble outweighs the success rate of the screening programme for the improvement of the (elbow) quality of their pedigree dogs.



*Fig 10 Genome wide association study of FCP in Labrador Retrievers. The genotypes of 22 000 DNA markers spread evenly over the genome were determined in 31 affecteds and 40 control dogs. The allele frequencies of the DNA markers in the two groups were compared with GenABEL software [50] and corrected for multiple testing by analysis of permutations of the data. The y-axis indicates the level of significance of the difference between affecteds and controls across the genome, indicated by chromosome numbers on the x-axis. Blue circles: results of odd numbered chromosomes, green circles: results of even numbered chromosomes.*

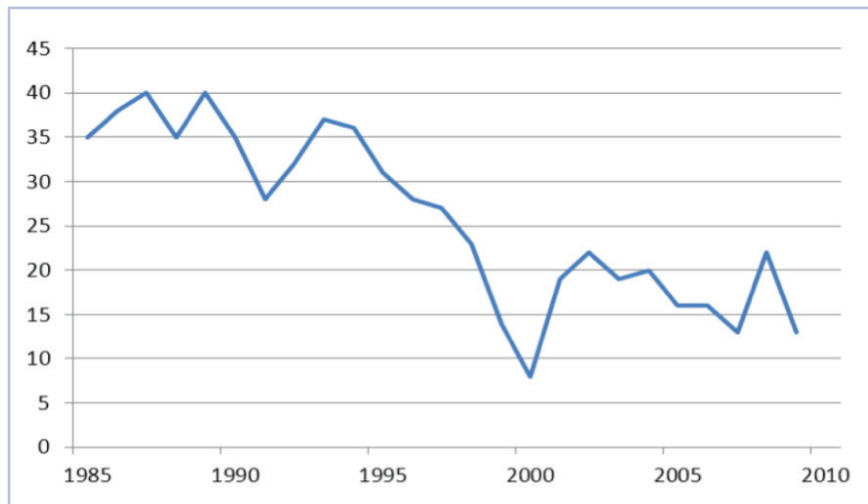


Fig 11: A gradual decrease of the incidence of ED in Bernese Mountain dogs in Norway is depicted during the last 25 years. Acknowledgements: Dr. H.K.Skogmo Elbow screening in the Nordic countries-past, present and future. Proceedings IEWG 2012.<sup>[24]</sup>

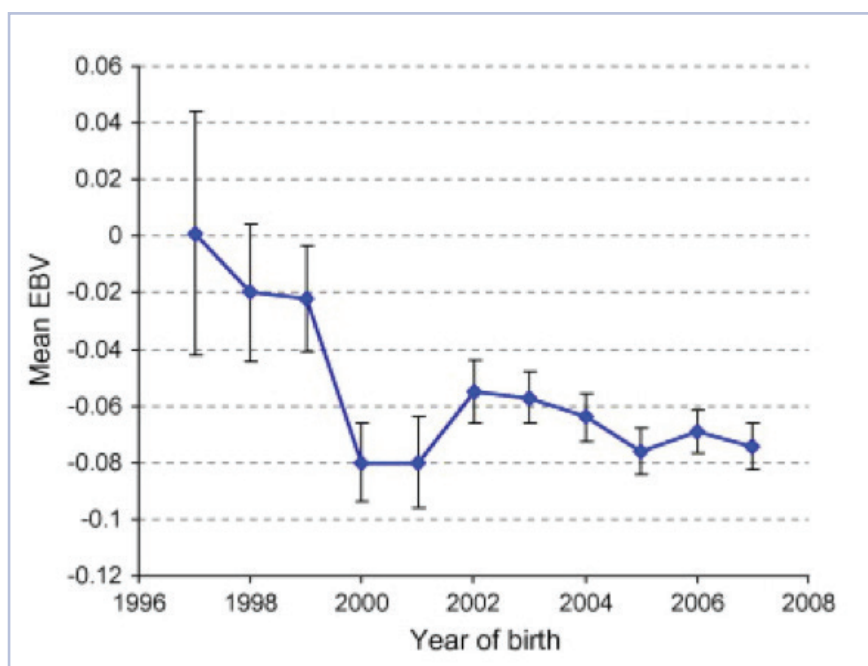


Fig. 12: The means and standard deviations for Estimated Breeding Value for ED in Labradors in the UK (from a univariate analysis) of elbow scores related to the year of birth indicates that some genetic progress was made against elbow dysplasia. [from: Lewis TW, Iliska JJ, Blott SC, Woolliams JA. Genetic evaluation of elbow scores and the relationship with hip scores in UK Labrador retrievers. Vet J 189; 227-233: 2011]<sup>[51]</sup>

	Number of dogs Screened	Prevalence of ED
1985 Rottweilers	339	59%
1987 Rottweilers	747	48%
1990 Labradors	1269	15%
1995 Rottweilers	868	41%
1995 Labradors	1306	14%
2002 Rottweilers	817	28%
2002 Labradors	1357	9%

Table 8: The prevalence of elbow dysplasia in Swedish Rottweiler and Labrador populations. This table illustrates the gradual decrease of incidence of elbow dysplasia which could be reached by a variety of measures directed at responsible breeding with dogs without signs of OA of the elbow joint. In addition it warrants a good organisation for screening, skilled screeners, high quality radiographs, strict legislation by the breed clubs (including an appeal and punishment procedure), whereas assurance companies paying the costs and a legal system which keeps the breeders responsible for caused damage helps to support the screening system.

Acknowledgement: Prof A. Hedhammar, Genetic aspects of ED and efficacy of breeding programs at: IEWG meeting, Dublin 2008 [proceedings pp. 24-25]<sup>[52]</sup>

As mentioned above, the IEWG scoring system is a two-step procedure, a) assessing the degree of arthrosis and b) registering any signs indicative of a primary form of ED. It is important to bear in mind that various countries in Europe and overseas only rely on step a). Both concepts have proven to be useful in reducing ED in a population. However, problems arise when dogs are to be used for breeding in countries with differing scoring systems. In such a case it is advisable to re-score the dog again, according to the local scoring mode. It will be the aim of the IEWG to harmonise the scoring systems in the future.

The Certificate in use for reporting the screening for elbow dysplasia is shown in Fig. 13 The form includes different sections, for identification of the dog, the owner, the practitioner who made the radiological films (including when and which views), the screening officials, and the screening results both for secondary arthrosis (OA) and for primary lesions (UAP, FCP, OC, INC, respectively). The use of the form will facilitate international transparent communication about the way the dog was examined and thus the certainty of the final score.

**IEWG or WSAVA** Certificate of radiological Elbow Dysplasia examination  
Examination based on International Elbow Working Group Standards

Logo Kennel Club  
Archive and Registration for Great Britain  
Etc..Etc..

Registration .nr. Examination  
**ED-GB**  
National reg.veterinarian reg.nr. examiner

**Animal**  
Name \_\_\_\_\_  
Breed \_\_\_\_\_  
Registration nr \_\_\_\_\_  
Microchip nr \_\_\_\_\_  
Date of birth day month year Sex ☐ F (female intact) ☐ Fs (female spayed) ☐ M (male intact) ☐ Mc (male castrated)  
Tattoo \_\_\_\_\_

**Owner/agent**  
Name \_\_\_\_\_  
Address \_\_\_\_\_  
Country, Zip \_\_\_\_\_ Town \_\_\_\_\_  
The undersigned agrees to the WSAVA/IEWG examination protocol, the rules of the national scheme and confirms that the dog submitted for examination is the one described above. Signature also means that the results are available for official publication.  
Signature owner / agent \_\_\_\_\_

**Examination (veterinarian, age of dog, radiologic views)**  
**Veterinarian**  
Name \_\_\_\_\_  
Address \_\_\_\_\_  
Country, Zip \_\_\_\_\_ Town \_\_\_\_\_  
**Identification of dog**  
Check tattoo ☐ Correct ☐ Partly/unreadable ☐ Incorrect ☐ Absent  
Check microchip ☐ Correct ☐ Incorrect ☐ Absent  
**Radiologic examination**  
Date radiologic examination day month year Age Year Months  
Number of radiographs per elbow 1 2 3 4 5  
Radiologic projections ☐ ML-flexed (Medio-Lateral 45°-flexed) ☐ CC (Cranio-caudal) ☐ CC-15° pronated (Cranio-caudal-15°pronated)  
☐ ML-neutral (Medio-Lateral 90°-ext.) ☐ ML-extended (Medio-Lateral >120°ext.) ☐ Other: (specify) \_\_\_\_\_  
The undersigned agrees that the examination is performed according to protocols of the WSAVA (World Small Animal Veterinary Association) and her affiliate, IEWG (International Elbow Working Group).  
Furthermore the undersigned states that the dog, submitted for IEWG-elbow-examination is the above mentioned dog. The results will be registered and archived by the National Kennel Club  
Signature veterinarian \_\_\_\_\_

**Results evaluation by National ED-panel**  
**Veterinarian**  
Name \_\_\_\_\_  
Address \_\_\_\_\_  
Country, Zip \_\_\_\_\_ Town \_\_\_\_\_  
**Radiographic evaluation**  
Date panel evaluation day month year  
**Primary lesion**  
Left elbow UAP FCP OC INC Other ☐ Affected ☐ Suspected ☐ Free (this definite proof of a primary lesion) ☐ Grade 0 (no signs of secondary arthrosis)  
Right elbow UAP FCP OC INC Other ☐ Affected ☐ Suspected ☐ Free (this definite proof of a primary lesion) ☐ Grade 0 (no signs of secondary arthrosis)  
**Secondary arthrosis**  
Borderline ☐  
Grade I ☐  
Grade II ☐  
Grade III ☐  
The undersigned agrees that the radiographic evaluation is performed according to protocols of the WSAVA (World Small Animal Veterinary Association) and her affiliate, IEWG (International Elbow Working Group).  
Signature authorized examiner \_\_\_\_\_

**Interpretation**  
Interpretation based on the current recommendations of the International Elbow Working Group (IEWG), an affiliate of the World Small Animal Veterinary Association (WSAVA)  
**Primary Lesions**  
UAP Unilateral Anconeal Process  
FCP Fragmented Coronoid Process  
OC Osteochondrosis or Osteochondritis dissecans of the medial humeral condyle  
INC Incongruity of more than 2mm between articular surface of Radius and Ulna  
**Other Lesions**  
Avulsion medial humeral epicondyle  
Mineralisation medial collateral ligament/origin flexor muscles  
Other: \_\_\_\_\_  
ED grade, based on the secondary arthrosis  
Grade 0 No signs of arthrosis  
BL Border Line: Undetermined changes  
Grade 1 Osteophyte formation of less than 2 mm anywhere in the elbow joint  
Grade 2 Osteophyte formation of 2-5 mm anywhere in the elbow joint  
Grade 3 Osteophyte formation of more than 5 mm anywhere in the elbow joint  
Note: The classification Grade 0 (or no detected primary lesion) does not imply that the animal is genetically sound. Based on the current scientific knowledge IEWG does not recommend breeding of arthrotic animals or animals displaying a primary lesion.  
Space for sponsors !!!

Fig 13 ED Registration Form

## Acknowledgement

The authors acknowledge Dr. H.C.Kranenburg, Dr.I.C.M. Lavrijsen and Dr. S.F. Lau for their valuable contributions to the manuscript, which were partly reviews in their thesis books.

## References

For proceedings of the IEWG see: <http://www.vet-iewg.org/>

- [1] Michelsen J. Canine elbow dysplasia: aetiopathogenesis and current treatment recommendations. *Vet J.* 2013; 196:12-19
- [2] Breit S, Künzel W, Seiler S. Variation in the ossification process of the anconeal and medial coronoid process of the canine ulna. *Res Vet Sci* 2004;77:9-14.
- [3] Ubbink GJ, Hazewinkel HAW, van de Broek J, Rothuizen J. Familial clustering and risk analysis for fragmented coronoid process and elbow joint incongruity in Bernese Mountain Dogs in The Netherlands - *Am J Vet Res* 1999 ; 60; 1082-1087
- [4] Samoy Y, Gielen I, Van Caelenberg A, van Bree H, Duchateau L, Van Ryssen B.. Computed tomography findings in 32 joints affected with severe elbow incongruity and fragmented medial coronoid process. *Vet Surg* 2012; 41:486-494.
- [5] Lavrijsen IC, Heuven HC, Voorhout G, Meij BP, Theyse LF, Leegwater PA, Hazewinkel HA Phenotypic and genetic evaluation of elbow dysplasia in Dutch Labrador Retrievers, Golden Retrievers, and Bernese Mountain dogs *Vet J.* 2012; 193:486-92.
- [6] Hazewinkel HAW, Goedegebuure SA, Poulos PW and Wolvekamp, WThC. Influences of chronic calcium excess on the skeleton of growing Great Danes. *Journal of the American Animal Hospital Association* 1985; 21, 377-391.
- [7] Tryfonidou MA, Holl MS, Stevenhagen JJ, Buurman CJ, Deluca HF, Oosterlaken-Dijksterhuis MA, van den Brom WE, van Leeuwen JP, Hazewinkel HA. Dietary 135-fold cholecalciferol supplementation severely disturbs the endochondral ossification in growing dogs. *Domest Anim Endocrinol* 2003; 4:265-85.
- [8] Wind A, Packard M. Elbow incongruity and developmental elbow diseases in the dog: Part II. *J.A.A.H.A.* 1986; 22, 725-730.
- [9] Remy D, Neuhart L, Fau D, Genevois JP. Canine elbow dysplasia and primary lesions in German shepherd dogs in France . *J Small Anim Pract* 2004; 45:244-248
- [10] Meyer-Lindenberg A, Fehr M, Nolte I. Co-existence of ununited anconeal process and fragmented medial coronoid process of the ulna in the dog. *J Small Anim Pract.* 2006; 47:61-65.
- [11] Hazewinkel HAW, Kantor A, Meij B, Voorhout G. Fragmented coronoid process and osteochondritis dissecans of the medial humeral condyle. *Tijdschrift voor Diergeneeskunde*, 1988 ;113, 415 -465.
- [12] Samoy Y, Gielen I, Saunders J, van Bree H, Van Ryssen B. Sensitivity and specificity of radiography for detection of elbow incongruity in clinical patients. *Vet Radiol Ultrasound.* 2012; 53: 236-44.
- [13] Lang J, Busato A, Baumgartner D, Flückiger M, Weber UT. Comparison of two classification protocols in the evaluation of elbow dysplasia in the dog. *J Small Anim Pract.* 1998 ; 39:169-74.
- [14] Voorhout G, Hazewinkel HAW. Radiographic evaluation of the canine elbow joint with special reference to the medial humeral condyle and the medial coronoid process. *Veterinary Radiology* 1987; 28, 158-165.
- [15] Haudiquet PR, Marcellin-Little DJ, Stebbins ME. Use of the distomedial-proximolateral oblique radiographic view of the elbow joint for examination of the medial coronoid process in dogs. *Am J Vet Res.* 2002; 63: 1000-1005
- [16] Wagner K, Griffon DJ, Thomas MW, Schaeffer DJ, Schulz K, Samii VF, Necas A. Radiographic, computed tomographic, and arthroscopic evaluation of experimental radio-ulnar incongruence in the dog. *Vet Surg.* 2007; 36:691-698.
- [17] Lau SF, Theyse LFH, Hazewinkel HAW, van den Belt AJM, Voorhout G. Radiographic, computed tomographic and surgical findings in 34 Labrador Retrievers with medial coronoid disease (MCD) *Proceedings IEWG 2012* pp.15-16
- [18] Beuing R, Mues CH, Tellhelm B, Erhardt G. 2000 Prevalence and inheritance of canine elbow dysplasia in German Rottweilers *J Anim Breed Genet* 2000; 117: 375-383.
- [19] Swenson L, Audell L, Hedhammar A. Prevalence and inheritance of and selection for hip dysplasia in seven breeds of dogs in Sweden and benefit: cost analysis of a screening and control program. *J Am Vet Med Assoc.* 1997; 210: 207-214
- [20] Audell L. Elbow dysplasia, screening and scoring system in *Proceedings IEWG 2000* p. 3
- [21] Dennis R. The BVA/KC Elbow Dysplasia grading scheme. *Proceedings IEWG 2012* pp. 7-10
- [22] Coopmans F, Verhoeven G, Saunders J, Duchateau L, Van Bree H. Prevalence of hip dysplasias, elbow dysplasia and humeral head osteochondrosis in dog breeds in Belgium. *Vet Rec* 2008; 163:654-658.
- [23] Orthopedic Foundation for Animal [OFA] <http://www.offa.org/pdf/>
- [24] Skogmo HK. Elbow screening in the Nordic countries - past, present and future. *Proceedings IEWG 2012* pp. 17-20
- [25] Voorhout G, Hazewinkel HAW. A radiographic study on the development of the antebrachium in Great Dane pups on different calcium intakes. *Vet Rad* 1987; 28: 152-157.
- [26] Grondalen J, Lingaas F. 1982. Arthrosis of the elbow joint among Rottweiler dogs. Results from investigations into hereditary disposition. *Tijdsch Diergeneeskunde* 111, S1: 49-51.
- [27] Olsson SE. 1981. Pathophysiology, morphology, and clinical signs of osteochondrosis in the dog. In: *Pathophysiology in small animal surgery.* MJ Bojrab (ed) Lea&Febiger, pp.604-618.



- [28] Tellhelm B. 2010. Grading primary ED-lesions and elbow osteoarthritis according to the IEWG protocol: [www.vet\\_iewg.org/joomla/images/proceedings/proceedings2010iewg.pdf](http://www.vet_iewg.org/joomla/images/proceedings/proceedings2010iewg.pdf)
- [29] Lappalainen AK, Mölsä S, Liman A, Laitinen-Vapaavuori O, Snellman M. Radiographic and computed tomography findings in Belgian shepherd dogs with mild elbow dysplasia. *Vet Radiol Ultrasound* 2009; 54: 364-369.
- [30] Flückiger M. Radiographic Diagnosis of Elbow Dysplasia in the Dog; Requirements for the IEWG standardized screening procedure, updated version 2010. IEWG proceedings 2010, pp. 8-12
- [31] Tellhelm B. Grading primary ED-Lesions and elbow osteoarthritis according to the IEWG protocol proceedings IEWG 2012 pp. 11-12
- [32] Van Bruggen LW, Hazewinkel HA, Wolschrijn CF, Voorhout G, Pollak YW, Bartezyk PY. Bone scintigraphy for the diagnosis of an abnormal medial coronoid process in dogs *Vet Radiol & Ultrasound* 2010; 51, 344-348.
- [33] Peremans K, Vermeire S, Dobbeleir A, Gielen I, Samoy Y, Piron K, Vandermeulen E, Slegers G, van Bree H, De Spiegeleer B, Dik K. Recognition of anatomical predilection sites in canine elbow pathology on bone scans using micro-single photon emission tomography. *Vet J.* 2011; 188:64-72.
- [34] Hedhammar A, 2008 Genetic aspects of ED and efficacy of breeding programs at: IEWG meeting, Dublin 2008 proceedings pp. 24-25
- [35] Keller GG, Dzuik E, Bell JS 2011 How the OFA is tackling inherited disorders in the USA: using hip and elbow dysplasia as examples. *The Vet J* 189: 197-202 .
- [36] Carpenter LG, Schwarz PD, Lowry JE, Park RD, Steyn PF. Comparison of radiologic imaging techniques for diagnosis of fragmented medial coronoid process of the cubital joint in dogs. *J Am Vet Med Assoc.* 1993; 203:78-83.
- [37] Gemmill T. 2004 Completing the picture: use of CT to investigate elbow dysplasia. *J Small Anim Pract.* 2004; 45:429-430.
- [38] Reichle JK, Snaps F. The elbow. *Clin Tech Small Anim Pract.* 1999; 14:177-186.
- [39] Holsworth IG, Wisner ER, Scherrer WE, Filipowicz D, Kass PH, Pooya H, Larson RF, Schulz KS. Accuracy of computerized tomographic evaluation of canine radio-ulnar incongruence in vitro. *Vet Surg.* 2005; 34:108-113.
- [40] Gemmill TJ, Hammond G, Mellor D, Sullivan M, Bennett D, Carmichael S Use of reconstructed computed tomography for the assessment of joint spaces in the canine elbow. *J Small Anim Pract.* 2006; 47:66-74.
- [41] Kramer A, Holsworth IG, Wisner ER, Kass PH, Schulz KS. Computed tomographic evaluation of canine radioulnar incongruence in vivo. *Vet Surg.* 2006; 35:24-29.
- [42] Samoy Y, Van Ryssen B, Gielen I, Walschot N, van Bree H. Review of the literature: elbow incongruity in the dog *Vet Comp Orthop Traumatol.* 2006; 19:1-8.
- [43] Guthrie S, Pidduck HG. Heritability of elbow osteochondrosis within a closed population of dogs. *J Small Anim Pract* 1990; 31, 93-96.
- [44] Grøndalen J, Lingaas F. Arthritis in the elbow joint of young rapidly growing dogs: a genetic investigation. *J Small Anim Pract* 1991; 32, 460-464.
- [45] Studdert VP, Lavelle RB, Beilharz RG & Mason TA. Clinical features and heritability of osteochondrosis of the elbow in Labradors retrievers. *J Small Anim Pract* 1991; 32, 557-563.
- [46] Mäki K, Liinamo AE, Ojala M Estimates of genetic parameters for hip and elbow dysplasia in Finnish Rottweilers *J Anim Sc* 2000; 78: 1141-1148
- [47] Stock KF, Klein S, Tellhelm B, Distl O. Genetic analyses of elbow and hip dysplasia in the German shepherd dog. *J Anim Breed Genet.* 2011; 128:219-29.
- [48] Salg KG, Temwichitr J, Imholz S, Hazewinkel HA, Leegwater PA. Assessment of collagen genes involved in fragmented medial coronoid process development in Labrador Retrievers as determined by affected sibling-pair analysis. *Am J Vet Res* 2006; 67: 1713-1718.
- [49] Temwichitr J. The genetic defect of fragmented coronoid process in Labrador Retrievers and other skeletal diseases in dogs. PhD thesis 2009, Utrecht University, Faculty of Veterinary Medicine. ISBN 978-90-393-5065-2.
- [50] Aulchenko YS, Ripke S, Isaacs A, van Duijn CM. GenABEL: an R library for genome-wide association analysis. *Bioinformatics* 2007; 23: 1294-1296.
- [51] Lewis TW, Ilska JJ, Blott SC, Woolliams JA. Genetic evaluation of elbow scores and the relationship with hip scores in UK Labrador retrievers. *Vet J* 2011; 189: 227-233
- [52] Hedhammar A, 2008 Genetic aspects of ED and efficacy of breeding programs. IEWG meeting, Dublin 2008 proceedings pp. 24-25

## Part 3 Spondylosis in dogs

Herman Hazewinkel<sup>1\*</sup> Silke Viefhues<sup>2</sup> Bernd Tellhelm<sup>3</sup>

### INTRODUCTION

Spondylosis deformans, also referred to as “spondylosis” and “ankylosing spondylitis”, is a non-inflammatory degenerative abnormality of unknown aetiology with new bone formation originating several millimeters from the disco-vertebral junction. The new bone formation originates from the area adjacent to peripheral endplates and forms small spurs, larger hooks or bony bridges crossing the intervertebral space. In earlier/milder forms of spondylosis the most part of the ventral surface of the vertebral body is thus unaffected (Fig. 1a). The new bone formation increases with age, and has a predilection in Boxer dogs<sup>[1-3]</sup> with an incidence of spondylosis of 26%, 50%, and 55% (Table 1) of the studied Boxer population in Norway, Italy, and The Netherlands, respectively.

There are different qualification systems, with the one of Langeland et al (1995) and Carnier et al (2004) being the most recent ones,<sup>[1-3]</sup> with the following grading system:

Grade 1: the bony spur does not protrude beyond the caudal or cranial edge, respectively, of the vertebral border (Th 10:11 Fig. 1);

Grade 2: the hook protrudes beyond the caudal or cranial edge, respectively, of the vertebral border (Th 9 : 10 Fig. 1);

Grade 3: a bony bridge is formed from the corner of one vertebra to the next (Lumbar vertebrae Fig. 1).

The grading system as introduced by Eichelberg und Wurster, (1983)<sup>[4]</sup> (Fig. 3, Table 3), is in use in Germany by the German and the International Boxer Club, including “free” and four grades of increasing severity. The highest grade is registered on a form which is mailed to the owner and the Boxer Club.

### Predilection of spondylosis and relevance

Spondylosis is seen at predilection sites these being the caudal thoracic vertebrae, the cranial lumbar and the lumbosacral region. In the cervical region spondylosis is less likely to occur. Spondylosis is seen both in combination with healthy and with degenerated (Hansen type 2) intervertebral discs<sup>[5]</sup>. The clinically relevant signs of spondylosis are: decreased flexibility of the vertebral column, lameness, changed gait and pain<sup>[2]</sup>, although often clinical signs are absent<sup>[6]</sup>. Depending on

the dimensions of the new bone formation neurological signs can occur due to their extension in a dorso-lateral direction compressing the spinal nerve roots at the level of the intervertebral foramen<sup>[6]</sup>. Spondylosis is considered to be clinically relevant in working dogs due to the consequently decreased flexibility of the vertebral column<sup>[7]</sup>. In a survey of 100 army dogs (German Shepherds and Mallinois) it was revealed that almost 50% of each breed showed spondylosis in the lumbar vertebrae, although without correlation to age (starting at 2 years) and with an influence on locomotion<sup>[8]</sup>.

1 Department of Companion Animal Sciences, Faculty of Veterinary Medicine, Utrecht University, PO box 80.154, NL-3508 TD Utrecht, The Netherlands.

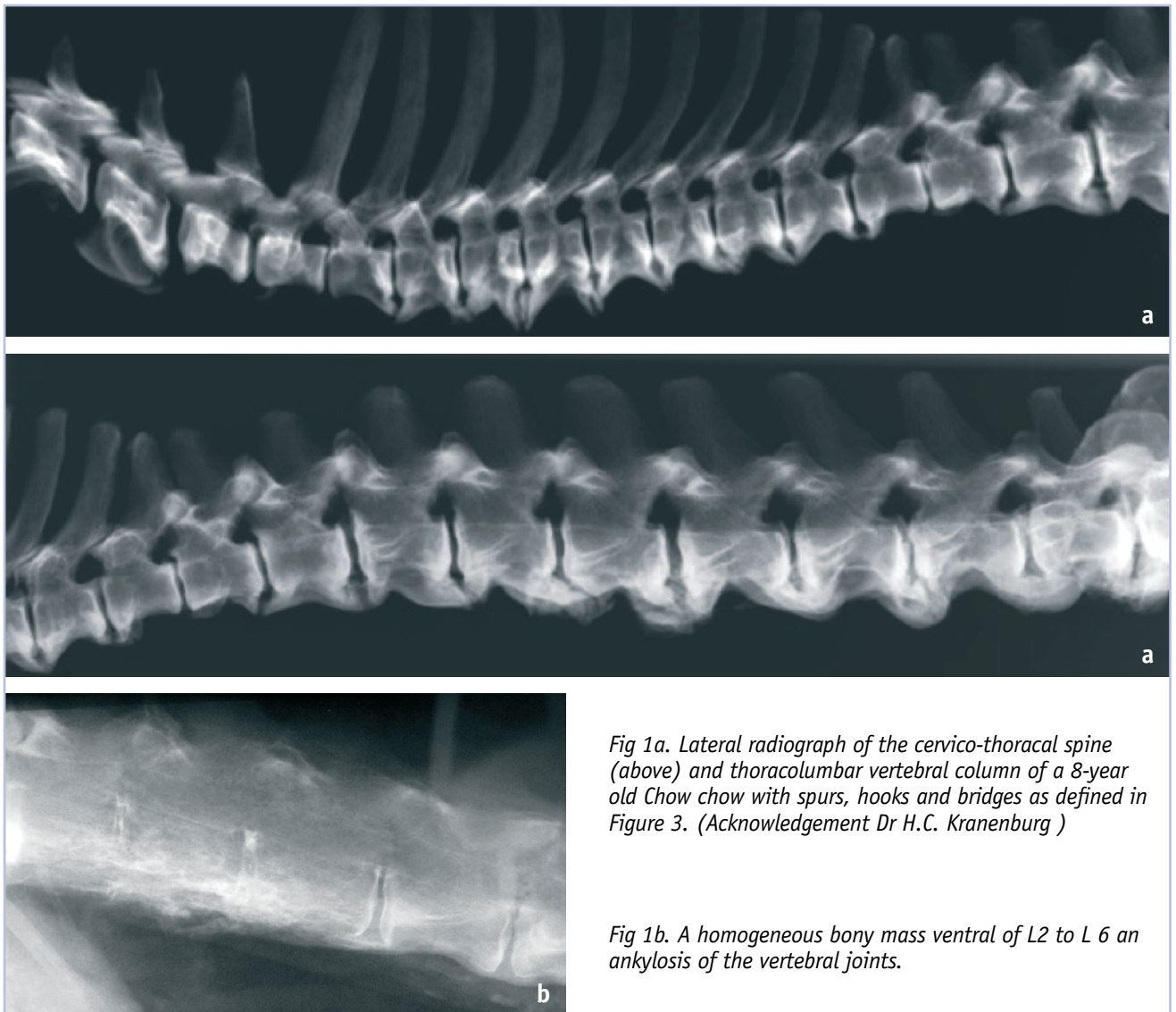
2 Bunsenstrasse 20 D-59229 Ahlen, Germany

3 Justus-Liebig- Universität Giessen, Klinik für Kleintiere-Chirurgie, Frankfurterstrasse 108, D-35392 Giessen, Germany.

\* Corresponding author Prof. Dr. H.A.W. Hazewinkel, DVM, PhD, Dipl. ECVS & ECVN,  
E-mail: H.A.W.Hazewinkel@uu.nl

The main differential diagnosis of spondylosis is diffuse idiopathic skeletal hyperostosis (DISH) or ankylosing hyperostosis, a systemic disorder of the axial skeleton which is a rare occurrence in dogs<sup>[3]</sup> and is considered as a distinct abnormality. The radiological appearance of DISH is different from spondylosis, and resembles flowing bone growth on the spinal ventral longitudinal ligament underneath, per definition, at least four contiguous vertebrae<sup>[9]</sup> (Fig 1b). It coincides not only with stiffness, but often also with back pain on palpation and pain with excessive movement, more commonly than is the case in

spondylosis<sup>[3]</sup>. This is probably due to the compression on surrounding structures by the large masses of bone which are considerably greater than the smaller spurs and bridges found in cases of spondylosis. DISH can be seen in conjunction with spondylosis (Table 1). In a large retrospective study of radiographs of 2041 purebred dogs 78 dogs (3.8%) had signs of DISH and 53 of those (68% of the dogs with DISH) also had also spondylosis<sup>[3]</sup>. T6-T10 and L2-L6 were the most frequently involved vertebrae with DISH, whereas the more flexible cervical and caudal lumbar area were least affected.



*Fig 1a. Lateral radiograph of the cervico-thoracic spine (above) and thoracolumbar vertebral column of a 8-year old Chow chow with spurs, hooks and bridges as defined in Figure 3. (Acknowledgement Dr H.C. Kranenburg )*

*Fig 1b. A homogeneous bony mass ventral of L2 to L 6 an ankylosis of the vertebral joints.*

## The incidence of spondylosis

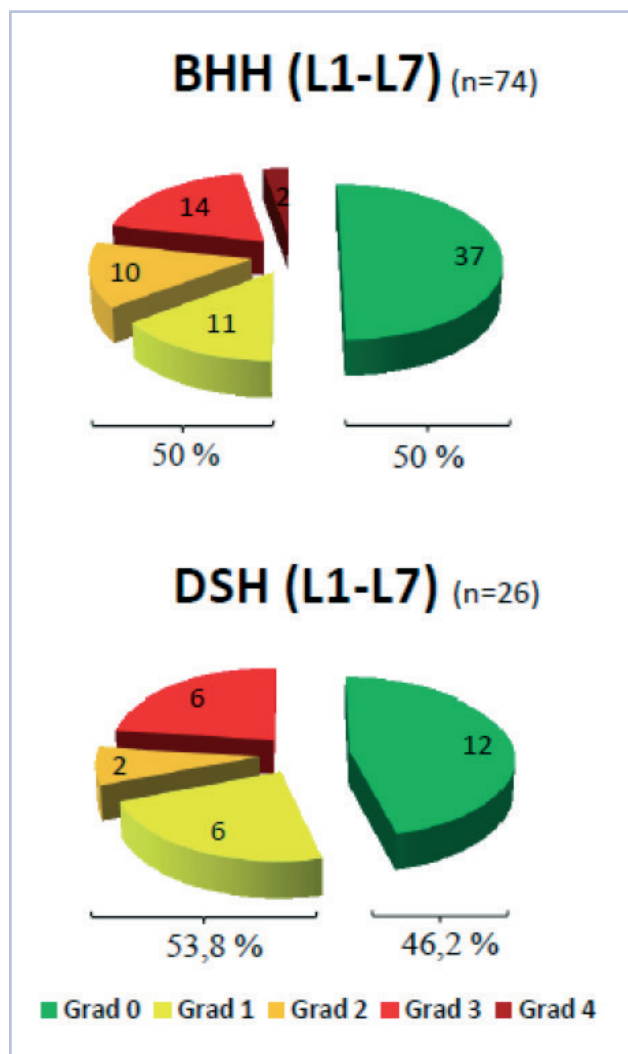
Spondylosis was seen in 18% of the dogs in a retrospective study of 1046 purebred dogs (367/2041), with 25.6% grade 1, 14.7% grade 2 and 59.7% grade 3<sup>[3]</sup>. Although in all dogs the entire vertebral column could not be studied, it showed that T4-T7 , T9-10, L2-L4 and LS joints were most frequently involved with spondylosis.

Table 1: Prevalence (%) of spondylosis, co-morbidity with DISH, or DASH only and Odds ratio

	free	Spondylosis (1-3)	Spondylosis + DISH	DISH only	odds (p) for spondylosis
Boxer (n= 69)	32	27	27	13	9.237 (< .001)
German Shepherd (n= 38)	65	29	5	2	3.327 (<.001)
Dobermann (n= 36)	67	33	0	0	3.082 ( .003)
Flat Coated Retriever (n= 61)	57	30	6	7	2.834 (<.001)
Labrador Retriever (n= 244)	74	23	2	0	1.465 (.037)

In these 5 breeds new bone formation at the vertebrae is more common (Odd >1) than in the total population<sup>[3]</sup>

Figure 2. Spondylosis grading in Malinois (BHH) and German Shepherd dogs (DSH) from the German army according to the grading scheme of Eichelberg and Wurster (1982)<sup>[10]</sup>. (Acknowledgement Dr F.Matzen and Prof. dr. R Köstlin)<sup>[8]</sup>



## Screening for spondylosis

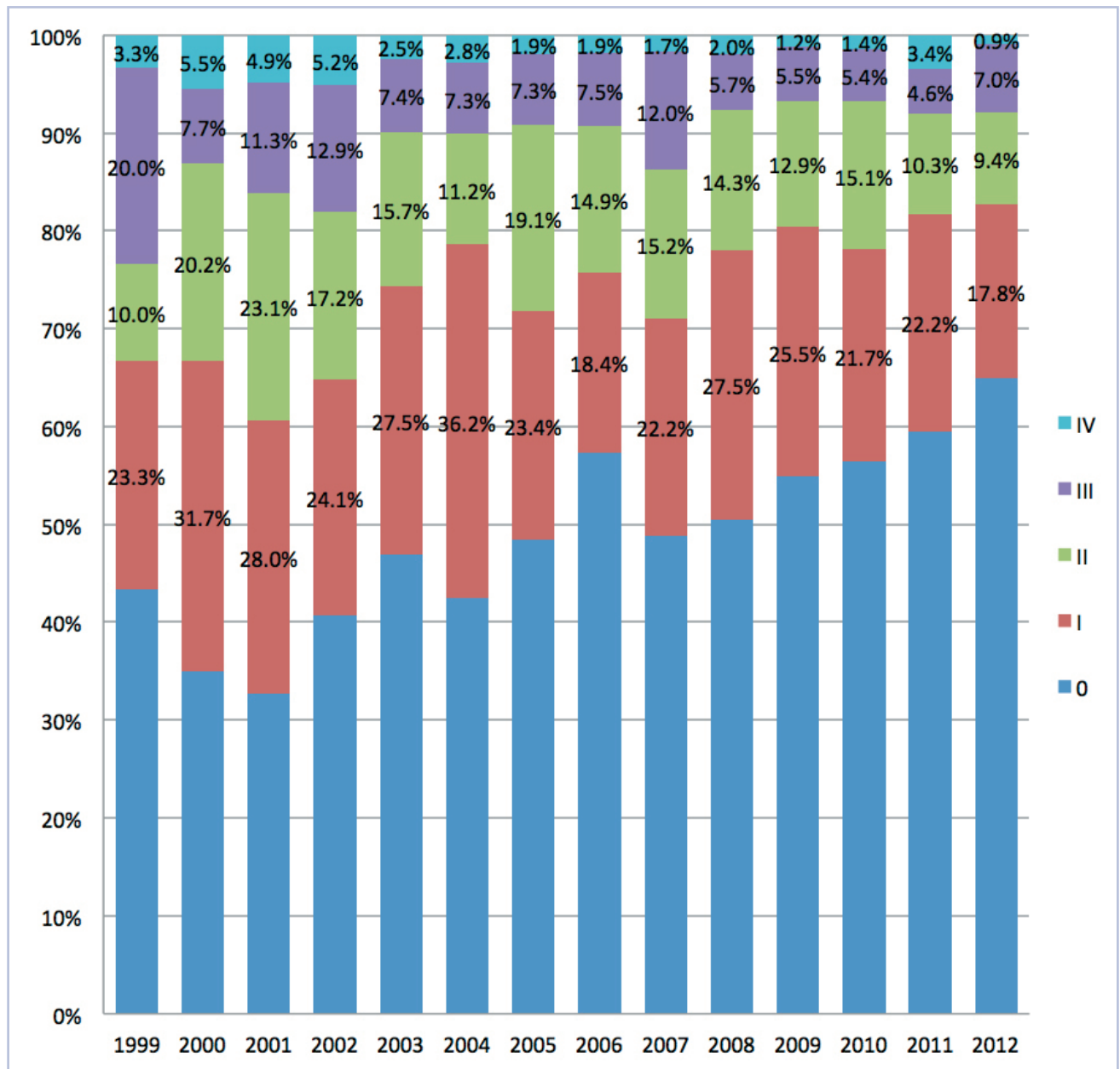
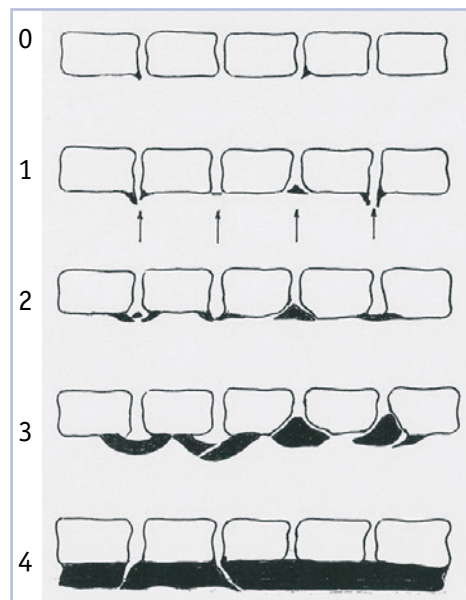
Screening for spondylosis in Boxer dogs is voluntary in Germany and undertaken by the Boxer-Klub München e.V. (BK) and the International Boxer Club e.V. (IBC). It is also voluntary in the Nordic countries. Malinois screening for spondylosis is also on a voluntary basis in Germany. The minimum age for radiological screening of dogs is 24 months. Screening is performed on lateral views of the vertebral column from the first thoracic to the last lumbar vertebrae and should be of good quality: no sedation or anaesthesia is usually required. The radiographs are sent to the scrutineer of the German Boxer Association (Dr. Silke Viefhues) or Malinois Association (Dr. Alexander Koch). The scheme is applied to all the vertebral endplates, except the lumbo-sacral intervertebral space: the final grading (grade 0, or grade 1-4) (Fig 3, Table 3) is reported to both the owner and the Boxer Association. There is an appeal process available.

Every dog that is used for breeding has to be evaluated. There is no breeding limitation set by the breeders club, but there is a limitation in the use of dogs with spondylosis grade 3 and 4.

Screening for spondylosis has been performed since 1999 in boxers, starting with 56% spondylosis positive Boxers till 35% spondylosis positive Boxers in 2012. Progress has been made as revealed by an overview of the spondylosis grading during the last 14 years with an increase of "free" from 35% in 2000 to 65% in 2013 (Table 2)



Table 2: Spondylosis in Boxer dogs &gt; 2 years from 1999-2012

Fig 1: Grade 0 (free) and grade 1-4 <sup>[4]</sup>Table 3: Definitions of grade 0 – 4 spondylosis according to Boxer Klub München e.V. und International Boxer Club <sup>[4]</sup>

Grade	Definition
0	no spurs or spurs < 3 mm in a maximum of 1-2 ivs or 1 hook > 3 mm in one ivs
1	Spur of < 3 mm in 3 or 4 ivs Hook of > 3 mm in 2 or 3 ivs Large unconnected bony island in 1 or 2 ivs
2	Each bony bridge (complete or partial) at 1 or 2 ivs Large unconnected bony island at 2 or 3 ivs
3	Bridges (complete or partial) at 2 or 3 ivs
4	Continuous bony bridge with bamboo-like appearance

ivs = intervertebral space(s)

## References

- [1] Langeland M, Lingaas F. Spondylosis deformans in the boxer: estimates of heritability J Small Anim Pract 1995; 36: 166-169
- [2] Carnier P, Gallo L, Sturaro E, Piccinini P Bittante G. Prevalence of spondylosis deformans and estimates of genetic parameters for the degree of osteophytes development in Italian boxer dogs J Anim Sci 2004; 82: 85—92
- [3] Kranenburg HC, Voorhout G, Grinwis GCM, Hazewinkel HAW, Meij BP. Diffuse idiopathic skeletal hyperostosis (DISH) and spondylosis deformans in purebred dogs: a retrospective study Vet J. 2011; 190: 84-90
- [4] Eichelberg H.; Wurster H. Untersuchungen an Boxern zum Verknöcherungsverlauf bei der Spondylosis deformans. Kleintierpraxis 1983 28, 393-444.
- [5] Levine GJ, Levine JM, Walker MA R. R. Pool RR, Fosgate GT. Evaluation of the association between spondylosisdeformans and clinical signs of intervertebral disk disease in dogs: 172 cases (1999-2000). J Am Vet Med Assoc 2006; 228:96-100
- [6] Morgan JP, Hansson K, Miyabayashi T. Spondylosis deformans in the female beagle dog: a radiographic study J Small Anim Pract 1989; 30: 457-460
- [7] Vaughan IC. Orthopaedic problems in old dogs Vet Rec 1990; 126: 379-293.
- [8] Matzen F. Radiologisch/klinische Befunde an Wirbelsäule und Hüfte bei Ankauf und Ausmusterung von Diensthunden der Bundeswehr, Dissertation, München (G) February 2013.
- [9] Resnick D, Niwayama GG Radiographic and pathologic features of spinal involvement in diffuse idiopathic skeletal hyperostosis (DISH) Radiology 1976; 119: 559-568
- [10] Eichelberg, H.; Wurster, H. Untersuchungen zur Spondylosis deformans bei Boxern. Kleintierpraxis.1982 27, 57-72.



## COMMISSIONED PAPER (D)

# Prevalence, grading and genetics of hemivertebrae in dogs

*E. Schlensker<sup>\*1</sup>, O. Distl<sup>1</sup>*

## SUMMARY

Hemivertebrae are the most frequent vertebral malformations in dogs and particularly common in chondrodystrophic dog breeds like the French bulldog, English bulldog, Pug and Boston terrier. Clinical signs caused by hemivertebrae are pelvic limb ataxia and paresis, loss of reflexes, kyphosis, lordosis and scoliosis, incontinence, atrophy and atony of the pelvic limbs due to a compression of the spinal cord. Hemivertebrae can be unilateral or bilateral. The standard diagnostic routine relies on ventrodorsal and lateral x-rays or even computer tomography. A few breeding associations request a mandatory x-ray examination for future breeding dogs to exclude individuals with a high number of hemivertebrae and/or hemivertebra at critical localisations in the thoracic spine or highly malformed vertebrae. Heritability estimates in French bulldogs indicate that breeding progress can be made using selective breeding and predicting breeding values for future breeding animals.

key words: hemivertebra, screening, heritability, dog

This paper was commissioned by FECAVA for the special issue of EJCAP, Genetic/Hereditary Disease and Breeding.

## Introduction

Hemivertebrae, also called wedge-shaped vertebrae, are among the most frequent vertebral malformations in the dog<sup>[1]</sup>. This condition is assumed to be highly heritable<sup>[2]</sup>. The first reports in dogs date back for more than 100 years. Hemivertebrae are common in chondrodystrophic dog breeds, but may also be infrequently seen in other breeds like Pomeranians<sup>[3]</sup> and Doberman pinschers<sup>[4]</sup>. Neurological signs accompanying hemivertebrae due to a

compression of the spinal cord become manifest in 3 - 4 month old dogs. Pelvic limb ataxia and paresis, loss of reflexes, kyphosis, lordosis and scoliosis, incontinence and atrophy and atony of the pelvic limbs are seen in affected dogs<sup>[5, 6]</sup>.

The objectives of this article are to review the prevalences and possible hereditary influences on hemivertebrae in dogs. The grading schemes used in dog breeding programs are discussed and a genetic analysis on hemivertebrae in French bulldogs is presented. Herein, we could show a considerable genetic variation underlying this condition in French bulldogs and this may stimulate efforts to implement breeding programmes.

1 Institute for Animal Breeding and Genetics, University of Veterinary Medicine, Foundation, Bünteweg 17p 30559 Hannover, Germany  
E-mail: Eva.Schlensker@yahoo.de

\*Corresponding author Eva Schlensker, Weyerstraße 114 D-50676 Köln

## Pathogenesis

Vertebrae derive from sclerotomes which surround the neural tube and the notochord and form the primordial vertebrae in the early embryonic development. Vertebrae have three ossification centres. At birth, ossification of these cartilaginous centres is only partial. Ossification of the vertebrae is completed by 7-9 months of age<sup>[7]</sup>. Hemivertebrae in dogs are caused by an asymmetrical development or a failure in fusion of two ossification centres<sup>[5]</sup>. There exist two forms of hemivertebrae: unilateral and bilateral.

Unilateral hemivertebrae occur when the right and the left half of the vertebrae develop asymmetrically<sup>[3, 6, 4, 8]</sup>. These vertebrae are wedge shaped with the base orientated dorsally, ventrally or laterally<sup>[9, 6]</sup>.

Bilateral vertebrae are caused by a non-union of the right and left halves of the vertebrae body. This malformation is termed butterfly vertebrae<sup>[5, 3, 4, 8]</sup>. Hemivertebrae may be single or multiple. The bilateral hemivertebrae often do not evoke clinical signs<sup>[5, 6, 2, 8]</sup>.

## Diagnosis, Screening and Grading

Some breeding associations have implemented systematic breeding programmes based on phenotypic records of x-rays of the vertebral column. Diagnosis and grading of hemivertebrae are usually based on a radiological examination with ventrodorsal and lateral x-rays of the vertebral column (Fig. 1, Fig2)<sup>[8]</sup>. Age at examination should be between 10<sup>[10, 11]</sup> and 12 months<sup>[13, 13]</sup>. There

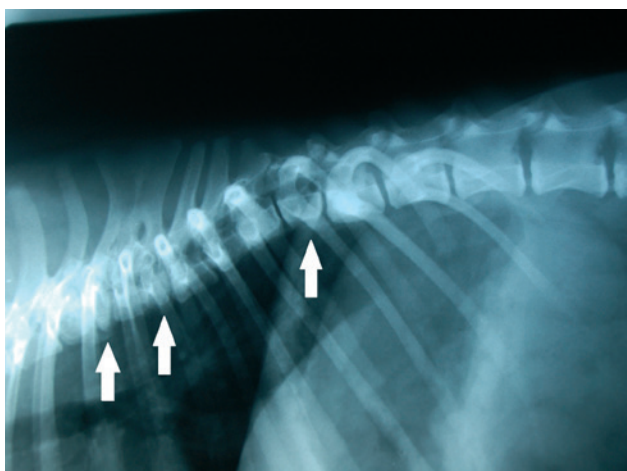


Fig. 1: X-ray from a French bulldog of the German Club of French Bulldogs with Hemivertebrae in the thoracic spine (white arrow)

is no agreement whether the dogs for the radiographic examination have to be sedated or anaesthetized. Dog breeding associations tend to suppose that radiography may be performed without anaesthesia. However, anaesthetists feel more secure having small brachycephalic dogs with possible upper airway problems anaesthetized, rather than just sedated<sup>[12, 13]</sup>.

There are two standard positions for the required radiography. The dog has to be placed in a lateral position, because of the lack of consequences of bilateral hemivertebrae<sup>[10, 11]</sup> or in a lateral and ventrodorsal position<sup>[14, 12]</sup>. The x-rays have to show at least T1 (thoracic vertebrae 1) to L7 (lumbar vertebrae 7) centred on T8-L1<sup>[12, 13]</sup> or on the junction between thoracic and lumbar spine. Some breeding associations require x-rays from the whole thoracic and lumbar spine and the beginning of the caudal spine or even the whole spine<sup>[14]</sup>.

The extent of the dorsal dislocation towards the posterior of the respective vertebrae, and the degree of the spinal cord compression can be detected with the help of a lateral myelogram<sup>[4]</sup> or a magnetic resonance and computed tomography<sup>[8]</sup>.

Classification of hemivertebrae for preventive health examinations is done by one panelist for a dog breeding association. Grading regards number, localization and severity of the malformation of all single hemivertebrae<sup>[10, 11, 14, 12, 13]</sup>. Some panelists also record the number of the caudal vertebrae<sup>[10, 11]</sup>.

In some German dog breeding associations this classification is based on hemivertebrae number and location, with grade 1 = no hemivertebrae, grade 2 = 1

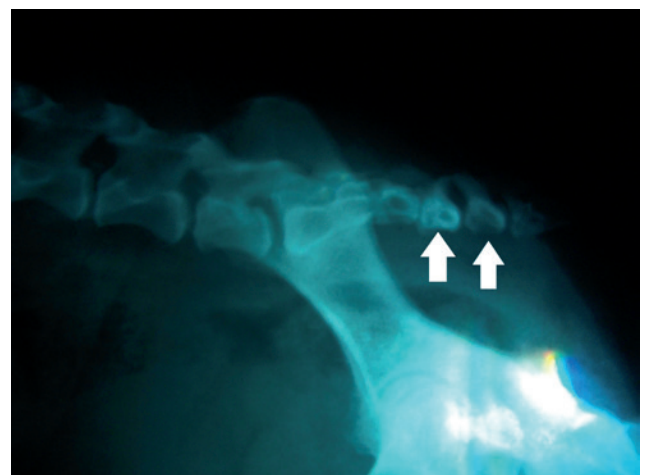


Fig. 2: X-ray from a French bulldog of the German Club of French bulldogs with a screw tail due to a Hemivertebrae (white arrow)



- 3 hemivertebrae, grade 3 = 4 - 6 hemivertebrae, grade 4 = > 6 hemivertebrae, grade 5 = hemivertebrae between thoracic and lumbar spine. Animals with grades 4 and/or 5 are excluded from breeding<sup>[10, 11]</sup>. Other dog breeding associations use a scheme with following scores: any hemivertebrae at T1 - T7 = score 1, any hemivertebrae at T8 - T11 = score 2, any hemivertebrae at T12 - T13 = score 3. Animals with score > 1 are excluded from breeding<sup>[14]</sup>.

Because the angle of the vertebral column – rather than the number of hemivertebrae – is decisive for clinical signs<sup>[15]</sup>, a four-point-measurement of hemivertebrae (after Felsenberg and Kalender) was introduced into the classification system used by German dog breeding associations. Measurements record the dorsal (distance from A to B indicating the leading and rear edge of the dorsal surface of the vertebral body) and ventral (distance from C to D indicating the leading and rear edge of the ventral surface of the vertebral body) length of each hemivertebra (Fig. 3). The differences between the dorsal and ventral vertebral body length measurements are scored according to Armbecht<sup>[18]</sup> in 5 classes (grade 0 = vertebral body lengths are identical, grade 1 = < 20% difference among dorsal and ventral vertebral body lengths, grade 2 = 20 - 40% difference, grade 3 = 40 - 60% difference, grade 4 = > 60% difference) (Tab. 1).

## Prevalence and Genetics

Hemivertebrae are common in chondrodystrophic breeds like French and English bulldog, Pug, Boston terrier or

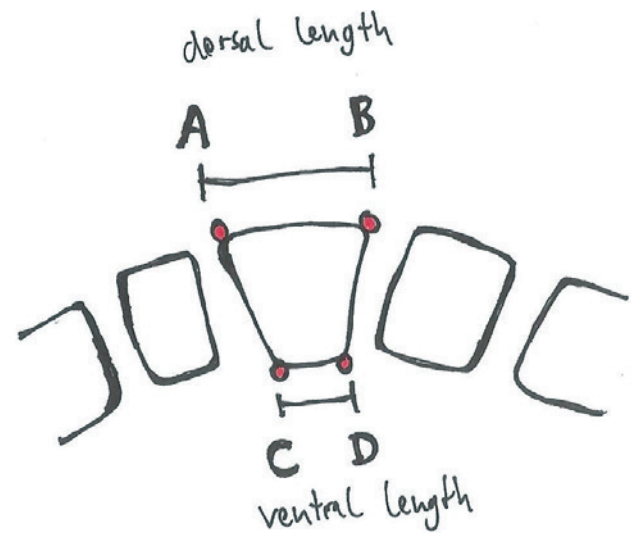


Fig. 3: Measurement of affected vertebrae with the Four-Point-System. Measuring the dorsal (d) and ventral (v) level (Felsenberg-Kalender)

Pekingese<sup>[5, 16, 3, 9, 1, 7, 2, 8]</sup>. These dogs originate from screw tailed breeds as a breed characteristic due to caudal hemivertebrae<sup>[3, 17, 6, 8]</sup>. Coccygeal hemivertebrae have been favoured in selective breeding as a desirable phenotype in many brachycephalic breeds. Selection for screwed tails is believed to enhance the risk for hemivertebrae in the thoracic and lumbar spine<sup>[17, 9]</sup>. The occurrence of hemivertebrae is not restricted to chondrodystrophic breeds but is also infrequently seen in other breeds like Pomeranian dog<sup>[3]</sup> and Dobermann pinschers<sup>[4]</sup> and mongrels (Tab. 2).

The male to female ratio does not suggest any sex specific influences<sup>[3]</sup>. A study in Italy about hemivertebrae in English bulldogs reported an incidence of 97.3%<sup>[19]</sup>

Tab. 1: The four-point-measurement of hemivertebrae according to Felsenberg and Kalender was introduced into the classification system used by German dog breeding associations. A graduation from degree 0 to degree 4 is developed by measuring the dorsal (distance from A to B indicating the leading and rear edge of the dorsal surface of the vertebral body) and ventral (distance from C to D indicating the leading and rear edge of the ventral surface of the vertebral body) length of each hemivertebra

Grade	Grading system according to German dog breeding associations	Grade	Grading system according to Felsenberg and Kalender
1	No Hemivertebrae	0	vertebral body lengths are identical
2	1-3 Hemivertebrae	1	< 20% difference between dorsal and ventral vertebral body lengths
3	4-6 Hemivertebrae	2	20 - 40% difference between dorsal and ventral vertebral body lengths
4	More than 6 Hemivertebrae	3	40 - 60% difference between dorsal and ventral vertebral body lengths
5	Hemivertebrae between thoracic and lumbar spine	4	> 60% difference between dorsal and ventral vertebral body lengths

Tab. 2: Occurrence of Hemivertebrae in different dog breeds

Breed	Number of dogs examined	Affected dogs	References
German Shorthaired Pointer	29	10	Kramer et al., 1982
French bulldog	95	83	Grebe, 1984
English bulldog	38	36	Grebe, 1984; Volta et al., 2005
Yorkshire terrier	1	1	Done et al., 1975
Pug	10	10	Jeffery et al., 2007
Fox terrier	1	1	Kirberger, 1989
Pekingese	6	6	Done et al., 1975; Ruberte et al., 1995
Westhighland white terrier	1	1	Done et al., 1975
Pomeranian	1	1	Done et al., 1975
Dobermann pinscher	1	1	Thilagar et al., 1998
Crossbreed	4	4	Besalti et al., 2005

In our current study, 105 French bulldogs were examined using lateral radiographs of the vertebral column. The dogs were born between 1994 and 2011. The pedigree file included 809 animals up to five generations. Prevalence of hemivertebrae was 86.7% of which 44% of the affected dogs were males. There was no significant sex difference for the number and grade of hemivertebrae. The highest frequency of hemivertebrae was in T6 - T12. This distribution of hemivertebrae is in agreement with the report on English bulldogs from Italy<sup>[19]</sup>. The mean inbreeding and relationship coefficients were slightly higher for the affected French bull dogs compared to unaffected dogs.

Figure 4 shows the pedigree of one French bulldog family including 102 dogs. Out of these, 52 animals had been examined for hemivertebrae and 43 animals had been

diagnosed as affected by hemivertebrae. There are affected and unaffected dogs in one litter as well as a litter with only affected members and one unaffected parent. Hemivertebrae are not seen in every generation, so a recessive trait is more likely. An X-linked inheritance can be ruled out, because affected dams have unaffected sons.

A linear animal model was employed to estimate heritabilities for the number and grade of hemivertebrae

Tab. 3: Heritability estimates for the appearance of number of Hemivertebrae and for the grade of Hemivertebrae (total number of animals: 694, base animals: 278)

Hemivertebrae	Heritability	Standard deviation
Grade	0.24	0.13
Number	0.64	0.12

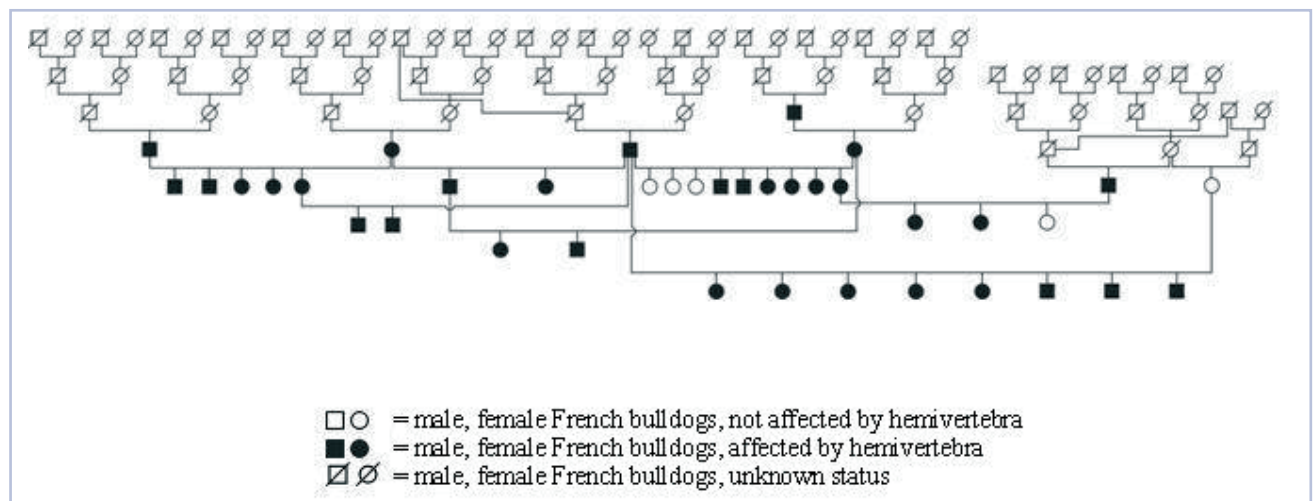


Fig. 4: A pedigree from one French bulldog family, including 102 dogs

using VCE, version 5.1.2. Heritability estimates were at  $0.64 \pm 0.12$  for the number of hemivertebrae and at  $0.24 \pm 0.13$  for the grade of hemivertebrae, respectively (Tab. 3). In English bulldogs and Yorkshire terriers a familial correlation has been reported [3]. An autosomal recessive trait for hemivertebrae in German short-haired Pointer had been assumed [20, 17].

## Conclusions

Very high prevalences of hemivertebrae were shown for French and English bulldogs and further chondrodystrophic dog breeds. In most cases, the animals do not show any clinical signs, but hemivertebrae may evoke a compression of the spinal cord in the long term and this can therefore be the reason for neurological signs. Breeding programmes to reduce the prevalences of hemivertebrae should be effective due to the large genetic variation in the number and localization of hemivertebrae and their degree of malformation. However, there is lack of information on the degree of spinal cord compression in dogs affected by hemivertebrae and clinical signs in older dogs resulting from hemivertebrae.

## Acknowledgement

The authors express their gratitude to the German Club of French Bulldogs (Deutscher Klub für Französische Bulldoggen, DKFB) and the German Dog Sport Union (Deutsche Hundesport Union, DHSU) for providing radiographs and pedigree data.

## References

- [1] Ruberte J, Anor S, Carretero A, Vilafranca M, Navarro M, Mascort J, Pumarola M. Malformations of the vertebral bodies and the ribs associated to spinal dysraphism without spina bifida in a Pekingese dog. *J Am Vet Med Asso.* 1995; 42: 307-313
- [2] Besalti O, Ozak A, Eminaga P, Eminaga S. Nasca classification of hemivertebrae in five dogs. *I Vet J.* 2005; 8: 688-690
- [3] Done SH, Drew RA, Robins GM, Lane JG. Hemivertebrae in a dog: clinical and pathological observations. *Vet Rec.* 1975; 96: 313-317
- [4] Thilagar S, Gopal MS, Dewan Muthu Mohammed MS. Hemivertebrae in a dog. *Ind Vet J.* 1998; 75: 163-164
- [5] Grenn HH, Lindo DE. Hemivertebrae with severe kypho-scoliosis and accompanying deformities in a dog. *Can Vet J.* 1969; 10: 214-216
- [6] Bailey CS, Morgan JP. Congenital spinal malformations. *Small Anim Pract.* 1992; 22: 985-1015
- [7] Wright JA. Congenital and developmental abnormalities of the vertebrae. *J Small Anim Pract.* 1979; 20: 625-634
- [8] Jeffrey N, Smith PM, Talbot CE. Imaging findings and surgical treatment of hemivertebrae in three dogs. *J Am Vet Med Assoc.* 2007; 230: 532-536
- [9] Grebe J. The French Bullytin. 1984; 3: 11-15
- [10] Deutscher Klub für Französische Bulldoggen e.V.: Ergänzungs-Zuchtordnung [homepage on the Internet]. c2009 [updated 2009 Jan 12; cited 2013 Aug 14]. Available from <http://www.dkfb.de/doks/zo.pdf>
- [11] Deutsche Hunde Sport-Union e.V.: Verbandszuchtordnung [homepage on the Internet]. c2008 [updated 2008 Apr 29; cited 2013 Aug 14]. Available from [http://www.dhsu.de/DHSU\\_Zuchtordnung\\_April\\_2008.pdf](http://www.dhsu.de/DHSU_Zuchtordnung_April_2008.pdf)
- [12] The Pug Dog Welfare & Rescue Association: Hemivertebrae Screening – Procedure [homepage on the Internet]. c2013 [updated 2009; cited 2013 Aug 14]. Available from <http://pugwelfare-rescue.org.uk/hemivertebrae-screening-scheme/hemivertebrae-screening-procedure-2/>
- [13] White D. Screening for hemivertebrae in pugs. *Vet Rec.* 2013; 1: 24
- [14] French Bulldog Club of New South Wales : Health screening [homepage on the Internet]. c2013 [updated 2013; cited 2013 Aug 14]. Available from [http://www.frenchbulldogclubnsw.asn.au/health\\_screening.html](http://www.frenchbulldogclubnsw.asn.au/health_screening.html)
- [15] Moissonnier P, Gossot P, Scotti S. Thoracic kyphosis associated with hemivertebrae. *Vet Surg.* 2011; 40: 1029-1032
- [16] Drew RA. Possible association between abnormal vertebral development and neonatal mortality in bulldogs. *Vet Rec.* 1974; 94: 480-481
- [17] Kramer JW, Schiffer SP, Sande RD, Whitener EK. Characterization of heritable thoracic hemivertebrae of the German shorthaired pointer. *J Am Vet Med Assoc.* 1982; 181: 814-815
- [18] Armbrrecht G. Inzidenz der vertebraelen osteoporotischen Fraktur in Deutschland [dissertation] Fachbereich Vet Med: Freie Universität Berlin; 2001
- [19] Volta A, Morgan JP, Gnudi G, Bonazzi M, Gazzola M, Zanichelli S, De Risio L, Bertoni G. Clinical-radiological study of the vertebral abnormalities in the English bulldog. *European Association of Veterinary Diagnostic Imaging - EAVDI- 12th Annual Conference, Naples 2005*, 31
- [20] Breur GJ, Lambrechts NE, Todhunter RJ. The genetics of canine orthopaedic traits. In: Ostrander E, Ruvinsky A, editors. *The Genetics of the Dog*, 2nd edition, New York: CABI Publishing, 2012; p. 138.