

104 Vaginal Rejuvenation and Cosmetic Vaginal Surgery

Robert D Moore and John R Miklos

INTRODUCTION

Vaginal rejuvenation and cosmetic vaginal surgery is one of the latest trends in gynecology, urogynecology, and plastic surgery and has created controversy and debate over the subject throughout the world. This latest craze in “sex surgeries” or “nip and tuck below the belt” have created a stir in the press with articles being published throughout the world in mainstream women’s magazines, on TV shows, and in newspaper articles. It is a topic that seems to bring out emotional responses on both sides of the controversy. For example, many women’s groups are applauding the fact that “finally women are being listened to and being offered procedures to help with sexual function or sexual self-imagery or confidence,” while others are very critical and feel that women are being forced to look “perfect” now in every part of their body, including their vaginas.

In the current chapter we will discuss some of the controversy surrounding these topics and review the background and history of these procedures, the available data to support them as well as review techniques and complications of these procedures. Finally, we will also attempt to shed light on what is myth and what is science in this relatively new field of elective vaginal surgery for sexual function and cosmesis of the female vagina and vulva. The chapter is divided into two sections: 1. Vaginal rejuvenation procedures and 2. External vaginal/vulvar cosmetic surgery. Many use the term “vaginal rejuvenation” to encompass all elective vaginal/vulvar surgery, however, we feel that it should be used only to refer to functional procedures of the internal vaginal canal and introitus that are designed to enhance sexual function, which includes ensuring adequate support of the pelvic floor and then internal vaginal canal repairs and repair of the introitus. Similarly, cosmetic vaginal surgery to many just means labiaplasty or labial minora reduction; however, one will see in the second section of the chapter that it is much more comprehensive than this. Therefore, we have defined “cosmetic vaginal/vulvar surgery” as cosmetic or aesthetic procedures of the outside of the vagina and/or vulva, including labiaplasty, labia minora reduction, excess or redundant clitoral prepuce reduction, labia majora reduction or augmentation, labia majora divergence repair, perineal skin reduction, and mons pubis reduction. In most instances, to achieve the outcome desired by the woman, a combination of these external cosmetic procedures needs to be done, truly bringing in the “art” of aesthetic surgery.

VAGINAL REJUVENATION

Vaginal rejuvenation is a relatively new term that refers to repair of the vaginal canal and opening of the vagina for sexual function. It is a term that has recently created quite a lot controversy in the fields of gynecology and urogynecology as well as in the public eye because of all the publicity that has been

generated by these new procedures. There does seem to be much misinformation and confusion over what the term actually refers to and what procedures are actually being done and where on the body they are completed. Here we use the term to refer to surgical procedures of the internal vagina and the introitus that are designed to repair vaginal relaxation and enhance or improve sexual function and sensation of the female vagina and reserve the term “cosmetic vaginal surgery” to refer to the outside of the vagina. Utilizing this definition, one realizes that this is not a new field at all, i.e., gynecologists have been dealing with sexual dysfunction related to vaginal pathology resulting mostly from vaginal childbirth for hundreds of years. Many women presenting for vaginal rejuvenation procedures, actually are found to have symptoms and findings of prolapse and therefore a proper repair involves restoring the foundation of pelvic floor support and also then encompassing some of the newer concepts of vaginal rejuvenation in the repair.

Prolapse and vaginal relaxation occurring after vaginal childbirth is not a new concept. We have very good evidence that vaginal delivery increases risks for vaginal support problems, vaginal relaxation, prolapse, and incontinence. Various pathophysiologic studies have demonstrated marked changes after vaginal delivery to levator muscles (1), nerves (2), and pelvic support. It is clear that parous women are more likely to have pelvic organ prolapse, fecal incontinence, and urinary incontinence than women who have not borne children. There is ample epidemiological evidence that vaginal delivery appears to be the strongest risk factor for pelvic floor disorders, at least in young and middle-aged women. In women participating in the Women’s Health Initiative (3), those who had borne at least one child were twice as likely to have uterine prolapse, rectocele, and cystocele as nulliparas, after adjusting for age, ethnicity, body mass index, and other factors. The amount of damage at the time of vaginal childbirth has also been shown to correlate with sexual function. At six months postpartum, women with an intact perineum or first-degree perineal tear were more likely to experience orgasm than those with either second-, third-, or fourth-degree perineal tear (4). It also is interesting that if vaginal childbirth did not affect sexual function and/or risk of prolapse, than why would 45.5% of urogynecologists surveyed, state they would opt for primary elective caesarian section at time of delivery? (5).

There is very little data in the literature that looks at sexual function related to vaginal and pelvic floor support. Although, dysfunction of vaginal support leading to incontinence, prolapse, and sexual dysfunction is highly prevalent, surprisingly little research has been undertaken regarding the sexual function portion of the equation. The American Urogynecologic Society has stated that any surgery for pelvic organ support

should take into account: restoring the normal anatomy and function of pelvic floor and vagina, including maintaining support, and also maintaining or correcting bowel, bladder, and sexual function. Despite these goals, very little information regarding sexual function and vaginal relaxation exists in the literature (6–8). Recently, Lowenstein et al. in an article titled “Urogynecology and sexual function research. How are we doing?,” concluded that disorders of the pelvic floor do influence sexual function and satisfaction; however, most pelvic floor research abstracts still do not mention sexual function in their outcome (9). Only recently have studies in prolapse repair begun to take a closer look at the effect of surgery on sexual function.

We believe that two critical questions need to be answered: Does prolapse and/or vaginal relaxation cause sexual dysfunction and does repair improve sexual function and/or sensation of the female vagina? While research and data regarding these specifics are lacking, we will attempt to examine some of the existing data and make some educated conclusions regarding vaginal relaxation and sexual function. Finally, we will address whether repair of vaginal relaxation, which may not be severe enough to cause symptomatic prolapse, results in an improvement of sexual function.

PROLAPSE AND SEXUAL FUNCTION

It is beyond the scope of this chapter to review all of the anatomy, neuroanatomy of pelvic floor support, and its relation to sexual function; however, suffice it to say that we do have good evidence that vaginal childbirth, as well as other environmental and genetic factors, can lead to issues with pelvic floor support which in turn can affect sexual function. One of the goals of pelvic floor repairs is to restore sexual function, therefore we will make the assumption that vaginal relaxation and prolapse can affect sexual function in a negative way. The literature also supports this theory as well. In a recent study, Novi et al. compared sexual function in women with prolapse compared to women without prolapse (10). They collected sexual function data utilizing a standardized, validated, condition specific questionnaire, the pelvic organ prolapse/urinary incontinence sexual function questionnaire (PISQ), to compare the two groups. They found that prolapse had a significant negative impact on sexual function. They also looked at a group of patients who had a prior prolapse repair and were currently without prolapse and found that their scores were not significantly different from patients with normal support and no prior surgery. Botros et al. attempted to assess the impact of childbirth on female sexual function using an identical twin study design (11). They administered the PISQ to 276 identical, sexually active twins and found that nulliparous women reported superior sexual satisfaction scores compared to parous women. Barber et al. evaluated sexual function in women with urinary incontinence and pelvic organ prolapse and found that prolapse was more likely than incontinence to affect sexual activity and sexual relations (12). Rogers et al. found that women with urinary incontinence and/or pelvic organ prolapse, had significantly poorer sexual function, as reported by the PISQ and reported less sexual activity than those without the

conditions (13). These studies have confirmed that prolapse, albeit a more severe form of vaginal relaxation, but certainly relaxation, does cause sexual dysfunction.

Impact of Prolapse Repair on Sexual Function

Most recent studies evaluating different prolapse repair procedures are now focusing more closely on the impact of the procedure on sexual function. In the past, this did not seem to be a very important factor, but most now realize it is a critical component of any repair. Many new procedures, for example, vaginal mesh repairs, are under the microscope concerning their impact on sexual function. However, it is interesting that when compared to historical “accepted” procedures without mesh, the rates of sexual dysfunction with mesh repairs are the same or less and have higher cure rates (14–16). Because of this, there does seem to be more data recently regarding the sexual function aspect of prolapse repair and most studies are finding a positive impact in this regard. Srikrishna et al. evaluated this concept and found that 83.6% of women presenting for prolapse surgery list improved sexual function as part of their goal for surgery (17). This clearly indicates that when asked, women with prolapse are stating the prolapse has affected their sexual function and they would like it to be improved with their repair. They found significant improvement in sexual function after the prolapse repair was completed. Azar et al. utilized the Female Sexual Function Index, another validated questionnaire, to evaluate women before and after surgery for prolapse and also found that sexual function was improved post-operatively after repair of the prolapse (18). Two studies have found improvements in PISQ scores after prolapse repair (19,20). Stoutjesdijk et al. also found a significant improvement in dyspareunia and increased frequency and satisfaction with intercourse after vaginal reconstructive surgery (21). These findings were also recently confirmed by Rogers et al. in a multicenter prospective study evaluating sexual function after surgery for prolapse and/or incontinence with improved sexual function scores after repair (19).

We feel that the posterior vaginal wall anatomically controls most of the vaginal caliber secondary to its relationship to the levator ani and genital hiatus and repair of this wall is a major portion of most rejuvenation type procedures. Therefore, studies evaluating rectocele repairs may have more of a direct correlation to vaginal caliber and sexual function. Tunuguntia and Gousse, in a review of female sexual dysfunction following vaginal surgery, found that while posterior repair with levatorplasty leads to sexual dysfunction and pain in many women, that actually posterior colporrhaphy completed alone, with the avoidance of levator ani plication, improves sexual function (22). Komesu et al. evaluated the effect of posterior repair on sexual function on women that underwent prolapse and/or incontinence either with or without a posterior repair and found that women with posterior repair had improvements in sexual function on PISQ scores (23). Paraiso et al. compared three different methods of posterior rectocele repair including one that utilized a graft and found that all three approaches resulted in statistically significant improvements in sexual function, again utilizing the PISQ questionnaire (24).

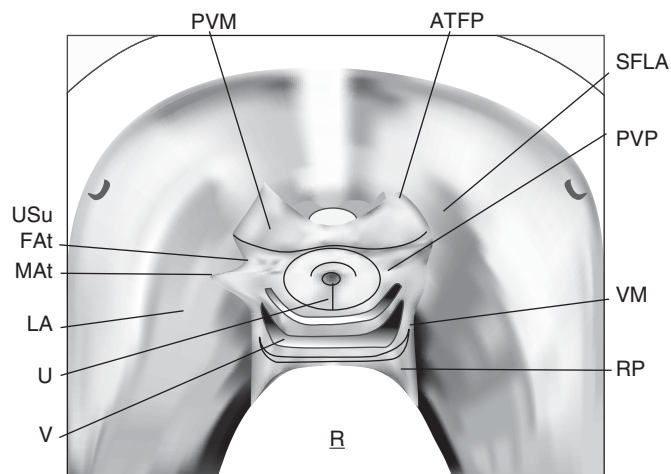


Figure 104.1 Cross section view of the vagina and pelvis, showing connection of vaginal connective tissue out to the levators and the role of both in vaginal caliber. Abbreviations: PVM, pubovesical muscle; ATFP, arcus tendineus fasciae pelvis; SFLA, superior fascia of levator ani; PVP, paraurethral vascular plexus; VM, vaginal wall muscularis; RP, rectal pillar; R, rectum; V, vagina; U, urethra; LA, levator ani; MA, muscular attachment; FA, fascial attachment; USu, supportive tissues of urethra.

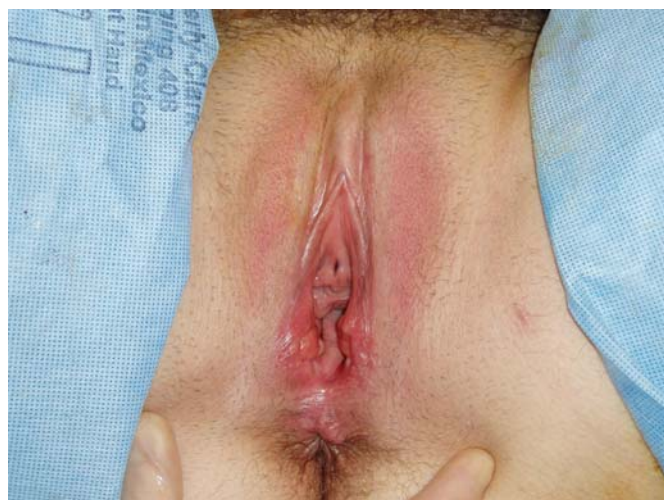

Figure 104.2 Picture of damaged introitus and perineal body. Source: Courtesy of Robert D Moore and John R Miklos.

Vaginal Relaxation and Effect on Sexual Function and Sensation

It is clear from the above data that prolapse has a role in creating sexual dysfunction and its repair can improve sexual function. However, sexual function and dysfunction are multifactorial. Does sexual function occur because of the prolapse creating discomfort causing the woman to avoid intercourse, or because of self-image issues regarding the prolapse? Does vaginal relaxation and prolapse cause decreased sensation leading to sexual dysfunction, that is, feeling less, or does it result in a woman feeling self-conscious about the fact that she feels her vagina is loose, stretched out or relaxed? We can look at some basic anatomy and function of the vagina in its relation to sensation, orgasm, and sexual function and to try to answer these questions.

Ozel et al. recently published one of the first reports evaluating libido, sexual excitement, vaginal sensation, and ability to orgasm in a group of women with prolapse compared to women without prolapse. They found that women with prolapse and vaginal relaxation were significantly more likely to report an absence of libido, lack of sexual excitement during intercourse, and a much lower frequency of achieving orgasm during intercourse (all statistically significant) compared to women with the same demographics without prolapse (i.e., multiparous, similar age, marital status, etc.) (25).

The reasons why vaginal relaxation and prolapse may affect sensation are likely multifactorial and difficult to assess. It has been shown that when voluntarily contracted, the pelvic floor muscles can intensify orgasms for women (26). Decreased sensation and difficulty achieving orgasm may be secondary to nerve damage from childbirth, muscular changes, soft tissue changes, and to date we have no way of studying or confirming the exact cause prior to surgery. It also just makes logical sense that vaginal caliber can affect vaginal sensation. This has been studied and it has been shown that vaginal tone affects vaginal sensation and the ability to orgasm (27). Tone is comprised of two variables, levator muscle tone, and the elasticity of the vaginal tissues attached to the muscles. The vaginal caliber is directly related to the elasticity of the endopelvic fascia surrounding the vaginal canal and the tone of the levator ani muscles that the tissues are attached to. If the levator muscles are atrophied this affects the overall pressure that the vagina can produce. Similarly, if the vaginal support tissues that are attached to the muscles are stretched out, damaged, or disconnected from the levators (i.e., at the white line or the arcus) this will also effect vaginal tone and size, which ultimately can affect vaginal sensation and the ability to achieve orgasm. Kline utilized a perineometer to evaluate vaginal tone and control (woman's ability to create a sustained contraction and create vaginal tone) and showed that women with decreased tone or levator atrophy had a more difficult time reaching coital orgasm and, if reversed, the women's ability to achieve coital orgasm returned. It can be clearly seen in the cross-section view of the pelvis (Fig. 104.1), that the vaginal canal is attached out laterally to the levators and when the levators contract, the vaginal caliber is reduced and pressure increased. Some argue that Kegel exercises alone can achieve this in a patient with decreased vaginal tone, and this certainly can be true in patients with true levator tone, and this certainly can be true in patients with true levator atrophy. However, in woman that the endopelvic fascia is stretched out beyond its elastic capability to recover or not attached to the levators at all, the levators, no matter how strong, cannot overcome this and create a taught vaginal canal, and this will affect vaginal sensation.

It is not clear how much vaginal relaxation is required to cause decreased sensation or sexual dysfunction. If women do have a sense of a relaxed or loose vagina that is causing them to have sexual dysfunction prior to them having any of the traditionally described symptoms of prolapse, i.e., feeling or seeing a bulge, incontinence, voiding dysfunction, or bowel dysfunction, will a repair of the caliber of the vagina reverse these changes and improve sexual function? We may see women present with a damaged perineal body from episiotomy or laceration during childbirth and a relaxed vaginal canal that does not have significant anterior or posterior prolapse (Fig. 104.2).

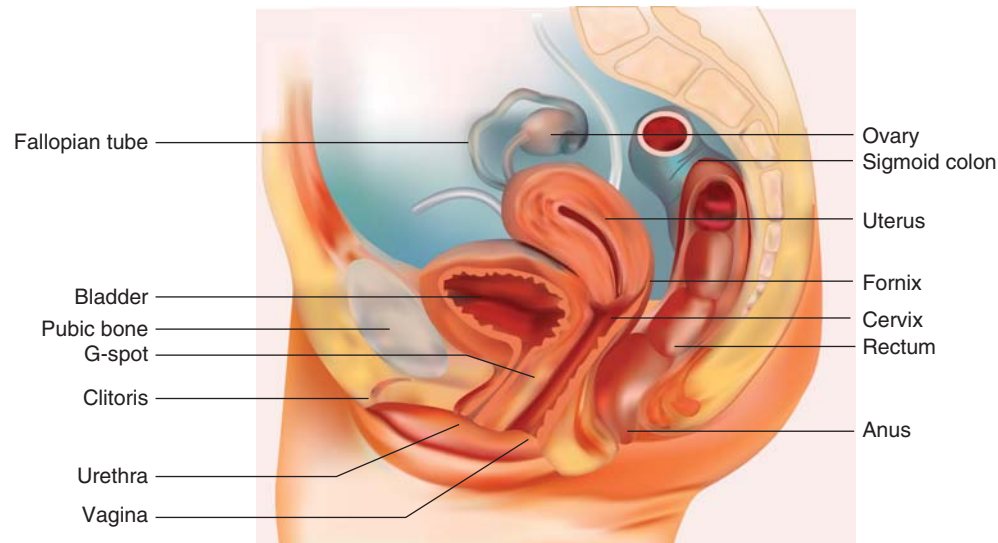


Figure 104.3 Location of g-spot on anterior wall of vagina.

These patients may complain that their vagina feels wide open or that it feels very loose and relaxed, has and that there is less sensation during intercourse, and coital orgasm cannot be achieved. In the past, we would often turn these patients away because their only symptom was sexual dysfunction and they did not have true prolapse and therefore did not have indication for surgical repair. We were ignoring one of the major aspects of quality of life in a couple's relationship, which is sexual function. This is what vaginal rejuvenation is all about, completing a vaginal repair of a relaxed vaginal opening and vaginal canal for sexual function and the woman's subjective symptoms of feeling as if her vagina is loose and/or wide open.

Vaginal Sensation, the G-Spot, and Vaginal Caliber

Despite some controversy over this subject, researchers have found evidence that a sensitive area called the g-spot, named after Ernst Grafenberg (28), exists in the vaginal canal, typically located on the anterior vaginal wall. This has been studied and described sometimes as an area that lies beneath the posterior part of the "female prostatic gland" and therefore typically found 2 to 3 cm inside the introitus on the anterior vaginal wall in the region of the bladder neck. When stimulated the area becomes engorged, enlarged, "bumpy," and very sensitive and stimulation of this area alone may induce orgasm (Fig. 104.3). Recently, in a study evaluating the thickness of the urethrovaginal space in women with or without vaginal orgasm, it was found that there was a direct correlation of the thickness of this space (i.e., the g-spot) and the presence or absence of vaginal orgasm (29). Masters and Johnson, on their studies of orgasm, argued that clitoral stimulation was the source of all orgasmic response. They did not deny the possibility of vaginal sensitivity, they merely overlooked it (30) and considered the vagina as merely a passive receptacle for the male organ and ejaculate. Vaginal sensitivity and the possibility of another sensitive spot, in addition to the clitoris, was made more aware during studies of female ejaculation in the late 1970s. Sevely and Bennett initially described this "female prostatic gland" as the source of fluid that some women expel

during orgasm. The area identified by their research subjects as the "trigger point" for their ejaculations, was the same area described initially by Grafenberg. They confirmed Grafenberg's observation that this sensitive area could be located on the anterior vaginal wall, typically midway between the pubic bone and the cervix, on or near the urethra, and when stimulated it can lead to orgasm. They trained physicians in their technique, and in a study of 250 women these physicians were able to locate the spot in all 250 patients (31). Mould confirmed this in several studies by measuring electromyography responses in the vaginal canal and the levators during stimulation of this area and subsequent orgasmic response (32). His and other studies have clearly shown that there is sensation in the vagina itself and a nerve pathway that plays a role in sexual stimulation and satisfaction and that if altered, may impair sexual function.

Vaginal caliber, size, and tone all may have a role in sexual sensation, stimulation, and orgasmic response. After vaginal childbirth, as with women with true pelvic organ prolapse, many women report decreased sensation vaginally with intercourse and difficulty reaching orgasm which may lead to sexual dysfunction and sexual discontentment. Perry and Whipple, in vaginal myography studies, have shown the average women is able to register a 10 second sustained contraction on myography of 8.77 mV. They studied women with stress urinary incontinence and found they could only register between 2 and 4 mV (33). Now this could have been secondary to atrophy of the levators, or they may have had associated relaxation or prolapse of the vaginal support structures leading to these lower readings. They assumed that if a woman could not improve these contractions, that she was not being compliant on the exercise routine; however, they do not address whether or not it may have been associated with relaxation of the walls of the vagina themselves or if the patient had a cystocele or rectocele present. It stands to reason that in a woman with a larger caliber vagina, from relaxation of the vaginal walls, that there will be less sensory input with vaginal intercourse and penile penetration, even with levator muscles that have

adequate tone and no atrophy. It is the vaginal walls themselves that are stretched out or torn away from the levators, causing the larger caliber vaginal canal. This will lead to less contact, friction, and ultimately less stimulation of the vaginal walls and to the g-spot itself, which again will result in orgasmic and sensory dysfunction. The g-spot needs direct stimulation from the penis during intercourse to become aroused and if the caliber of the vagina is large or relaxed, this may not be possible. Vaginal size may also effect the woman's partner to achieve orgasm, which again can lead to sexual dysfunction and dissatisfaction not only for the partner, but for both partners.

The theory that vaginal size is related to sexual sensation has been recently confirmed by Pardo et al. in a recent study on a group of women that presented with symptoms of a wide or relaxed vagina and were interested in vaginal repair for sexual function alone. The women had no symptoms of prolapse or incontinence. Inclusion criteria included a sensation of a wide or loose vagina alone in combination with a decrease or lack of ability to reach orgasm. Exclusion criteria included symptomatic prolapse (cystocele, rectocele, or vault/uterine prolapse), dyspareunia, primary anorgasmia, or psychologic impairment (all patients had psychological evaluation). Fifty-three patients were included in the study and 96% of the patients experienced decreased vaginal sensation, 73% described difficulty achieving orgasm, and 27% could not reach orgasm. All but two patients had previous vaginal deliveries. Following surgical repair of the vaginal caliber and tightening of the vagina itself, 90% of women reported their sexual satisfaction was much or sufficiently improved and 94% of women were able to reach orgasm (34). This confirmed that vaginal size has a direct impact on sensation and ability to orgasm and when repaired sexual function improves.

Vaginal Rejuvenation—Surgical Techniques

Importance of Proper Evaluation and Diagnosis

It cannot be stressed enough about the importance of a proper pre-operative evaluation of a patient that presents with an interest in surgery to repair what she conceives is a loose or relaxed vagina and would like it tightened to for sexual enhancement or to correct the feeling of having a "wide-open" vagina, i.e., vaginal rejuvenation surgery. This includes proper medical history, psychosocial evaluation for sexual dysfunction, and/or sexual satisfaction prior to any of the anatomical changes she may have noted since childbirth. Marital or relationship issues or concerns and an evaluation of her expectations of surgery and the reasoning why she is interested in the procedure should be discussed as well. It is true that most women that present to our clinic had a very satisfactory sexual life and then experienced a major change subsequent to their pregnancies and deliveries or gradually by aging. However, sexual dysfunction is very complex and multi-factorial and of course a surgical procedure to repair vaginal support and reduce the vaginal caliber, will not reverse or change psychologic or psychosocial sexual dysfunction arising from previous abuse, primary anorgasmia, relationship issues, depression, or other more complex psychologic dysfunction.

We have found that most women presenting for this type of surgery do not have this type of dysfunction at all. They present and state: "Since the birth of my child or children, my vagina, and sex life has not been the same. I had a tear and my vagina never returned to the size it was before children and this has affected my sex life as my vagina feels very loose or wide and I have less sensation and difficulty reaching orgasm which makes my partner and I frustrated." We also find that most women have done Kegel exercises and have not found any improvement with this and therefore present for a possible surgical solution. There will, however, be women that present with psychologic issues that need to be addressed and are not deemed surgical candidates. We have found that when women are well educated and informed and have reasonable expectations, the success of any surgery is much higher.

In addition to a medical and psychosocial history, an adequate urogynecology history, and physical exam must be completed. Sexual dysfunction related to a sense of a relaxed or loose vagina may be the first sign of the beginning stages of pelvic floor dysfunction and prolapse, therefore an adequate history must be taken. We have found that as many as 50% to 75% of patients that present for vaginal rejuvenation, when asked, have symptoms including urinary incontinence, voiding dysfunction such as overactive bladder or difficult emptying, feelings of pressure or the sense that their organs are falling, defecatory dysfunction, or dyspareunia related to the uterus being hit during intercourse because of prolapse. It is vitally important to have an adequate understanding of the symptoms that prolapse can cause and we use validated questionnaires such as the UDI-6, IIQ-7, and the PISQ-12 to evaluate patients for these symptoms as well as a general urogynecologic history form. If significant symptoms of urogynecologic pathology are present, this must be evaluated pre-operatively so that it can be addressed properly during surgery.

We have also found that as many as 75% of patients that present for vaginal rejuvenation are found to have true prolapse on exam, either cystocele, rectocele, uterine/vault prolapse or a combination of findings and therefore this of course is their major pathology and is what is leading to the sense of a relaxed vaginal canal. They do not need vaginal rejuvenation, they need true pelvic reconstructive surgery. This is why a proper urogynecologic exam in the supine and standing positions with a proper POP-Q evaluation is necessary to assess for overall pelvic floor support. Again, it is vital to properly diagnose any pelvic floor prolapse prior to any surgical procedure of the vagina, as vaginal rejuvenation or repair of the opening and caliber of the vagina, will not repair a prolapsed uterus, a significant cystocele/rectocele, or urinary incontinence. We stress to patients that the foundation of support must be corrected and intact prior to any repair of the caliber of the vagina or the opening. We have seen many women, from other institutions, that had a "vaginal rejuvenation" procedure completed and find that they still feel as things are not right or feel like something has dropped in their vagina. On examination, we find that they have complete uterine prolapse, which most likely was present and not recognized nor addressed at the time of their initial procedure. For these reasons we believe that experts in

vaginal reconstructive surgery should be responsible for any and all vaginal repairs, including vaginal rejuvenation. Not only for the surgical skills required, but also to have the experience to make a proper diagnosis to determine what exactly needs to be done at the time of surgery.

Surgical Procedures

As stated above, the surgical procedure required is determined by the patient's physical exam. Again, most women that present interested in vaginal rejuvenation type surgery, or surgery to correct a feeling of a loose or wide vagina, are found to have prolapse in the form of cystocele, rectocele, or uterine/vault prolapse. In most instances it is POP-Q stage II or less, however it is present and must be repaired. This is what determines what surgery will need to be done as the prolapse must be corrected first, prior to any rejuvenation procedures being completed and is really the first step in an overall repair or "rejuvenation" of the vagina and pelvic floor. The below case study is a typical presentation of a woman that presents to our center for vaginal rejuvenation.

Case Study

A 40-year-old woman, G2P2, presents for vaginal rejuvenation surgery. She states that since the birth of her children, her vagina feels very loose and relaxed. She states that she has less sensation vaginally and although still coitally orgasmic, it takes her much longer and many times the orgasms are not as intense or she does not reach orgasm. She states prior to her deliveries, this was not the case as she was able to have vaginal orgasms with intercourse very easily. She feels that the opening of her vagina is gaping and she does not have any grip or squeeze of the penis upon entry, which she used to have. She has gone for pelvic floor physical therapy and has been doing kegel exercises for several years and although the therapist has deemed her to have good levator tone and control, this has not improved her situation. With further questioning, she also states that she has pain with deep intercourse that has been present for the last year. She states it feels as if her partner is hitting something with deep penetration and this causes her significant pain at times. She feels very self-conscious about her vaginal relaxation and although her husband has never said anything to her, she feels that he notices a difference as well. She denies any urinary symptoms including incontinence and also denies any bowel dysfunction.

On exam, the patient is found to have a cystocele to the introitus, a retroverted uterus with cervical prolapse within 3 cm of the introitus and a mild rectocele with significant relaxation of the introitus secondary to perineal muscle damage resulting from childbirth. She has excellent levator tone and good control of her levators.

The above case typifies how many women present interested in vaginal rejuvenation. This patient does not need just a vaginal "nip and tuck" and it would be a disservice to offer her this type of procedure. She might, however, benefit from pelvic reconstruction including cystocele repair and uterine suspension to restore her foundation, prior to repairing or reducing the caliber of the vagina and introitus for the purpose of enhancing vaginal sensation and sexual function.

Repairing Prolapse First

As already stated, vaginal rejuvenation procedures are alterations of vaginal repairs that we are already completing; however, they do become more involved and more attention is paid to the final diameter of the vagina and the opening of the vagina. However, prior to this, the first step in the procedure is correcting any prolapse that exists.

Anterior Vaginal Wall

If a significant cystocele is found on exam, this needs to be repaired with standard techniques. We feel that a cystocele that is stage II or larger, should not be repaired vaginally, as a traditional anterior repair is a compensatory procedure, with cure rates only in the range of 50% and can shorten the vagina. Most cystoceles are caused by paravaginal defects and as they get larger, we feel that a proper repair should be done via a paravaginal defect repair (Fig. 104.4A–C). This can be completed vaginally, however we feel a laparoscopic or abdominal approach is much more anatomic and the defects can be repaired with direct visualization. We have shown that over 94% of women presenting with cystoceles or stress incontinence, have paravaginal defects identified during laparoscopic exam. Repairing the defects laparoscopically allows the cystocele to be repaired with anatomic restoration of the anterior vaginal wall and maintain normal length. Additionally, no incision is made on the anterior wall, theoretically, avoiding dissection in the region of the g-spot and preserving the nerves to the area.

Uterus and/or Vaginal Vault

If uterine prolapse or vault prolapse is present (Fig. 104.5), this again needs to be addressed as part of the surgery. One could argue that the vaginal canal could be entirely treated via a vaginal approach and repair of the canal alone, however if uterine/vault prolapse is present, this is not treated at all by rejuvenation or any vaginal repair. The vault is the anchor of the entire pelvic floor system and this is why most patients present with recurrences after pelvic floor surgery, i.e., the vaginal vault was not either diagnosed as having a deficit or not addressed during the repair. Patients frequently present with failure after anterior/posterior repair for prolapse and think they have a recurrent cystocele, when indeed they have vault prolapse causing the defect. In a younger woman presenting for rejuvenation or for sexual dysfunction secondary to feelings of a relaxed vagina, the vault must be adequately supported. If vault or uterine prolapse is found it must be treated.

Many younger women presenting for vaginal rejuvenation are not ready for hysterectomy and wish to retain their uterus. Many are actually shocked to hear that their uterus is almost prolapsing out of the opening of the vagina and therefore have not prepared themselves psychologically about the possibility of needing a bigger surgery or a hysterectomy, nor are they ready to have their uterus removed therefore creating permanent sterility. It is for these reasons, that uterine suspension is a viable option for these patients that have no other uterine pathology except prolapse. We have found that in women with true uterine prolapse, mesh must be used to achieve adequate

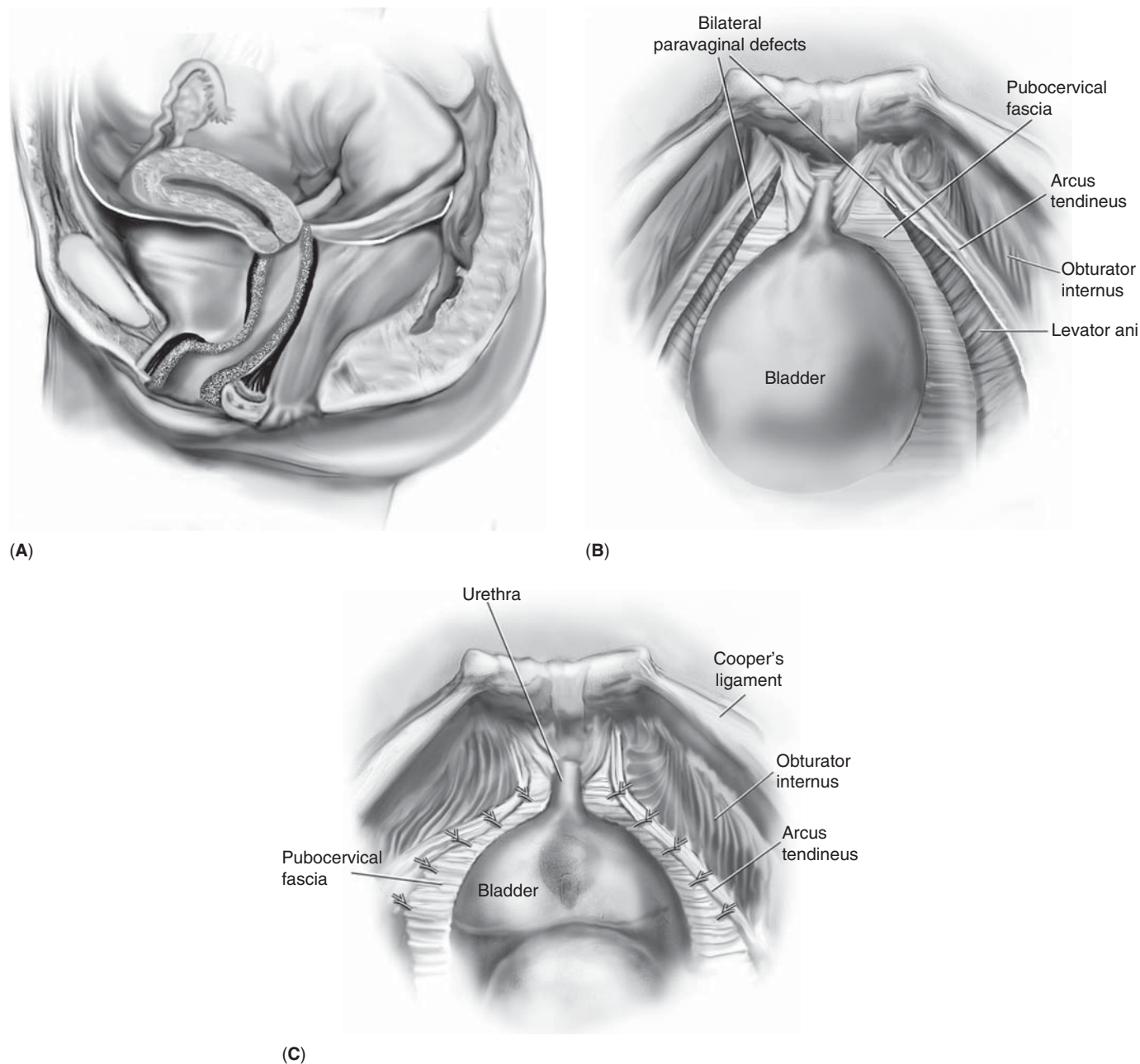


Figure 104.4 (A) Cystocele, (B) paravaginal defects, and (C) laparoscopic repair. Source: Courtesy of Robert D Moore and John R Miklos.

support and an acceptable long-term cure rate. Many times with uterosacral and round ligament plication, we cannot elevate the uterus up high enough in the canal and the long term cure rates are poor when using this technique. We have been utilizing laparoscopic sacrohysteropexy (Fig. 104.6A–C) in these type of patients. It is a minimally invasive alternative to achieve excellent uterine support and minimize risks of recurrence. Alternatively, if the patient wishes for hysterectomy and/or there is other uterine pathology to consider, then hysterectomy in combination with vault suspension is a viable option. We typically will complete laparoscopic assisted vaginal hysterectomy (leaving the ovaries in situ in younger women), in combination with laparoscopic uterosacral suspension or laparoscopic sacralcolpopexy (Fig. 104.7A and B) to support the vault, prior to repair of the vaginal canal.

Rejuvenation of the Vaginal Canal and Introitus

Repair of the posterior vaginal wall and the introitus are the key aspects to any vaginal rejuvenation procedure. Vaginal rejuvenation surgeries are alterations and modifications of vaginal repairs for prolapse that focus on the final diameter and caliber of the vagina and attempt to restore it back to its pre-childbirth state. They however do go far beyond the simple traditional posterior repairs and perineoplasty of old. The focus of these older procedures is simply to restore and reduce the bulge, whereas the focus of vaginal rejuvenation is to restore the caliber of the vagina and genital hiatus back to pre-childbirth state from the introitus all the way up to the apex. They are much more extensive and meticulous procedures. No drop-offs or dips should be felt and there should be no tension placed on the levators that causes lateral banding of the vagina.

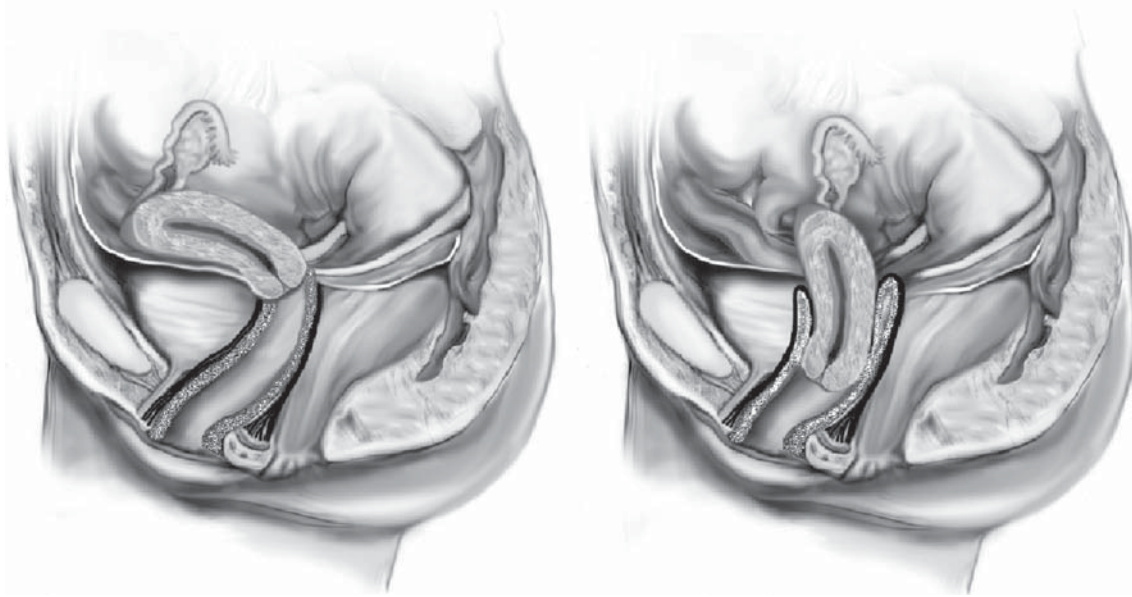


Figure 104.5 Uterine prolapse—normal and side view of prolapse. Source: Courtesy of Robert D Moore and John R Miklos.

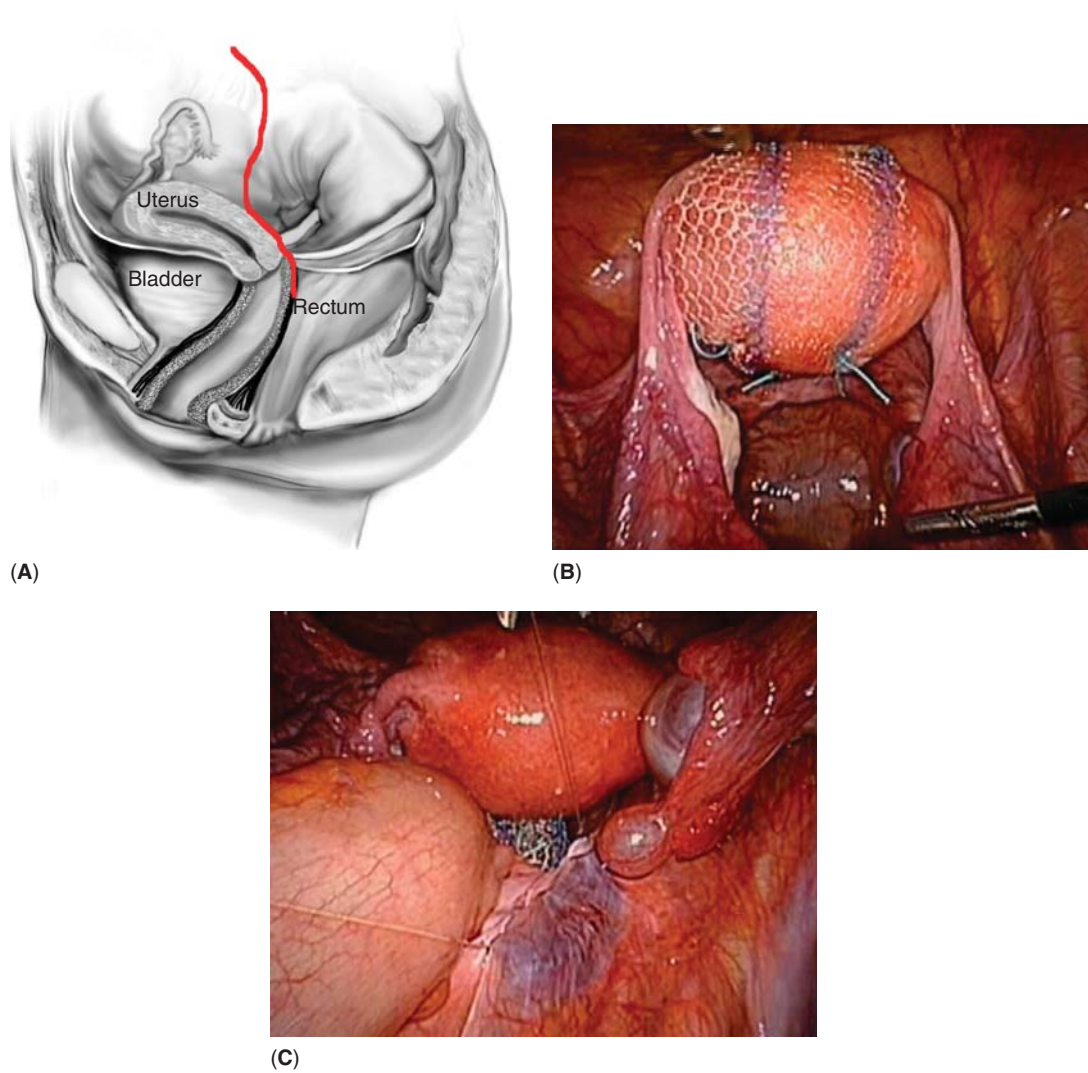


Figure 104.6 Uterine suspension with mesh: (A) lateral view of pelvis depicting mesh (in red) suspending uterus and top of vagina to presacral ligament (mesh sacrohysteropexy); (B) laparoscopic view of mesh sutured to lower uterine segment; (C) closure of peritoneum over mesh following attachment of mesh to presacral ligament. Source: Courtesy of Robert D Moore and John R Miklos.

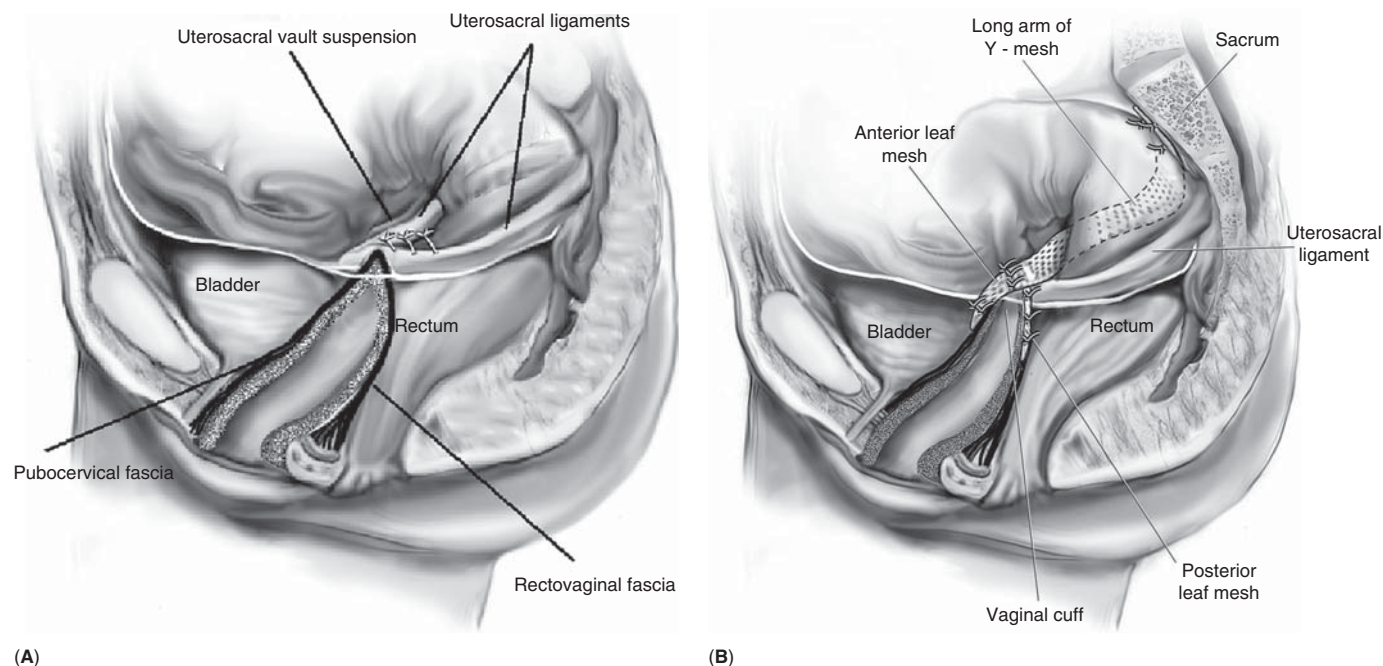


Figure 104.7 Laparoscopic uterosacral vault (A) and sacralcolpopexy (B)—side views. Source: Courtesy of Robert D Moore and John R Miklos.

Additionally, the cosmetic appearance of the introitus and perineal body is also taken into account and requires an intricate dissection and repair to not only restore function of the introitus, but also obtain an appearance that the woman is desirous of. That look is of the vaginal opening being closed, not gaping, or wide open with a normal length perineal body that does not bulge out following the repair. This look is sometimes difficult to obtain, without making the introitus too tight, which will cause pain with intercourse.

Posterior Wall, Introitus, and Rejuvenation

The posterior vaginal wall is the focus of any vaginal rejuvenation procedure. In a woman with a mild cystocele or mild relaxation of the anterior vaginal wall, a small anterior colporrhaphy (Fig. 104.8) can be completed to take care of this prior to repair of the posterior wall. However, one needs to be very careful with this as if the repair of the anterior wall is too aggressive, it will lead to lateral banding and constriction of the vagina, before the posterior wall is even started.

An incision is made at the introitus, typically in trapezoid pattern that will also be used in the perineoplasty portion of the procedure. A small incision is then made in a vertical fashion on the posterior wall and the vaginal epithelium is dissected off the underlying rectovaginal fascia all the way laterally out to the levators. The dissection must be taken all the way up to the apex of the vagina, as the repair needs to incorporate the entire posterior wall to restore the caliber of the full length of the vagina. If a rectocele is present, the fascia is repaired in a site-specific fashion with delayed absorbable suture. The caliber of the vagina is then addressed by plication of the rectovaginal fascia in the midline with delayed absorbable sutures. Levator plication is avoided; however, the diameter of the vagina is constantly measured and several layers of plication may be needed to reduce the genital hiatus and reduce the

caliber of the vagina to an appropriate level. A small amount of vaginal epithelium is then excised and the incision closed in a running fashion.

A perineoplasty is then completed, involving a very meticulous and detailed dissection out laterally to obtain the lacerated edges of the deep and superficial transverse perineal muscles and bringing them back together in the midline to achieve uniformity at the same level of the posterior wall repair. The inferior edges of the labia majora that will make up the posterior forchette of the vaginal opening must be marked at the beginning of the procedure so that these edges match up during the closure to form the vaginal opening. An appropriate amount of skin must also be excised from the perineum and introitus to result in a cosmetically pleasing appearance of the opening of the vagina for the patient. A multilayer (typically this may involve 4 or 5 layers) is completed at the perineum and introitus (Figs. 104.9 and 104.10).

When a repair is primarily for repair of vaginal relaxation for sexual function it becomes a much more meticulous dissection and repair as the surgeon has to constantly be judging and measuring vaginal caliber to try to restore the entire vaginal length to its pre-childbirth state. If this is not done, then the results will be poor and the patient's sexual function may not change or they will be worse secondary to pain, vaginal shortening, scar tissue formation, and/or constrictions.

Laser Vaginal Rejuvenation

Laser vaginal rejuvenation was originally described by David Matlock, a gynecologist, and is a modification of the above procedure that utilizes a laser in the repair of the caliber of the vagina to improve sexual gratification. Many of his techniques utilizing the laser are trademarked and patented, therefore we are not at will to discuss the details of the surgeries in the current chapter. He does utilize modifications of traditional vaginal

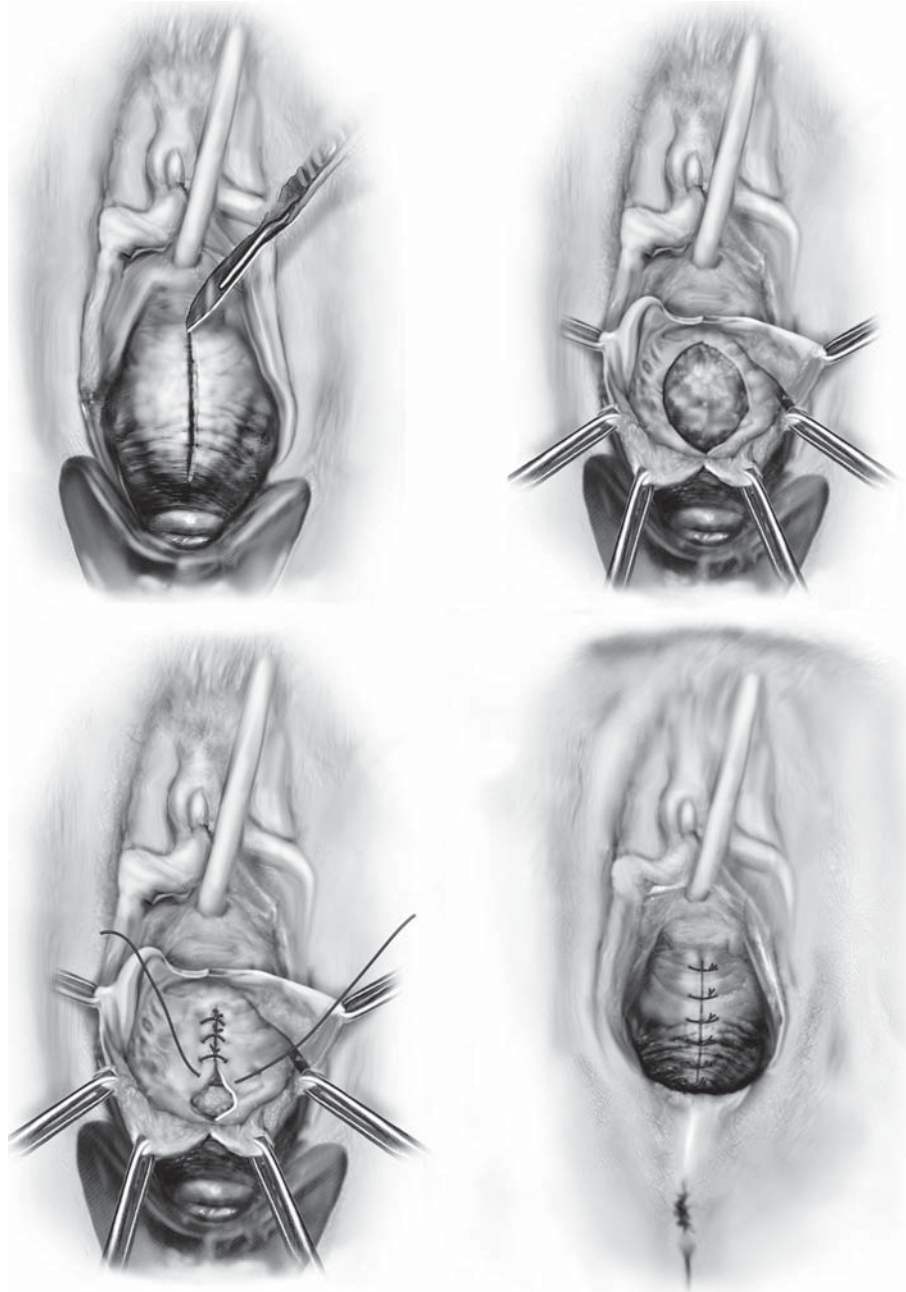


Figure 104.8 Anterior repair drawings. Source: Courtesy of Robert D Moore and John R Miklos.

repairs, but considers the laser procedures to be much more in-depth and detailed than traditional repairs. He feels that his techniques that utilize the laser in the repairs decreases morbidity, is less invasive, creates less scarring and results in optimum vaginal caliber, and sensation for sexual function and enhancement. We have also incorporated some of his techniques into many of our repairs and do agree with his findings to date.

Post-operative Care

Routine post-operative care is given to patients undergoing vaginal surgery. Many of the procedures are completed on an outpatient basis and the surgery is completed under spinal or general anesthesia. Vaginal packing is left in for a short period

of time and removed prior to the patient being discharged. Routine instructions for vaginal surgery are given to the patient and they are seen in follow-up at four weeks post-operatively. The vaginal introitus and caliber is assessed and if felt necessary the patient will begin perineal massage in a warm water bath for one to two weeks prior to resuming sexual relations.

Clinical Data on Results of Vaginal Rejuvenation Surgery

Pardo et al. have published the only clinical data on repair of vaginal caliber for sexual function. They reported on a group of 53 women that underwent colpoperineoplasty for a sensation of a wide vagina and secondary loss of sexual satisfaction secondary to this. Patients that were found to have prolapse, that is, a cystocele, rectocele, or vault prolapse were not

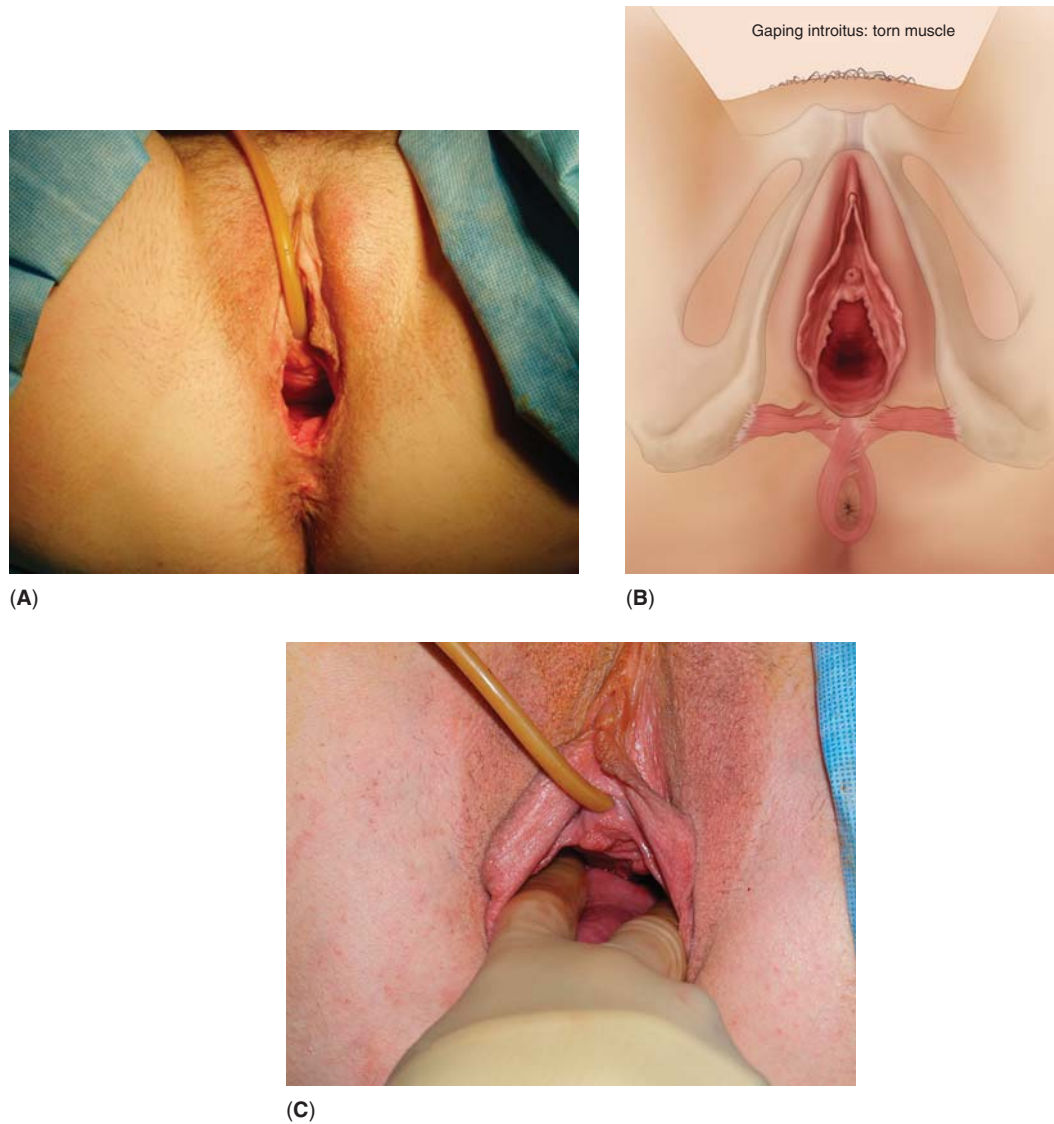


Figure 104.9 (A–C) Relaxed introitus and vaginal canal. Source: Courtesy of Robert D Moore and John R Miklos.

included in the study, therefore maintaining a very select study group of patients that had a previously satisfactory sexual life but noted major changes following vaginal childbirth and/or aging. They were also screened for psychosocial disorders and any patient that revealed personality upheavals or classic sexual dysfunction such as vaginismus, dyspareunia, primary anorgasmia, and/or sexual partner dysfunction were not considered candidates for the treatment. They found that after colpoperineoplasty, utilizing a Yag laser in their dissection, as well as other techniques described by Matlock, that 90% of the women had much or sufficiently improved sexual activity and 95% had their expectations partially or completely fulfilled by the surgery. No patient reported worsened sexual function; however, 4% of patients reported regretting undergoing the procedure (34). In a follow-up study, they confirmed their findings in a second group of patients as well (35).

Goodman et al. led a recent multicenter U.S. study on women undergoing female genital plastic surgery including vaginoplasty/perineoplasty for vaginal relaxation affecting sexual function. The authors of this chapter were one of the centers

involved in the study. Pre-operatively 83% of women reported their sexual function was fair/poor. Postoperatively it was found that 84% of 69 women following vaginoplasty/perineoplasty for sexual function reported enhanced sexual function following repair with only 2% reporting a negative effect on sexual function, confirming repair of the vaginal caliber may lead to improved sexual function in women presenting with relaxation (36).

Conclusion

Vaginal rejuvenation surgery is one of the latest trends in elective vaginal surgery for women. It is a repair of the vaginal caliber in women that suffer from decreased vaginal sensation or of feelings of a loose or wide vagina that affects their sexual life. In many instances, women that present with these symptoms are found to have other urogynecological pathology such as prolapse that must also be addressed in any repair contemplated. Sexual dysfunction or decreased sexual sensation may be one of the first symptoms that women suffer from in the progression of prolapse and therefore a proper exam is vital

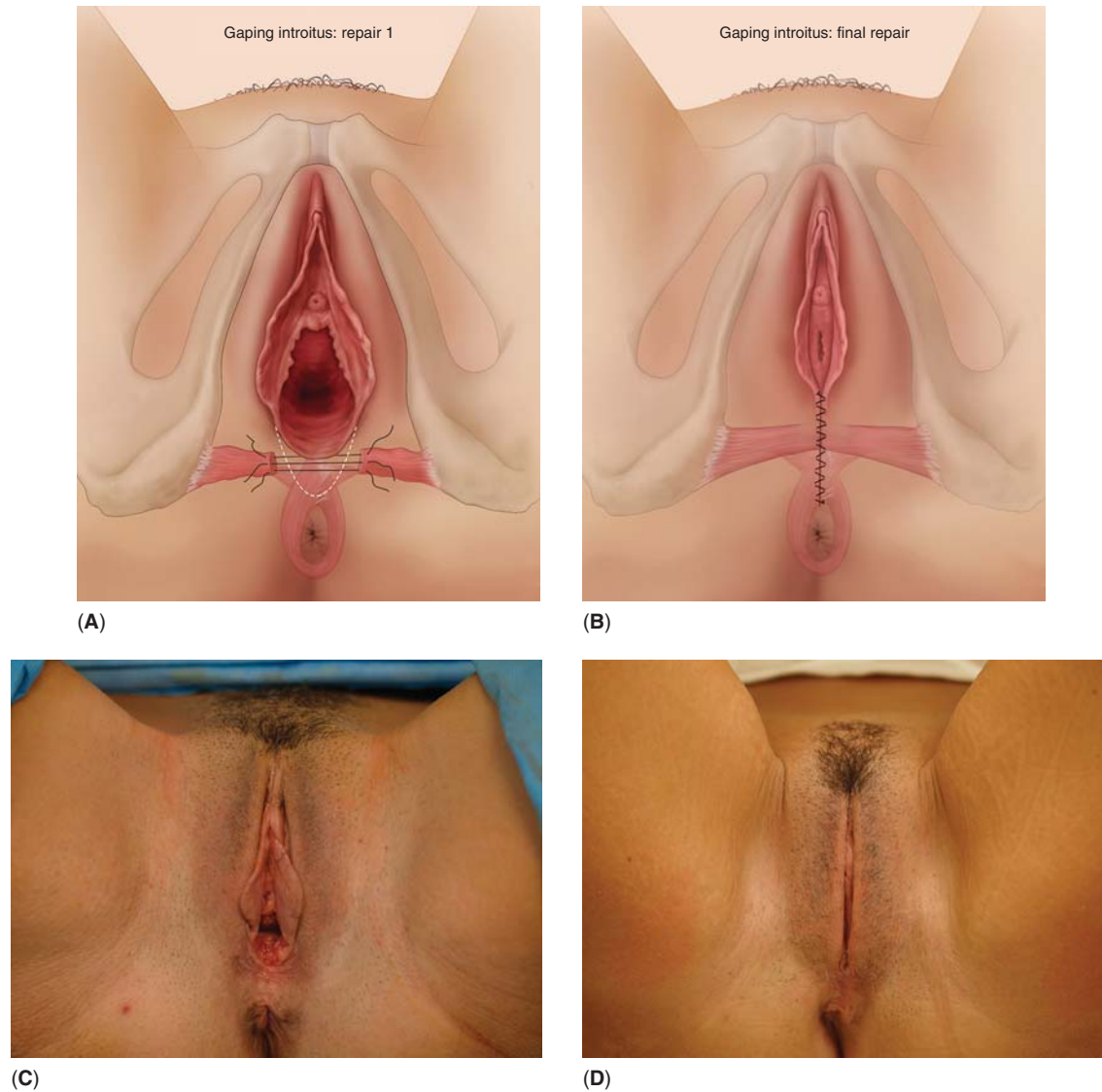


Figure 104.10 Before (A–C) and after (B–D) perineal body repair. Source: Courtesy of Robert D Moore and John R Miklos.

prior to any repair. We have ample evidence that prolapse and vaginal relaxation can create sexual dysfunction and that repair may reverse these changes in many women. However, when dealing with sexual dysfunction alone and the caliber or width of the vagina, the surgical repair must be very meticulous and exact in order to enhance sensation and function and not impair it. This sums up the statement “The Art of Surgery!”

COSMETIC VAGINAL SURGERY

Aesthetic Surgery of the External Vagina and Vulva

Introduction

There have been many studies and research on the relationship between a woman’s body image and her sexual function. However, little research exists on the relationship between a woman’s genital image and her sexual function. Realizing one’s genital image is part of one’s body image, it is easy to understand how many women might feel sexually inhibited if they are not comfortable with appearance of their vagina, vulva, or external genitalia. A survey of 3627 women found that women with

positive body images reported more sexual activity, initiation of sexual activity, orgasm, sex with lights on, and greater comfort undressing in front of their partners, trying new sexual behaviors, and pleasing their partner (37).

Cosmetic vaginal surgery is currently steamrolling its way into mainstream culture. However, as with every new trend, there are always those who oppose change. There have been many negative comments and editorials written suggesting that both the doctors and the patients should not be pursuing cosmetic vaginal surgery (38–40). Many of those who imposingly opine are often ignorant of the patient and their disposition as well as their medical conditions and their associated symptoms (41). Patients can suffer from a variety of physical and emotional symptoms. Physical symptoms are usually associated with wearing certain types of clothing, engaging in activities such as walking, jogging, exercise, and bicycling and finally intercourse. Yet other patients are afflicted with emotional problems such as embarrassment, anxiety, and a loss of self-esteem.

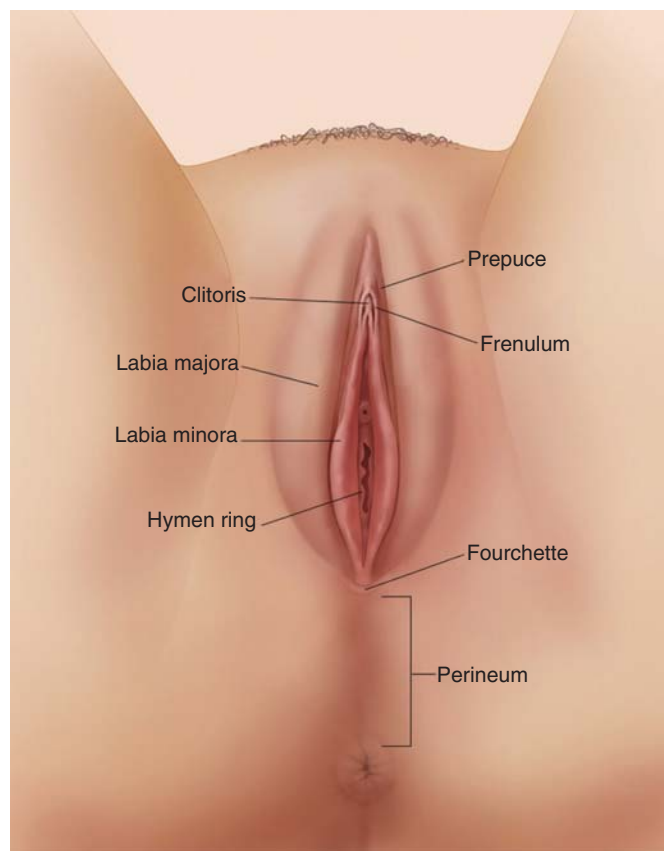


Figure 104.11 Normal anatomy of vulva and external vagina. Source: Courtesy of Robert D Moore and John R Miklos.

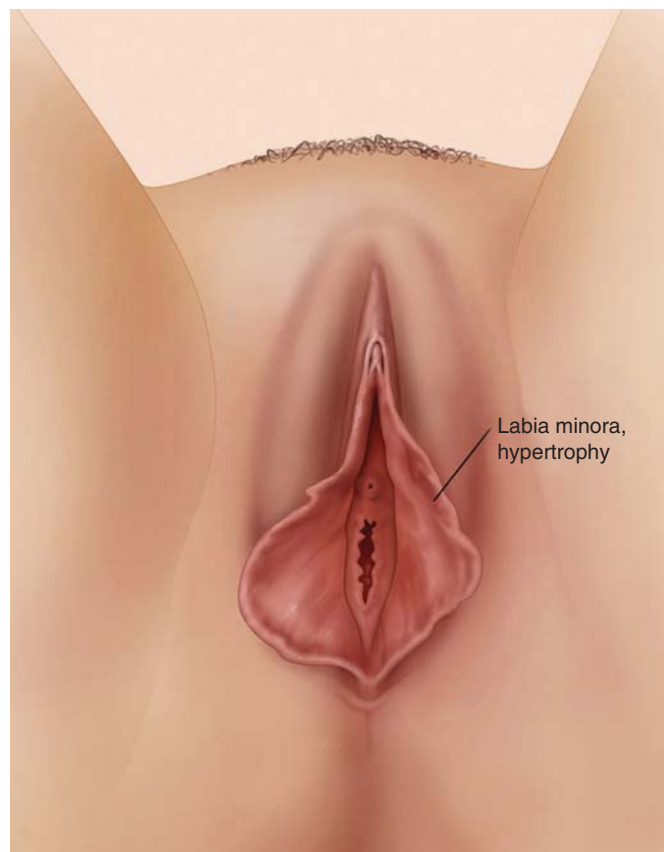

Figure 104.12 Bilateral labial hypertrophy. Source: Courtesy of Robert D Moore and John R Miklos.

One of the common mistakes of cosmetic vaginal surgeries is due to inferences and suggestions on the part of the surgeon. Some surgeons suggest that patients might benefit from a surgical procedure despite no complaints from the patient. The authors of this chapter highly discourage any suggestive surgical intervention and only pursue surgery at the patient's request. Still even when a patient has a complaint of a cosmetic vaginal problem, many surgeons do not listen to what the patient wants and instead assumes what the patient needs based on his/her limited surgical armamentarium. Cosmetic vaginal surgery does not always begin and end with labia minora reduction surgery, i.e., labiaplasty. There are many different techniques which can be applied to enhance of womans genital cosmetic image. To understand the techniques a basic understanding of the external genitalia is essential before applying surgical technique.

Anatomy

The vulva is made up of the external genitalia including the mons pubis, clitoris, prepuce or clitoral hood, labia minora, labia majora, urethral meatus, hymen, and vestibule (Fig. 104.11). The mons pubis is the adipose laden area that lies superior to the pubic symphysis. This area is naturally covered with pubic hair and is natural cushion during the impact of intercourse. The adipose area of the mons is contiguous with that of the hair bearing labia majora. The labia majora are found bilaterally and converge both anteriorly above the clitoral prepuce and posteriorly at the perineum. The prepuce is actually the clitoral hood and acts like a protective covering over the clitoral gland. Usually the very distal tip of the clitoris remains uncovered and exposed.

The labia minora are bilateral mucosal-cutaneous refolds located between the labia majora and vulvar vestibule. While there is a wide range of normal anatomic variants, in general, the labia minora are semicircular with a 3-cm-long base and a free edge extending from the clitoris to the posterior commissure. The medial mucosal surface is derived from the primitive urogenital sinus and is shiny and pink. The free edge and the lateral cutaneous surface are derived from the urethral folds and are more deeply pigmented (42). However, the deeper pigment tends to be a darker pink initially and then begins to darken with hormonal changes often but not always associated with pregnancy. Obviously just like any other part of the human body there are multiple normal variants of this anatomy. Just like a nose all the structures can be anatomically similar but cosmetically dissimilar. The most common of all described cosmetic vaginal surgery is labia minora reduction or labiaplasty (42–45).

Labia Minora Reduction (Labiaplasty)

Labia minora protruding past the distal edge of the labia majora can be of concern to women. As mentioned above this condition can constitute a functional or cosmetic problem. Such an enlargement can be bilateral or unilateral in nature (Figs. 104.12 and 104.13). Labia enlargement can be congenital as described by Caparo (46) and Radman (47) or can also be the result of androgenic hormones, manual

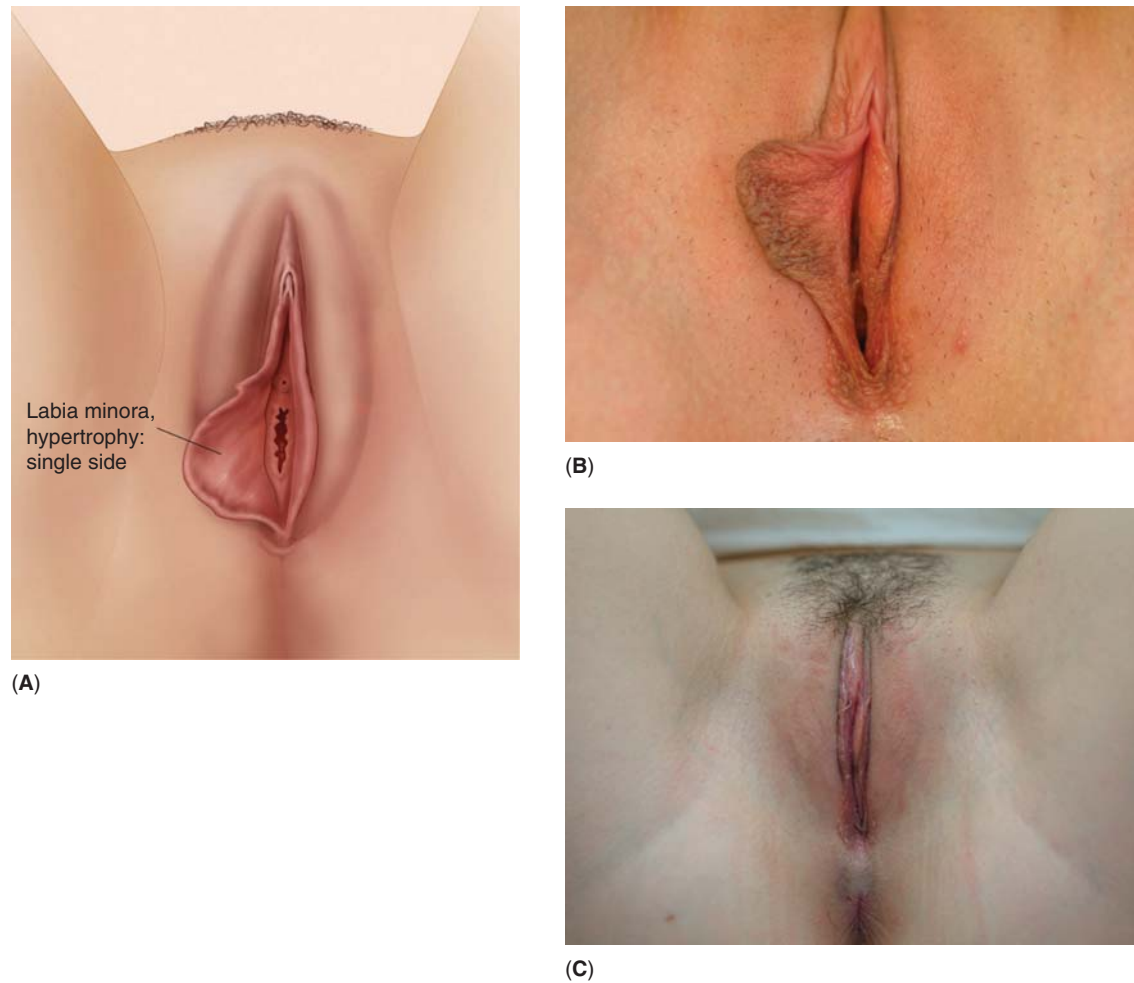


Figure 104.13 (A–B) Unilateral Labia Hypertrophy prior to repair; (C) after reduction labiaplasty. Source: Courtesy of Robert D Moore and John R Miklos.

stretching, and chronic irritation (46–49). Despite the cause, labia enlargement remains a problem for some women.

Rouzier et al. reported on 163 women who received labia reduction surgery. The primary reason for patients requesting labia reduction surgery was aesthetic dissatisfaction in 87% of cases, discomfort in clothing in 64%, discomfort when taking part in sports in 26%, and entry dyspareunia by invagination of the protuberant tissue in 43% (43). A recent study of 131 patients undergoing labia minora reduction surgery revealed the patients' indications for having the surgery: 37% strictly cosmetic reasons, 32% strictly for physical symptoms, and 31% a combination of cosmetic reasons and physical symptoms (41). Patients afflicted with these types of symptoms often seek a solution and currently the only solution remains surgical intervention.

Though there are few reports in the literature on labia reduction surgery, there are a number of different techniques described in the literature. The two most commonly utilized techniques are known as: excision or contouring technique and the wedge resection technique. We employ both techniques depending upon the patients' requests and desires. If the patients prefer to keep the darkened pigmented labial border we tend to utilize the wedge resection technique. However, it has been the authors' experience that most of their patients prefer to have a pinker or lighter look to the edges of their

labia. In this situation, in an attempt to fulfill the desires of the patient, we utilize the contouring technique (50).

The contouring or excisional technique is a more time consuming operation and directly excises the edge of the labia minora (Fig. 104.14A–D). Though all surgeries are surgeon dependent, this operation is less reproducible than the wedge technique because it requires more artistic aptitude. There are multiple skin folds that need to be excised, reduced, and brought together to achieve a natural anatomic appearance of the entire external vulvar region. The edges should be contoured or removed in an artistic fashion instead of the commonly described term amputation. The term amputation seems to insinuate the protruding labia should just be “cut off” in a straight vertical fashion, which does not result in aesthetically pleasing results and can cause pain and discomfort. The procedure should not be completed with this type of “amputation” technique. Time and care should be put into the incision and the excision of the protruding aspect of the labia. It should be removed in a curvilinear fashion at the level or below the level of the labia majora. The amount of tissue removed should be in direct correlation to the patient's desire. Aggressive excision can result in complete amputation resulting in an undesirable result (Fig. 104.15). Time, patience, and experience are essential in cosmetic vaginal surgery. The results of a contouring surgery should be aesthetically pleasing yet

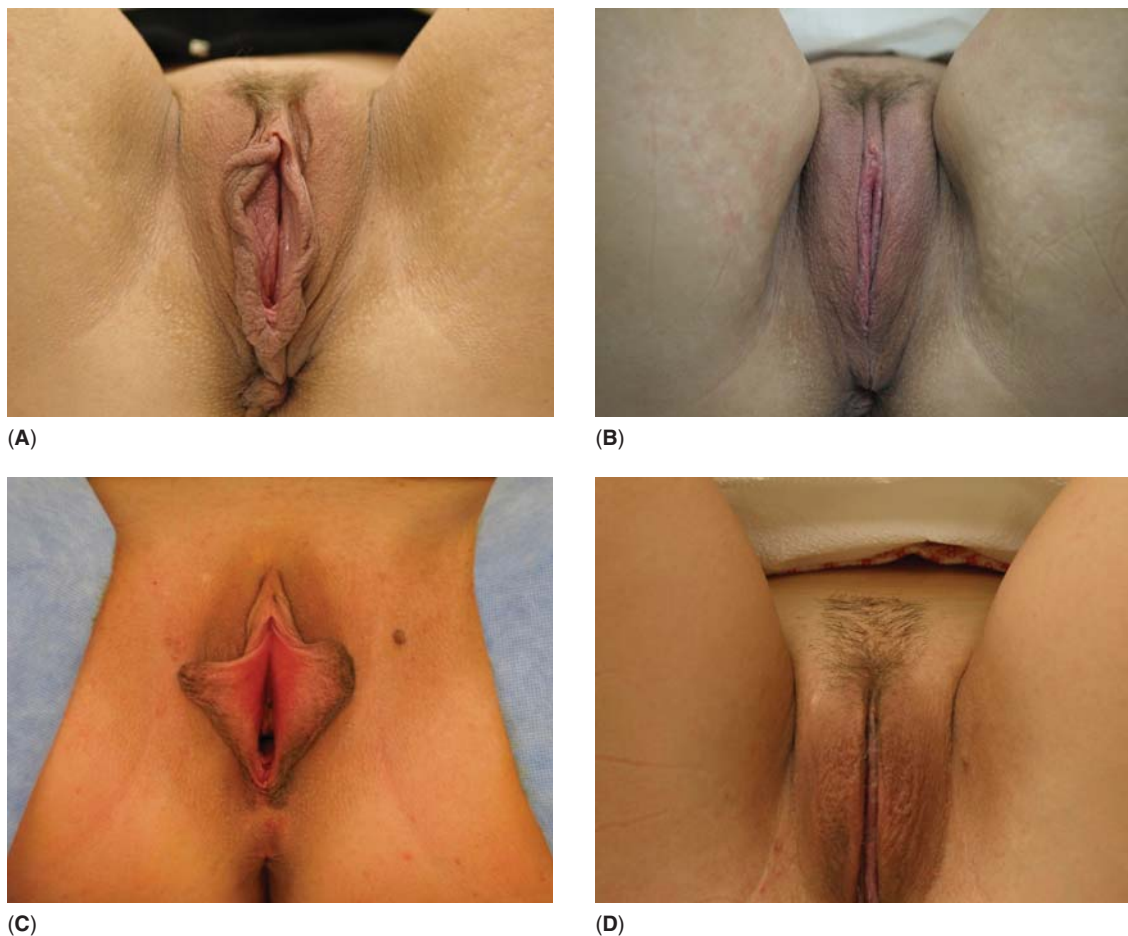


Figure 104.14 Before (A,C) and after (B,D) labial reduction utilizing contacting technique. Source: Courtesy of Robert D Moore and John R Miklos.

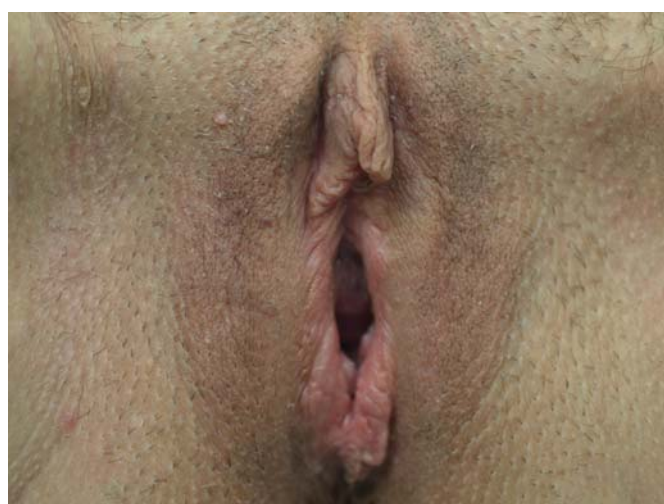

Figure 104.15 Aggressive surgery resulting in amputation. Source: Courtesy of Robert D Moore and John R Miklos.

addresses any associated physical dysfunction. Most women state that they do not want their labia minora to protrude beyond the majora and are interested in a smooth, sleek appearance of the external vulva. This was confirmed in a recent study of 238 women that presented for labial reduction surgery at our specialty center in Atlanta. Of the 238 women that were presenting for labial reduction, 98% of

them desired for their labia minora to be reduced to the level of or below the level of the labia majora (50).

The authors utilize the wedge resection technique in patients who desire to maintain the darkened skin edges of the labia. The technique was first described in the literature by Alters in 1998, where he utilized the technique on four patients (45). In this case series it is suggested that excision or contouring the protuberant edges removes the natural contour and color. Interestingly many patients do not feel that the darkened skin edges are a normal color but instead the result of aging and hormonal changes. No different than the skin discoloration that happens on hands or the areola of the breast. This was also confirmed in a recent study of 238 women presenting for labiaplasty at our center in Atlanta. Of the 238 women 72% of women felt their skin edges were dark or pigmented and 98% preferred that their skin edges be pink following the procedure (50). The authors feel the wedge technique is less time consuming and requires less artistic impression. However the authors recommend utilizing the technique which best meets the patient's desires. Remember, the labia minora reduction cannot address all the cosmetic issues of the vulva. In fact many of the patients will complain of redundant lateral prepuce at the time of consultation for the labia enlargement and the wedge resection technique does not address these extra skin folds, which when not reduced

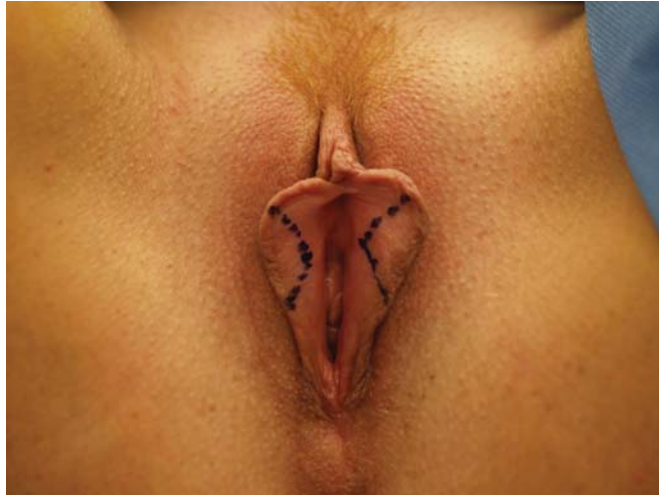


Figure 104.16 Wedge resection technique. Source: Courtesy of Robert D Moore and John R Miklos.

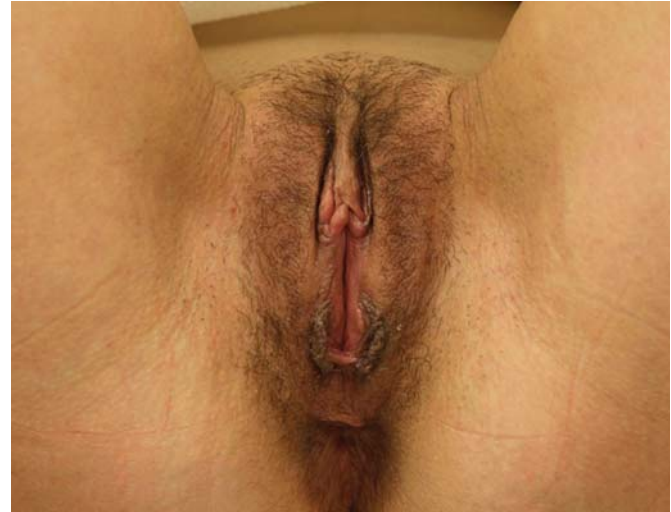

Figure 104.18 Labiaplasty with no reduction of prepuce. Source: Courtesy of Robert D Moore and John R Miklos.

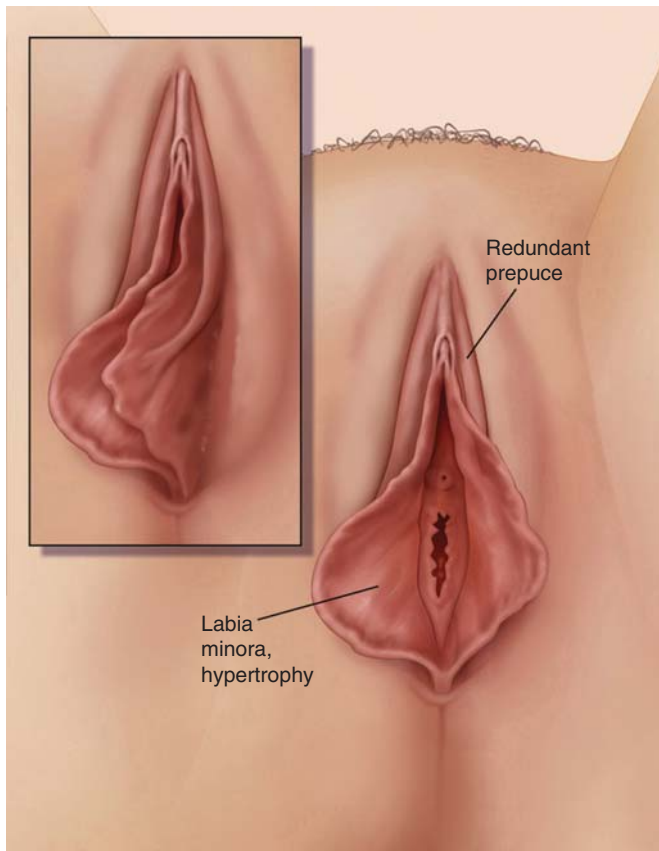


Figure 104.17 Redundant prepuce and lateral insertion. Source: Courtesy of Robert D Moore and John R Miklos.

at the time of labial surgery leaves a very unnatural appearance and can make the clitoral area actually appear larger (Fig. 104.16).

Redundant Lateral Prepuce

In our practice, approximately 40% of patients also complain of redundant prepuce when they consult for labia minora enlargement (Fig. 104.17A). This is strictly a cosmetic problem

and not a functional problem. We have not had patients complain of symptoms from redundant lateral prepuce. On examination patients will often point out the lateral excessive tissue which is adjacent to the clitoral hood bilaterally. If the patient wants to have her labia minora reduced via a contouring technique often the redundant prepuce will inhibit the surgeon from getting good cosmetic results unless the prepuce redundancy is reduced or removed. The reason why the redundant prepuce becomes an issue is because of its anatomic insertion. The origin of the prepuce starts laterally to the prepuce and then inserts usually at an acute angle into the lateral aspect of the labia minora (Fig. 104.17B). An excision of the labia minora without addressing the redundant prepuce can result in poor cosmesis (Fig. 104.18).

Excess Prepuce Reduction (Clitoral Unhooding)

As described above we have coined the term “redundant prepuce” in patients who have an extra layer of prepuce *lateral or adjacent* to the clitoral hood. Patients with excess prepuce have excessive prepuce at its normal anatomic position. In other words the prepuce is in the right spot but there is just an excessive amount of it or have an elongation of the clitoral hood itself (Fig. 104.19A and B). Patients who complain of excess prepuce usually complain of difficulty accessing the clitoris thus making clitoral orgasms difficult to achieve. This type of clitoral hood enlargement can be congenital, due to chronic irritation or persistent manual stretching. This is similar to the concept that labia minora enlargement can be because of weight attachment of the labia as in the Hottentot tribe (46). Surgical resection, if done correctly, can bring favorable results for patients with excess prepuce. Performed incorrectly it can result in hypersensitivity and chronic pain or even severe scar limiting any access to the clitoris.

Labia Majora Reduction

Patients also often consult for enlarged labia majora. The patients complain of “drooping,” “sagging,” or “hanging” majora or the majora is just too large and protruding in appearance. Many women state that this skin is very loose and

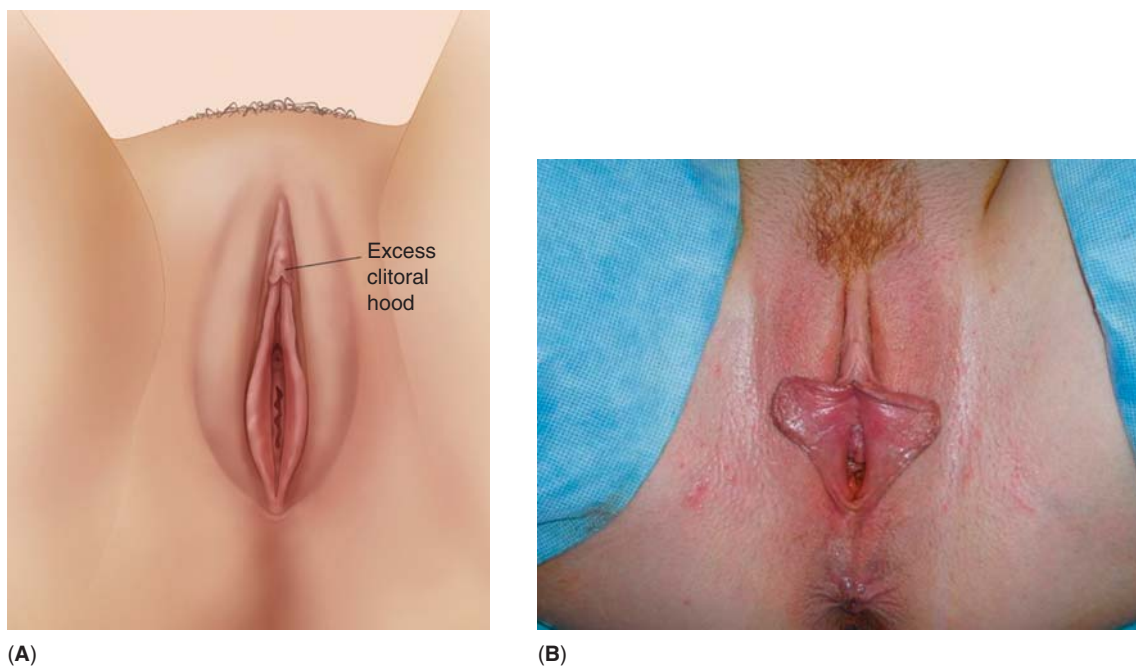


Figure 104.19 (A, B) Excess prepuce (elongated clitoral hood). Source: Courtesy of Robert D Moore and John R Miklos.

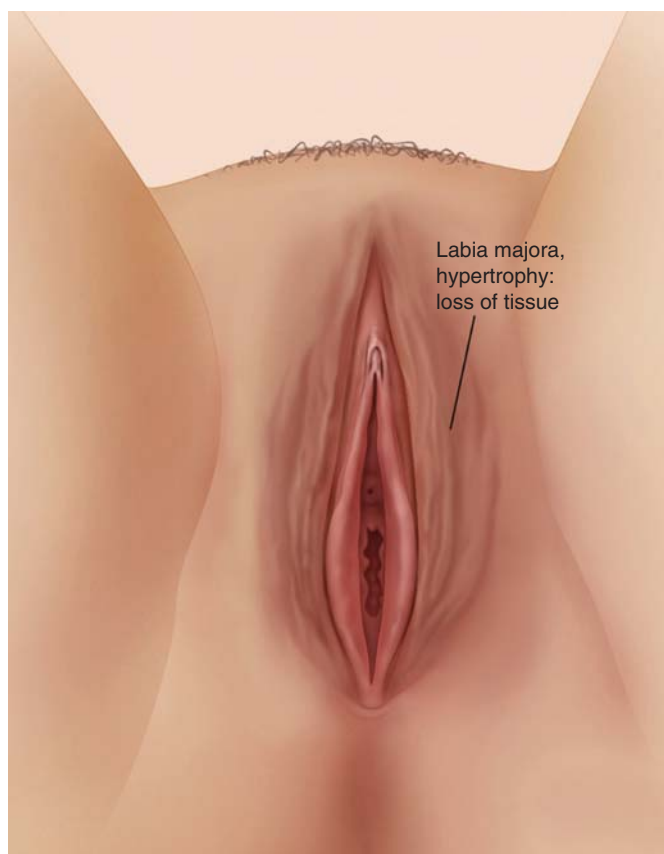

Figure 104.20 Sagging labia majora. Source: Courtesy of Robert D Moore and John R Miklos.

makes the appearance of the external vaginal area appear “old.” They are looking for a youthful “plumpness” of the labia majora, without much laxity or wrinkling. The sagging labia majora is often the result of weight gain and weight losses

which seem to be often associated with pregnancy or in patients who have had bariatric surgery. The saggy skin of the labia majora is the result of stretching during the weight gain now with sudden weight loss the skin hangs because it has lost some of its elastisty. It can also occur due to aging and/or childbearing. Analogous situation occurs to the abdominal and buttocks skin after bariatric surgery. Often patients need to have skin reduction surgery of the abdomen and buttocks after dramatic weight loss (Fig. 104.20).

Still others complain of enlarged labia majora and on examination do not have sagging skin. These patients tend to have taut skin because it is filled with excessive adipose deposits. This in essence results in lipodystrophy of the labia majora and labia majora hypertrophy. In many cases, women that have had abdominoplasties and/or liposuction of the abdominal region, end up with an asymmetrically enlarged mons pubis. This area also in many cases has excess deposits of fatty tissue and if not reduced at time of abdominoplasty, ends up protruding out, or hanging down. These patients often complain they cannot wear tight wearing clothing or they are embarrassed in a swimming garment because they feel as if their vulva and/or mons is protruding. These patients can benefit from liposuction of the mons pubis and labia majora areas (Fig. 104.21A and B).

Labia Majora Convergence

Cosmetic surgical patients are very consumer savvy and often are quite specific about their cosmetic desires. Many of our patients will have pictures and or medical illustrations, which represent their desired cosmetic results. Another common request we have coined “labia majora convergence” surgery. Patients can have labia majora divergence both anteriorly at the mons pubis or directly anterior to the clitoral hood and posteriorly at the perineum (Fig. 104.22A and B). Surgical correction

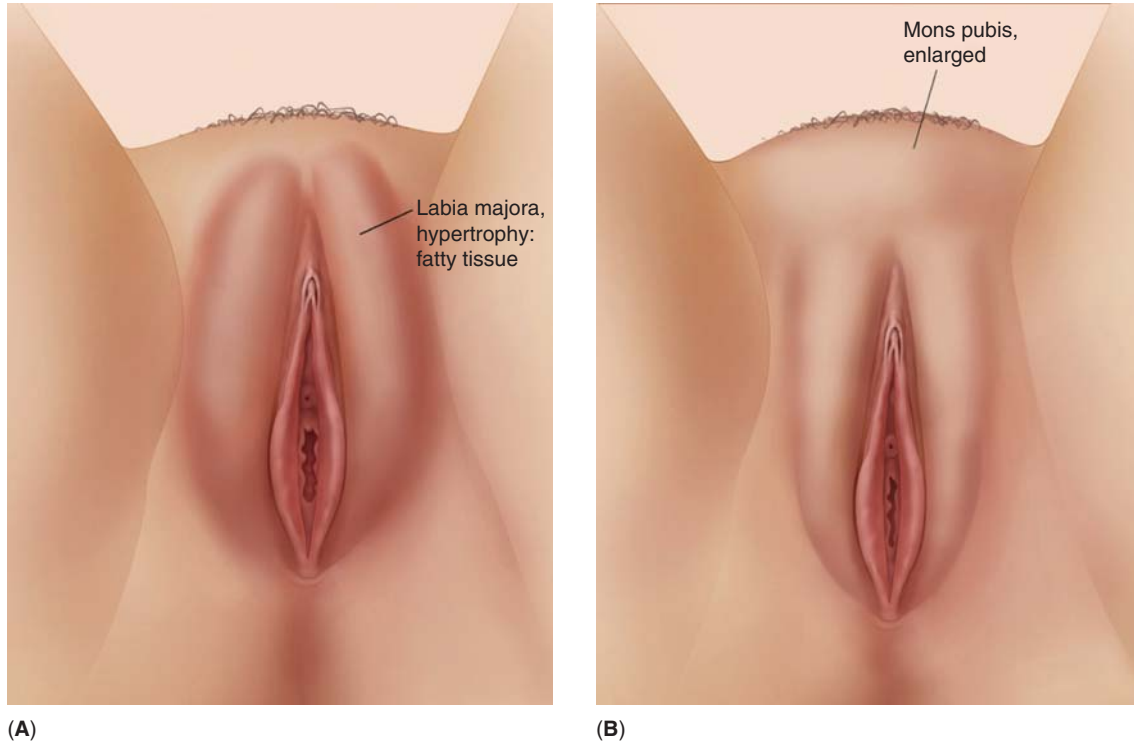


Figure 104.21 (A) Enlarged or hypertrophied labia majora; (B) lipodystrophy of mons pubis. Source: Courtesy of Robert D Moore and John R Miklos.

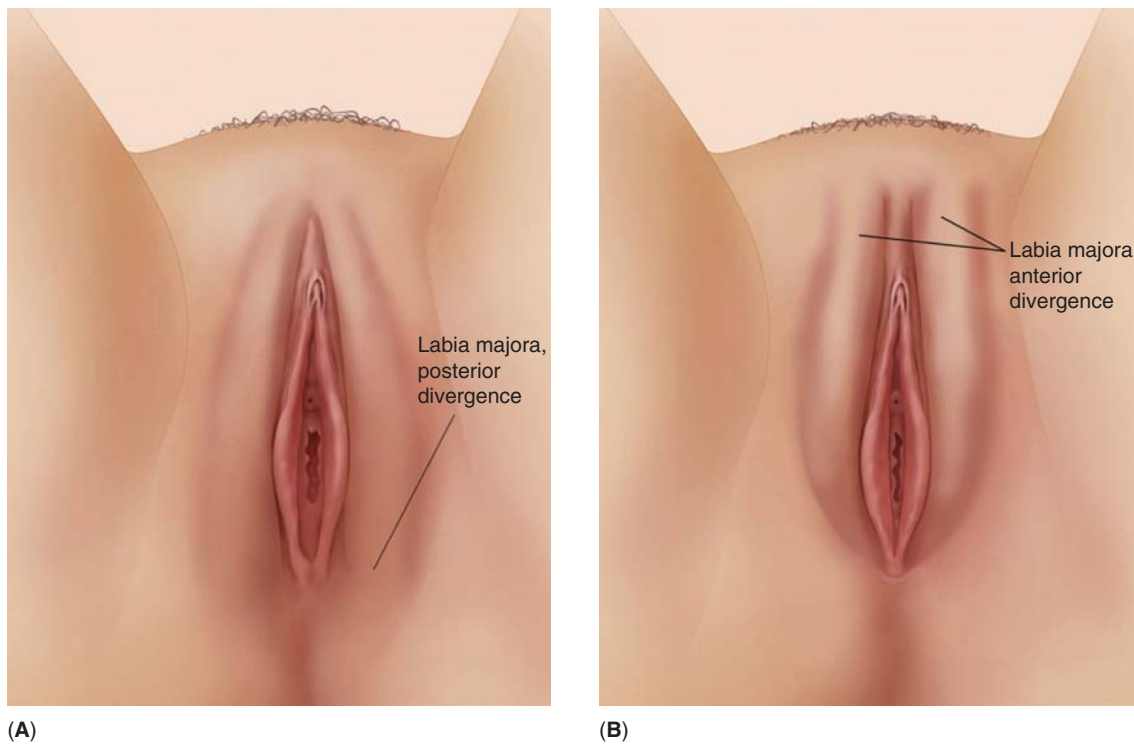


Figure 104.22 (A) Posterior divergence of labia majora; (B) superior or anterior divergence of labia majora. Source: Courtesy of Robert D Moore and John R Miklos.

of the divergence results in convergence of both or either the anterior division of posterior aspect of the labia majora.

CONCLUSION

Cosmetic vaginal surgery is a newly emerging frontier in our dynamic and body image conscious society. Still in its infancy this discipline will continue to mature and take on a

life of its own. Partially spurred by our ever pervasive process of globalization, the internet, the desire to “anti-age” and remain youthful in appearance and function, cosmetic vaginal surgery is here to stay. A woman’s desire to enjoy life to its fullest does require a good body image and *sometimes* a little surgical help might be necessary to help maintain that body image.

REFERENCES

- Delancey JOL, Kearney R, Chou Q, Speights S, Binno S. The appearance of levator ani muscle abnormalities in magnetic resonance images after vaginal delivery. *Obstet Gynecol* 2003; 101: 46–53.
- Allen RE, Hosker GL, Smith ARB, Warrel DW. Pelvic floor damage and childbirth: a neurophysiological study. *Br J Obstet Gynaecol* 1990; 97: 770–9.
- Hendrix SL, Clark AM, Nygaard I, et al. Pelvic organ prolapse in the Women's Health Initiative: gravity and gravidity. *Am J Obstet Gynecol* 2002; 186: 1160–6.
- Signorello LB, Harlow, Chekos AK, Repke JT. Postpartum sexual functioning and its relationship with perineal trauma: a retrospective cohort study of primiparous women. *Am J Obstet Gynecol* 2001; 184: 881–8.
- Wu JM, Hundley AF, Visco AG. Elective primary caesarean delivery: attitudes of urogynecology and maternal fetal medicine specialists. *Obstet Gynecol* 2005; 105: 301–6.
- Brubaker LT, Saclarides TJ, eds. *The Female Pelvic Floor: Disorders of Function and Support*. Philadelphia PA: FA Davis Company, 1996.
- Karram MM, Walters MD, eds. *Urogynecology and Reconstructive Surgery*, 3rd edn. Philadelphia: Elsevier Mosby, 2006.
- Nichols DH, Randall CL. *Vaginal Surgery*, 3rd edn. Baltimore, MD: Williams and Wilkins, 1989.
- Lowenstein L, Pierce K, Pauls R. Urogynecology and sexual function research. How are we doing? *J Sex Med* 2009; 6: 199–204.
- Novi JM, Jeronis S, Morgan MA, Arya LA. Sexual function in women with pelvic organ prolapse compared to women without prolapse. *J Urol* 2006; 173: 1669–72.
- Botros SM, Sand P, Goldberg RP, et al. Effect of parity on sexual function: an identical twin study. *Obstet Gynecol* 2006; 107: 765–70.
- Barber MD, Visco AG, Bump RC, et al. Sexual function in women with urinary incontinence and pelvic organ prolapse. *Obstet Gynecol* 2002; 99: 281–9.
- Rogers GR, Villareral A, Kammerer-Doak D, et al. Sexual function in women with and without urinary incontinence and/or pelvic organ prolapse. *Int Urogynecol J Pelvic Floor Dysfunct* 2001; 12: 361–5.
- Nguyen JN, Burchette RJ. Outcome after anterior vaginal wall prolapse repair: a randomized controlled trial. *Obstet Gynecol* 2008; 111: 891–8.
- Nieminem K, Hiltunen R, Heiskanen E, et al. Symptom resolution and sexual function after anterior vaginal wall repair with and without polypropylene mesh. *Int Urogynecol J* 2008; 19: 1611–16.
- Gauruder-Burmester A, Koutouzidou P, Tunn R. Effect of vaginal polypropylene mesh implants on sexual function. *Eur J Obstet Gynecol* 2008. DOI:10.1016/j.ejogrb.2008.09.010.
- Srikrishna S, Robinson D, Cardozo L, Cartwright R. Experiences and expectations of women with urogenital prolapse: a quantitative and qualitative exploration. *BJOG* 2008; 115: 1362–8.
- Azar M, Noohi S, Radfar S, et al. Sexual function in women after surgery for pelvic organ prolapse. *Int Urogynecol J Pelvic Floor Dysfunct* 2007. [Epub ahead of print].
- Rogers RD, Kammerer-Doak D, Barber M, et al. Does sexual function change after surgery for stress urinary incontinence and/or pelvic organ prolapse? A multicenter prospective study. *Am J Obstet Gynecol* 2006; 195: e1–4.
- Thakar R, Chawla S, Scheer I, Barrett G, Sultan AH. Sexual function following pelvic floor surgery. *Int J Gynaecol Obstet* 2008; 102: 110–14.
- Stoutjesdijk JA, Vierhout ME, Spruijt JW. Does vaginal reconstructive surgery with or without vaginal hysterectomy or trachelectomy improve sexual well-being? A prospective follow-up study. *Int Urogynecol J Pelvic Floor Dysfunct* 2006; 17: 131–5.
- Tunuguntia HS, Gousse AE. Female sexual dysfunction following vaginal surgery: a review. *J Urol* 2006; 175: 439–46.
- Komesu YM, Rogers RG, Kammerer-Doak DN, et al. Posterior repair and sexual function. *Am J Obstet Gynecol* 2007; 197: 011.e1–6.
- Paraiso MF, Barber MD, Muir TW. Rectocele repair: a randomized trial of three surgical techniques including graft augmentation. *Am J Obstet Gynecol* 2006; 195: 1762–71.
- Ozel B, White T, Urwitz-Lane R. The impact of pelvic organ prolapse on sexual function in women with urinary incontinence. *Int Urogynecol J Pelvic Floor Dysfunct* 2006; 17: 14–17.
- Baytur YB, Deveci A, Uyar Y, Ozcakir HT, Caglar H. Mode of delivery and pelvic floor muscle strength and sexual function after childbirth. *Int J Gynaecol Obstet* 2005; 88: 276–80.
- Kline G. Case studies of perineometer resistive exercises of orgasmic dysfunction. In: Graber B, ed. *Circumvaginal Musculature and Sexual Function*. Basel Switzerland: Karger, 1982: 25–42.
- Grafenberg E. The role of the urethra in female orgasm. *Int J Sex* 1950; 3: 145–8.
- Gravina GL, Brandetti F, Martini P, et al. Measurement of the thickness of the urethrovaginal space in women with or without vaginal orgasm. *J Sex Med* 2008; 5: 610–18.
- Perry JD, Whipple B. Multiple components of the female orgasm. In: Graber B, ed. *Circumvaginal Musculature and Sexual Function*. Basel, Switzerland: Karger, 1982; 101–14.
- Sevely JL, Bennett JW. Concerning female ejaculation and the female prostate. *J Sex Res* 1978; 14: 1–20.
- Mould D. Women's orgasm and the muscle spindle. In: Graber B, ed. *Circumvaginal Musculature and Sexual Function*. 1982: 93–100.
- Perry JD, Whipple B. Vaginal myography. In: Graber B, ed. *Circumvaginal Musculature and Sexual Function*. Basel, Switzerland: Karger, 1982: 61–73.
- Pardo JS, Sola VD, Ricci PA, et al. Colpoperineoplasty in women with a sensation of a wide vagina. *Acta Obstetrica et Gynecologica* 2006; 85: 1125–7.
- Pardo JS, Sola VD, Ricci PA, et al. Colpoperineoplasty for vaginal relaxation: a follow-up study. *Int Urogynecol J* 2007; 18(Suppl1): S147.
- Goodman M, Miklos JR, Moore RD, et al. A large multicenter outcome study of female genital plastic surgery. *J Sexual Med* 2009 Nov 12. Epub ahead of print. DOI # 10.1111/j.1743-6109.2009.01573.x.
- Ackard DM, Kearney-Cooke A, Peterson CB. Effect of body image and self-image on women's sexual behaviors. *Int J Eat Disord* 2000; 28: 422–9.
- Liao LM, Creighton SM. Requests for cosmetic genitoplasty: how should healthcare providers respond? *Br Med J* 2007; 334: 1090–2.
- Tracy E. Elective vulvoplasty: a bandage that might hurt. *Obstet Gynecol* 2007; 109: 1179–80.
- Pauls RN. Nip, tuck and rejuvenate; the latest frontier for the gynecologic surgeon. *Int Urogynecol J Pelvic Floor Dysfunct* 2007; 18: 841–2.
- Miklos JR, Moore, RD. Labiaplasty of the labia minora: patients' indications for pursuing surgery. *J Sex Med* 2008; 5: 1492–5.
- Goldstein AT, Romanzi LJ. Z-plasty reduction labiaplasty. *J Sex Med* 2007; 4: 550–3.
- Rouzier R, Louis-Sylvestre C, Paniel BJ, Haddad B. Hypertrophy of labia minora: experience with 163 reductions. *Am J Obstet Gynecol* 2000; 182: 35–40.
- Choi HY, Kim KT. A new method for aesthetic reduction of labia minora (the deepithelialized reduction labiaplasty). *Plast Reconstr Surg* 2000; 105: 419–22.
- Alter GJ. A new technique for aesthetic labia minora reduction. *Ann Plast Surg* 1998; 40: 287–90.
- Caparo VJ. Congenital anomalies. *Clin Obstet Gynecol* 1971; 14: 988.
- Radman HM. Hypertrophy of the labia minora. *Obstet Gynecol* 1978; 48(Suppl): 78S.
- Chavis WM, LaFerla JJ, Niccolini R. Plastic repair of elongated, hypertrophic labia minora. A case report. *J Reprod Med* 1989; 34: 373.
- Kato K, Kondo A, Gotoh M. Hypertrophy of labia minora in myelodysplastic omen. Labiaplasty to ease clean intermittent catheterization. *Urology* 1988; 31: 294.
- Miklos JR, Moore RD. Labia minora physical characteristics: preoperative perception and postoperative expectations. *J Sex Med* 2009; in press.