

Effectiveness of Treatment of Calcific Tendinitis of the Shoulder by Disodium EDTA

ANGELO CACCHIO,¹ ELISABETTA DE BLASIS,² PIERGIORGIO DESIATI,¹ GIORGIO SPACCA,¹
VALTER SANTILLI,³ AND FOSCO DE PAULIS⁴

Objective. To evaluate the effectiveness of disodium EDTA administration in the treatment of calcific tendinitis of the shoulder.

Methods. Eighty patients with radiographically verified calcific tendinitis of the shoulder were enrolled between September 2001 and October 2003. Patients were randomly assigned to either a study group (n = 40) or a control group (n = 40). Pain and functional level were evaluated before and after treatment and at 1-year followup. Radiographic modifications in calcifications were evaluated before and after treatment. Disodium EDTA was administered through single needle mesotherapy and 15 minutes of pulsed-mode 1 MHz-ultrasound.

Results. The study group displayed improvement in all of the parameters analyzed after treatment and at the 1-year followup. Calcifications disappeared completely in 62.5% of the patients in the study group and partially in 22.5%; calcifications partially disappeared in only 15% of the patients in the control group, and none displayed a complete disappearance.

Conclusion. Our results suggest that the use of disodium EDTA for the management of calcific tendinitis of the shoulder is safe and effective, leading to a significant reduction in pain, improvement in shoulder function, and disappearance of calcifications after 4 weeks, without adverse effects.

INTRODUCTION

Calcific tendinitis of the shoulder is characterized by calcium phosphate crystal deposition in the rotator cuff tendons (1,2). The incidence of calcific tendinitis varies, depending on different reports, from 2.7% to 63% (2,3). Despite many investigations, the etiology and pathogenesis of shoulder calcific tendinitis remain unclear (4–7). Hypovascularization and local degenerative and proliferative changes in tendinous tissue of the rotator cuff have been suggested as possible causes (4,6,7). The disorder leads to pain, particularly nocturnal discomfort, in ~50% of patients (2,8) and frequently leads to a considerable restriction of range of motion. The clinical presentation

varies considerably, and symptoms may last for several days and then either disappear or become chronic (2,7). The natural history and incidence of spontaneous resorption of the calcific deposit is variable. For example, Bosworth (2) described the disappearance of calcifications in 9.3% of patients within 3 years of the initial diagnosis. According to Wagenhauser (9), calcifications disappeared in 27.1% of patients after 10 years, and Gartner (10) reported that calcifications with sharp margins and a homogeneous or heterogeneous structure disappeared spontaneously in 33% of patients over a period of 3 years. The time required for a spontaneous disappearance of the calcifications, however, is often too long and unacceptable for the patient's quality of life.

Treatment of patients with calcific tendinitis is typically conservative and includes the use of nonsteroidal antiinflammatory drugs and analgesics, acetic acid iontophoresis (11,12), therapeutic exercise (13), and therapeutic ultrasound (14,15), all of which have a limited effect (16).

When typically conservative therapy has not been effective in relieving pain and other symptoms, percutaneous needle aspiration (17), shock wave therapy (18–22), and rarely surgical intervention (23,24) are used. Heavy metal and mineral chelator disodium EDTA is an amino acid that was first synthesized and patented in 1938 and refers to the chelating agent. This amino acid is widely used to sequester divalent and trivalent metal and mineral ions

¹Angelo Cacchio, MD, Piergiorgio Desiati, MChSc, Giorgio Spacca, MD: San Salvatore Hospital of L'Aquila, Via L. Natali 1, 67100 L'Aquila, Italy; ²Elisabetta De Blasis, MD: SS. Filippo e Nicola Hospital of Avezzano, Località Tre Conche, Avezzano, L'Aquila, Italy; ³Valter Santilli, MD: La Sapienza University of Roma, Piazzale A. Moro 5, 00185 Rome, Italy; ⁴Fosco De Paulis, MD: Valle Giulia Clinic, Via G. De Notaris 2, 00197 Rome, Italy.

Address correspondence to Angelo Cacchio, MD, Dipartimento di Medicina Fisica e Riabilitazione, Ospedale San Salvatore di L'Aquila, 67100 L'Aquila, Italy. E-mail: angelo.cacchio@tin.it.

Submitted for publication June 16, 2008; accepted in revised form August 15, 2008.

(e.g., lead, mercury, arsenic, aluminum, cobalt, calcium, etc.). Currently, disodium EDTA is used in chelation therapy, a treatment that involves intravenous administration for lead and heavy metal poisoning. EDTA binds to metals via 4 carboxylate and 2 amine groups. The rationale of its clinical use in calcific tendinitis of the shoulder is based on the fact that disodium EDTA could bind and remove the calcium deposits (25,26).

When ultrasound is used to drive molecules of a topically applied medication, it is called phonophoresis. Although the exact mechanism is not known, drug absorption may involve a disruption of the stratum corneum lipids allowing the drug to pass through the skin. Phonophoresis has been used to administer various drugs, including local anesthetics and antibiotics (27). This technique also has been used successfully to deliver antiinflammatory medication to inflamed subcutaneous tissues and to accelerate functional recovery by decreasing pain and promoting healing (27–30).

Mesotherapy is a method of treatment in which subcutaneous injections containing mixtures of compounds are given at the site of the pain at short intervals (31). In this way, a mixture of readily available drugs is administered to treat local medical conditions. There are many indications for mesotherapy (32–34), although most applications are found in the osteoarticular field (35–37).

In previous studies, disodium EDTA has been used for the treatment of the calcific tendinitis of the shoulder administered by ionophoresis (38,39) or mesotherapy (40), bringing good results. To our knowledge, there have been no previous randomized placebo-controlled trials published that assessed the safety and clinical effectiveness of disodium EDTA administered by phonophoresis and mesotherapy in the treatment of calcific tendinitis of the shoulder. The purpose of the present study was to evaluate the effectiveness of disodium EDTA administered by phonophoresis and mesotherapy on pain relief, restoration of shoulder function, and resolution of calcific tendinitis of the shoulder.

PATIENTS AND METHODS

Patients. Between September 2001 and October 2003, patients with radiographically verified calcific tendinitis of the shoulders were treated at a single center. This double-blind, randomized, placebo-controlled study was approved by our local ethics committee, and written informed consent was obtained from all patients before participation in the study. Inclusion criteria were as follows: calcific tendinitis of the shoulder, detected on standardized radiographs, with type I (homogenous and with well-defined borders) or type II (heterogeneous in structure with sharp outline or homogenous in structure with no defined border) calcifications according to the Gartner and Simons radiographic classification (4); visual analog scale (VAS) score ≥ 4 cm at the moment of the evaluation; presence of symptoms for at least 6 months; and failure of previous conservative treatments (antiinflammatory drugs, ultrasound and exercises, laser therapy and exercises, electrical stimulation and exercises, acupuncture, and ste-

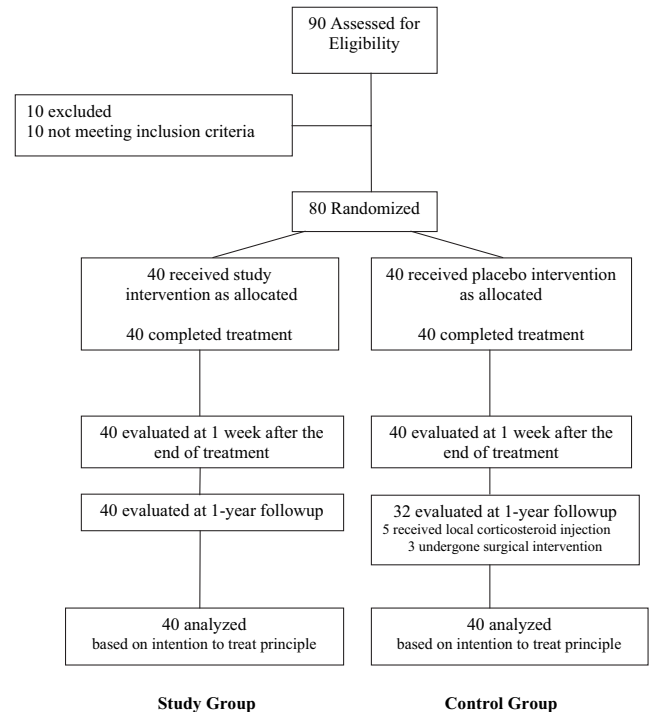


Figure 1. Flow diagram of the study.

roid injection). Exclusion criteria were as follows: rotator cuff tear, glenohumeral or acromioclavicular arthritis, or acromioclavicular spur to rule out alternative explanations for the pain; pregnancy; implanted pacemaker; blood coagulation disorders or use of anticoagulant drugs; age <18 years; inflammatory or neoplastic disorders; presence of type III (cloudy and transparent) calcifications according to the Gartner and Simons radiographic classification (4); and conservative treatments administered in the last 4 weeks.

Presence of other shoulder pathologies (e.g., rotator cuff tear, bursitis, etc.) was clinically evaluated by an expert physiatrist, and, when suspected on the basis of the clinical findings, ultrasound and magnetic resonance imaging examinations were performed before the randomization.

Patients who met the eligibility criteria were randomly assigned, using a computer-based 1:1 randomization scheme and sealed envelopes, to either a study group or a control group (Figure 1), so that each patient had an equal probability of being assigned to either group. The first patient was randomized in September 2001, and the last patient was randomized in October 2003.

Outcome measures. The primary end points were an increase of 30 points in the mean Constant and Murley Score (CMS) (41) and a decrease of 3 points in the mean VAS score, from before treatment to after treatment and to the 1-year followup period. The CMS is a standardized tool for evaluating shoulder pain and function. The maximum score (100 points) corresponds to the sum of 2 components, one subjective (35 points) and the other objective (65 points, including 25 points for shoulder muscle strength, which we assessed with an electronic dynamometer). A score of 100 represents an asymptomatic patient.

The CMS has been validated and shows good intra- and interobserver reproducibility.

Self-rated pain intensity at the moment of the evaluation was measured on a 10-cm horizontal VAS, with 0 cm labeled as “no pain” and 10 cm labeled as “worst pain I have ever had.” Patients were asked to answer the following question: “Referring to the worst pain you have experienced in your life, what is the relative level of your shoulder pain?” We chose this question after verifying that no patient in our series had a medical history of excruciating pain conditions.

The secondary end point was the radiographic disappearance of calcifications at the end of treatment. Success was defined as complete disappearance of calcifications. An anteroposterior radiograph of the shoulder obtained in 45 degrees of external rotation and 45 degrees of internal rotation was obtained for each patient under standardized conditions in terms of distance from radiographic film and exposure setting (42) in order to evaluate the presence, type, and size of calcifications, as well as their location within a specific tendon. Type of calcification was evaluated according to the Gartner and Simons classification (4). A caliper that evaluated calcification length (in millimeters) was used for size measurement. The radiographic assessments were obtained before treatment; posttreatment assessment was performed 1 week after the end of treatment so that the disappearance of the calcification could be correlated with the therapy performed.

Primary outcome measurements were performed by 2 experienced physicians. The secondary outcome measurements were assessed by an experienced radiologist. The patients, the outcome assessors, and the radiologist were all blinded to the treatment performed.

Tolerability of disodium EDTA. To evaluate the tolerability of the disodium EDTA during the course of treatment, patients underwent a complete laboratory examination, including hematology, blood chemistry, and urinalysis. Patients also underwent a clinical examination to record vital signs, and were asked to record all the adverse effects they observed.

Treatment. Each patient of the study group received 1) 1 administration per week, for 3 weeks, of single-needle mesotherapy with 1 ml of disodium EDTA, 1 ml of 1% procaine, and 3 ml of injectable water, and 2) 15 minutes of pulsed-mode ultrasound (frequency 1 MHz, power 2.5 watts/cm², pulse mode 1:4; Sonoplus 407, Enraf Nonius, The Netherlands), administered using a 15% solution of disodium EDTA gel (mixture of disodium EDTA and aquasonic gel), 5 times per week for 3 weeks.

The control group received the identical treatment procedure; however, the ultrasonic generator was not turned on, and the disodium EDTA was not present in the mixture for mesotherapy and in the aquasonic gel for ultrasounds.

Statistical analysis. The calculation of the number of patients was based on the primary outcomes. For the CMS at the end of treatment, it was assumed that the patients in the study group would have a mean of 80 points, and the

patients in the control group, a mean of 50 points, with a common SD of 30 points. For the VAS at the end of treatment, it was assumed that the patients in the study group would have a mean of 2 points, and the patients in the control group, a mean of 5 points, with a common SD of 3 points. On this basis, and assuming a level of significance of 5% and a power of 95%, the number of patients necessary was calculated to be 32 per group. A dropout of 15% was expected. Statistical analyses were performed using SAS software, version 8.2 (SAS Institute, Cary, NC). All analyses of the primary and secondary outcomes were performed according to the intent-to-treat principle. The intent-to-treat analysis was carried out according to a worst-case scenario analysis: patients who did not complete the treatment or had not undergone the posttreatment or final followup assessments were assigned a poor outcome, corresponding to the final average change recorded in the per-protocol completer population in the control group (43).

A 2-sample unpaired *t*-test was applied to compare the differences of the baseline data. A two-way analysis of variance (ANOVA) with group (study versus control) as the between-patient factor and time as the within-patient factor was used to assess the presence of significant differences between the study and control groups and within each group before and after treatment and at the 1-year followup. A Tukey post hoc comparison was used to determine significant differences between mean values when a significant main effect and interaction were found. Two-sample paired and unpaired *t*-tests were applied to compare the differences in average size of calcium deposits on radiographic examination before and after treatment and between the study and control groups, respectively. Two-sample paired *t*-tests were applied to compare the differences in mean values of clinical and laboratory examinations before and after treatment. For all analyses, 2-sided *P* values less than or equal to 0.05 were considered significant. A 95% confidence interval was also calculated.

RESULTS

Of 90 patients eligible for the study, 10 did not meet the inclusion criteria (Figure 1). The remaining 80 patients (44 men and 36 women, mean \pm SD age 46.20 \pm 2.05 years, range 40–52 years) with radiographically verified calcific tendinitis of the shoulder (mean \pm SD duration of symptoms 12 \pm 4.54 months, range 6–22 months) were randomly assigned to either the study group or the control group. No bilateral calcifications were encountered. The baseline characteristics, which did not display any statistically significant differences between groups, are shown in Table 1.

All 80 patients were reexamined 1 week after the treatment period. At the 1-year followup, all 40 patients in the study group were reappraised, and 8 patients (20%) in the control group were excluded, 5 because they had received corticosteroid injection therapy and 3 because they had undergone a surgical intervention between the end of treatment and followup. Nevertheless, based on the intent-to-treat principle (43), the data for these 8 patients were included in the data analysis.

Table 3. Mean size of calcifications, in millimeters, before and after treatment at radiographic examination*

	Study group (n = 40)	Control group (n = 40)	Δ between groups (95% CI)	P
BT	18.5 \pm 1.57	17.85 \pm 1.19	-0.65 (-1.38, 0.08)	0.08
AT	3.16 \pm 3.28	16.92 \pm 4.03	13.76 (11.81, 15.70)	< 0.01
Δ AT vs. BT (95% CI)	-15.34 (-16.68, -13.99)	-0.93 (-1.41, -2.24)		
P	< 0.01	0.16		

* Values are the mean \pm SD unless otherwise indicated; 95% CI = 95% confidence interval; BT = before treatment; AT = after treatment; Δ = mean difference.

as type I according to the Gartner and Simons classification (4). All 9 calcifications that partially disappeared were classified as type II, whereas all 6 unmodified calcifications were classified as type I. In the control group, no complete disappearance of calcifications was observed. Partial disappearance of calcifications was seen in 6 patients (15%), and unmodified calcifications were seen in 34 patients (85%). All 6 partially disappeared calcifications were type II, whereas of the remaining 34 unmodified calcifications, 6 were type I and 28 were type II according to the Gartner and Simons classification (4).

Tolerability of disodium EDTA. No side effects were recorded during the study. The results of clinical and laboratory examinations revealed no signs of systemic toxicity due to EDTA administration (Table 4).

DISCUSSION

The aim of this study was to evaluate the response to disodium EDTA administered through phonophoresis and mesotherapy in patients affected by calcific tendinitis of the shoulder. Although the disodium EDTA mechanism of action in calcific tendinitis of the shoulder is not fully understood, some authors (31–33) have used EDTA in the treatment of this condition with good results. It has been postulated that the action of disodium EDTA is due to its chelation capacity. Disodium EDTA has a lesser affinity for sodium than for calcium, thus disodium EDTA will ex-

change its sodium ions for a calcium ion (25,26). Disodium EDTA metal complexes are excreted by the kidney, with a biologic half-life of 20–60 minutes (44). However, no randomized clinical trial has yet been conducted to assess its safety and effectiveness in the management of calcific tendinitis of the shoulder. Thus, to our knowledge, this is the first double-blind, randomized, placebo-controlled study that has been conducted to investigate the effects of disodium EDTA on the treatment of calcific tendinitis of the shoulder.

Physiotherapy is widely recommended as the primary treatment for calcific tendinitis of the shoulder, although the physiotherapeutic treatment of choice is unclear. Peron and Malouin (11) did not report good results with the use of a 5% acetic acid solution via iontophoresis, followed by 5 minutes of continuous ultrasounds at 0.8 watts/cm², in the treatment of calcifying tendinitis of the shoulder. These negative results could be due to the low intensity (0.8 watts/cm²) and the brief time of administration (5 minutes) of the ultrasound. The rationale for the use of acetic acid is to obtain a solubilization of hydroxyapatite crystals, the main components of calcifications, by decreasing the pH. On the contrary, the action of EDTA is direct, due to its chelation capacity. Ebenbichler and colleagues (15) investigated the effect, at 6 weeks and 9 months, of pulsed ultrasound treatment in patients with type I or type II calcific tendinitis of the shoulder. After 6 weeks, the CMS score was significantly increased in 75% of the treated patients and only 34% of the untreated

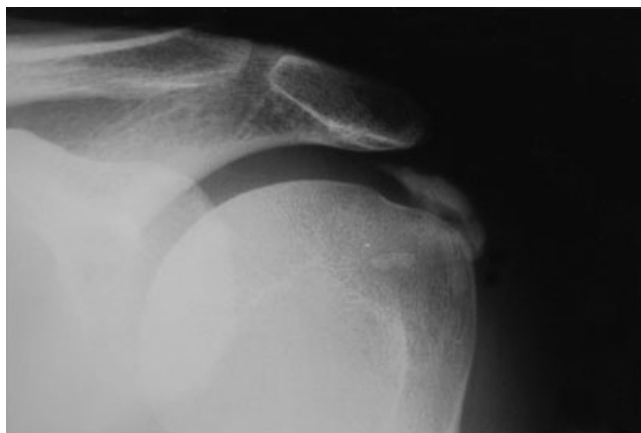
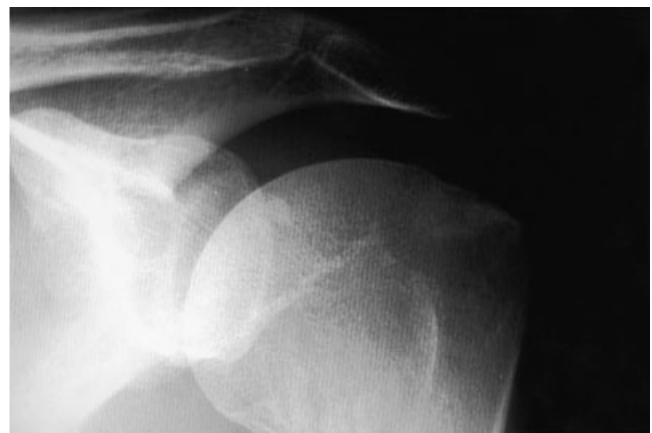**A****B**

Figure 2. Radiograph of the right shoulder of a 47-year-old man **A**, before and **B**, after treatment. The Gartner and Simons type II calcification has completely disappeared and the patient is pain free.

Table 4. Mean values of vital signs, hematology, blood chemistry, and urinalysis before and after treatment in both groups*

Outcomes	Study group (n = 40)			Control group (n = 40)		
	Before	After	P	Before	After	P
Vital signs						
Systolic pressure	118.2 ± 9.6	117.9 ± 9.4	0.88	116.5 ± 10.2	116.3 ± 10.1	0.93
Diastolic pressure	71.7 ± 6.4	71.5 ± 6.1	0.87	72.6 ± 6.8	71.9 ± 6.4	0.63
Heart-beat	70.5 ± 7.6	70.4 ± 7.1	0.95	70.7 ± 8.2	70.6 ± 7.9	0.95
Hematology						
WBC, 1,000/mm ²	6.4 ± 1.3	6.4 ± 1.2	0.99	6.4 ± 1.4	6.6 ± 1.3	0.51
RBC, 1,000,000/mm ²	4.7 ± 0.4	4.8 ± 0.4	0.99	4.8 ± 0.4	4.7 ± 0.4	0.27
Hgb, gm/dl	13.8 ± 1.0	13.9 ± 1.1	0.98	13.9 ± 1.1	13.8 ± 1.2	0.70
Hct, %	42.8 ± 2.9	42.9 ± 3.3	0.88	43.1 ± 3.1	42.7 ± 3.2	0.57
MCV, fl	90.0 ± 3.8	89.7 ± 3.9	0.72	90.3 ± 4.7	89.9 ± 4.8	0.70
MCH, pg	29.1 ± 1.7	28.7 ± 1.6	0.28	29.2 ± 1.8	29.1 ± 1.8	0.80
MCHC, gm/dl	32.2 ± 1.5	32.3 ± 1.1	0.73	32.3 ± 1.4	32.5 ± 1.1	0.48
Platelets, 1,000/m ²	242.3 ± 41.7	241.2 ± 40.7	0.90	240.3 ± 51.4	248.7 ± 53.9	0.47
MPV, fl	8.9 ± 0.8	8.8 ± 1.0	0.62	8.8 ± 0.8	8.6 ± 0.9	0.29
Granulocytes, %	55.6 ± 8.3	57.0 ± 8.8	0.46	55.6 ± 8.5	56.7 ± 7.3	0.53
Lymphocytes, %	31.7 ± 7.8	31.1 ± 7.6	0.72	32.1 ± 8.1	31.1 ± 6.9	0.55
Monocytes, %	6.9 ± 1.8	6.7 ± 1.9	0.63	7.1 ± 1.9	6.8 ± 1.9	0.48
Eosinophils, %	2.1 ± 1.3	2.2 ± 1.5	0.75	1.7 ± 1.3	1.5 ± 1.2	0.47
Basophils, %	0.8 ± 0.3	0.9 ± 0.4	0.21	0.8 ± 0.3	0.8 ± 0.2	0.99
Luc, %	2.1 ± 0.8	2.0 ± 0.7	0.55	2.0 ± 0.6	1.9 ± 0.7	0.49
Blood chemistry						
BUN, mg/dl	34.5 ± 8.4	34.2 ± 7.9	0.87	34.5 ± 10.5	35.3 ± 9.6	0.72
Glucose	78.7 ± 6.8	80.4 ± 7.6	0.29	77.5 ± 8.7	79.7 ± 9.3	0.28
Creatinine	0.8 ± 0.1	0.8 ± 0.2	0.99	0.8 ± 0.1	0.8 ± 0.2	0.99
GOT, IU/liter	19.4 ± 6.0	20.5 ± 6.2	0.42	19.7 ± 6.5	21.5 ± 6.1	0.20
GPT, IU/liter	21.2 ± 12.6	24.3 ± 19.3	0.39	21.9 ± 13.3	22.6 ± 14.8	0.82
GGT, IU/liter	18.6 ± 11.6	19.9 ± 14.6	0.66	17.1 ± 8.3	18.6 ± 12.6	0.53
Bilirubin direct	0.15 ± 0.1	0.17 ± 0.1	0.37	0.14 ± 0.1	0.15 ± 0.1	0.65
Bilirubin indirect	0.49 ± 0.2	0.51 ± 0.3	0.72	0.40 ± 0.2	0.44 ± 0.2	0.37
Bilirubin total	0.63 ± 0.2	0.71 ± 0.4	0.26	0.57 ± 0.2	0.60 ± 0.2	0.50
AP, IU/ml	157.0 ± 36.1	161.9 ± 34.8	0.54	159.6 ± 34.3	162.2 ± 36.2	0.74
Urinalysis						
pH	5.8 ± 0.4	5.9 ± 0.7	0.43	5.7 ± 0.5	5.9 ± 0.7	0.14
Specific weight	1,016 ± 5.5	1,017 ± 4.6	0.30	1,016 ± 5.7	1,017 ± 3.7	0.35

* Values are the mean ± SD. WBC = white blood cell; RBC = red blood cell; Hgb = hemoglobin; Hct = hematocrit; MCV = mean corpuscular volume; MCH = mean corpuscular hemoglobin; MCHC = mean corpuscular hemoglobin concentration; MPV = mean platelet volume; Luc = Large unformed cells; BUN = blood unproteic nitrogen; GOT = glutamic oxaloacetic transaminase; GPT = glutamic pyruvic transaminase; GGT = gammaglutamyl transaminase; AP = alkaline phosphatase.

patients, and the calcifications had completely disappeared in 19% and partially disappeared in 28% of treated patients, in comparison with 0% and 3% of the untreated patients, respectively.

Nevertheless, as demonstrated by our results, the use of EDTA significantly increases the number of calcifications that completely disappear. In a previous nonrandomized, placebo-controlled study consisting of 31 patients, Soncini and Costantino (40) reported their experience using disodium EDTA administered by mesotherapy for the treatment of patients with calcific tendinitis of the shoulder. A mixture comprised of 0.4 cc of 20% disodium EDTA and 1.6 cc of 2% lidocaine was administered by mesotherapy in 5 sessions, the first 3 at 2-week intervals and the last 2 at 1-month intervals. An improvement in VAS score was reported in 93.5% of patients with a complete and partial resorption of calcifications in 80% and 13% of patients, respectively.

In addition, the results of this randomized, placebo-

controlled study strongly support the hypothesis that disodium EDTA administered by phonophoresis and mesotherapy is effective in reducing pain, improving shoulder function, and removing calcifications. Moreover, these results were maintained at the 1-year followup. Reduction in pain, as evaluated by VAS scores, is comparable with that observed in other studies in which shock wave therapy was used (21,22) for the treatment of calcific tendinitis of the shoulder. Moreover, the functional improvement of the shoulder, as evaluated by means of the CMS, is also comparable with that obtained by other researchers with the use of shock wave therapy (18,19).

The results of our study suggest that disodium EDTA administered by means of single-needle mesotherapy and phonophoresis should be preferred to classic physiotherapy for treating calcific tendinitis of shoulder. Moreover, it represents a valid alternative to the use of shock wave therapy due to comparable effectiveness (18–22), lower costs, and greater availability. Further studies are needed

to compare 1) the effectiveness of disodium EDTA administered as in this study versus shock wave therapy, and 2) the effectiveness of phonophoresis with disodium EDTA versus ultrasound in the management of calcific tendinitis of the shoulder.

Possible weaknesses of our study are a small number of patients, a followup period that was not sufficiently long enough to determine the long-term effect of disodium EDTA treatment and to assess its effects on the long-term quality of life in our patients, and the impossibility to independently assess the 2 administration modalities of disodium EDTA. However, there was a statistically significant difference across scores in the 2 groups and within the study group before and at the end of treatment, and at 1-year followup, suggesting that the use of disodium EDTA by mesotherapy and phonophoresis improves disappearance of calcifications, reduces shoulder pain, increases CMS, and is safe and effective in the treatment of the calcifications of shoulder.

AUTHOR CONTRIBUTIONS

Dr. Cacchio had full access to all of the data in the study and takes responsibility for the integrity of the data and the accuracy of the data analysis.

Study design. Cacchio, De Blasis, Desiati, Spacca, Santilli, De Paulis.

Acquisition of data. Cacchio, De Blasis, Desiati, De Paulis.

Analysis and interpretation of data. Cacchio, De Blasis, Desiati, Spacca, Santilli, De Paulis.

Manuscript preparation. Cacchio, De Blasis, De Paulis.

Statistical analysis. Cacchio, Spacca, Santilli, De Paulis.

REFERENCES

- Wainner RS, Hasz M. Management of acute calcific tendinitis of the shoulder. *J Orthop Sports Phys Ther* 1998;27:231-7.
- Bosworth BM. Calcium deposits in the shoulder and subacromial bursitis: a survey of 12122 shoulders. *JAMA* 1941;116:2477-82.
- Milone FP, Copeland MM. Calcific tendinitis of the shoulder joint: presentation of 136 cases treated by irradiation. *Am J Roentgenol Radium Ther Nucl Med* 1961;85:901-13.
- Gartner J, Simons B. Analysis of calcific deposits in calcifying tendinitis. *Clin Orthop Relat Res* 1990;254:111-20.
- Hayes CW, Conway WF. Calcium hydroxyapatite depositing disease. *Radiographics* 1990;10:1031-48.
- Moseley HF. The natural history and clinical syndromes produced by calcified deposits in the rotator cuff. *Surg Clin North Am* 1963;43:1489-93.
- Uthoff HK, Sarkar K. Calcifying tendinitis. In: Rockwood CA, Matsen FA 3rd, editors. *The shoulder*. Philadelphia: WB Saunders; 1990.
- McKendry RJ, Uthoff HK, Sarkar K, Hyslop PS. Calcifying tendinitis of the shoulder: prognostic value of clinical, histologic, and radiologic features in 57 surgically treated cases. *J Rheumatol* 1982;9:75-80.
- Wagenhauser JF. Die periartropatie-syndrome. *Therapiewoche* 1972;37:3187-92.
- Gartner J. Tendinosis calcarea: results of treatment with needling. *Z Orthop Ihre Grenzgeb* 1993;131:461-9. In German.
- Perron M, Malouin F. Acetic acid iontophoresis and ultrasound for the treatment of calcifying tendinitis of the shoulder: a randomised control trial. *Arch Phys Med Rehabil* 1997;78:379-84.
- Leduc BE, Caya J, Tremblay S, Bureau NJ, Dumont M. Treatment of calcifying tendinitis of the shoulder by acetic acid iontophoresis: a double-blind randomized controlled trial. *Arch Phys Med Rehabil* 2003;84:1523-7.
- Gimblett PA, Saville J, Ebrall P. A conservative management protocol for calcific tendinitis of the shoulder. *J Manipulative Physiol Ther* 1999;22:622-7.
- Ebenbichler GR, Resch KL, Graninger WB. Resolution of calcium deposits after therapeutic ultrasound of the shoulder [letter]. *J Rheumatol* 1997;24:235-6.
- Ebenbichler GR, Erdogmus CB, Resch KL, Funovics MA, Kainberger F, Barisani G, et al. Ultrasound therapy for calcific tendinitis of the shoulder. *N Engl J Med* 1999;340:1533-8.
- Green S, Buchbinder R, Glazier R, Forbes A. Systematic review of randomised controlled trials of interventions to painful shoulder: selection criteria, outcome assessment, and efficacy. *BMJ* 1998;316:354-60.
- Aina R, Cardinal E, Bureau NJ, Aubin B, Brassard P. Calcific shoulder tendinitis: treatment with modified US-guided fine-needle technique. *Radiology* 2001;221:455-61.
- Loew M, Daecke W, Kusnierczak D, Rahmanzadeh M, Ewerbeck V. Shock-wave therapy is effective for chronic calcifying tendinitis of the shoulder. *J Bone J Surg Br* 1999;81:863-7.
- Wang CJ, Ko JY, Chen HS. Treatment of calcifying tendinitis of the shoulder with shock wave therapy. *Clin Orthop Relat Res* 2001;387:83-9.
- Rompe JD, Zoellner J, Nafe B. Shock wave therapy versus conventional surgery in the treatment of calcifying tendinitis of the shoulder. *Clin Orthop Relat Res* 2001;387:72-82.
- Gerdesmeyer L, Wagenpfeil S, Haake M, Maier M, Loew M, Wortler K, et al. Extracorporeal shock wave therapy for the treatment of chronic calcifying tendonitis of the rotator cuff. *JAMA* 2003;290:2573-80.
- Cacchio A, Paoloni M, Barile A, Don R, De Paulis F, Calvisi V, et al. Effectiveness of radial shock-wave therapy for calcific tendinitis of the shoulder: single-blind, randomized clinical study. *Phys Ther* 2006;86:672-82.
- Ark JW, Flock TJ, Flatow EL, Bigliani LU. Arthroscopic treatment of calcific tendinitis of the shoulder. *Arthroscopy* 1992;8:183-8.
- Jerosch J, Strauss JM, Schmiel S. Arthroscopic treatment of calcific tendinitis of the shoulder. *J Shoulder Elbow Surg* 1998;7:30-7.
- Holleman AF, Wiberg E. *Inorganic chemistry*. San Diego: Academic Press; 2001.
- Scalella P, Pozzuoli A, Cossettini M, Bacelle L, Primon D, Ortolani L, et al. Azione biochimica dell'EDTA nel trattamento fisioterapico della periartrite calcifica di spalla. *Eur Med Phys* 1995;31:153-8.
- Byl N. The use of ultrasound as an enhancer for transcutaneous drug delivery: phonophoresis. *Phys Ther* 1995;75:539-53.
- Ballerini R, Casini A, Chinol M, Mannucci C, Giaccai L, Salvi M. Study on the absorption of ketoprofen topically administered in man: comparison between tissue and plasma levels. *Int J Clin Pharmacol Res* 1986;6:69-72.
- Oziomek R, Perrin D, Herold D, Denegar C. Effect of phonophoresis on serum salicylate levels. *Med Sci Sports Exerc* 1990;23:397-401.
- Bare A, McAnaw M, Pritchard A. Phonophoretic delivery of 10% hydrocortisone through the epidermis of humans as determined by serum cortisol concentrations. *Phys Ther* 1996;76:738-49.
- Pistor M. What is mesotherapy? *Chir Dent Fr* 1976;46:59-60. In French.
- Dalloz-Bourguignon A. A new therapy against pain: mesotherapy. *J Belge Med Phys Rehabil* 1979;2:230-4. In French.
- Rohrich RJ. Mesotherapy: what is it? Does it work? [editorial]. *Plast Reconstr Surg* 2005;115:1425.
- Einholtz B, Maudet D, Bicheron M. Use of NHA1 via mesotherapy in oral surgery. *Actual Odontostomatol (Paris)* 1990;44:285-98. In French.
- Guazzetti R, Iotti E, Marinoni E. Mesotherapy with naproxen sodium in musculoskeletal diseases. *Riv Eur Sci Med Farmacol* 1988;10:539-42. In Italian.
- Menkes CJ, Laoussadi S, Kac-Ohana N, Lasserre O. Controlled

- trial of injectable diclofenac in mesotherapy for the treatment of tendinitis. *Rev Rhum Mal Osteoartic* 1990;57:589–91. In French.
37. Palermo S, Riello R, Cammardella MP, Carossino D, Orlandini G, Casigliani R, et al. TENS + mesotherapy association in the therapy of cervico-brachialgia: preliminary data [letter]. *Minerva Anesthesiol* 1991;57:1084–5. In Italian.
 38. Colombo I, Rega V, Cossu M, Cigolini M, Radaelli E. La ionoforesi medicamentosa con EDTA nelle periartriti calcifiche di spalla. *La Riabilitazione* 1986;19:211–20.
 39. Gazzi A, Ponzetti F, Ricci L, Cortese G, Buosi C. La mesoterapia con EDTA nella periartrite scapolo-omerale calcifica (morbo di Duplay), risultati incoraggianti. *La Riabilitazione* 1984;17:141–5.
 40. Soncini G, Costantino C. The treatment of pathologic calcification of shoulder tendons with EDTA biosodium salt by mesotherapy. *Acta Biomed Ateneo Parmense* 1998;69:133–8. In Italian.
 41. Constant CR, Murley AH. A clinical method of functional assessment of the shoulder. *Clin Orthop Relat Res* 1987;214:160–4.
 42. Kilcoyne RF, Reddy PK, Lyons F, Rockwood CA Jr. Optimal plain film imaging of the shoulder impingement syndrome. *Am J Roentgenol* 1989;153:795–7.
 43. Hollis S, Campbell F. What is meant by intention to treat analysis? Survey of published randomised controlled trials. *BMJ* 1999;319:670–4.
 44. Goodman A, Rail T, Nies A, Taylor P. Goodman and Gilman's pharmacological basis of therapeutics. New York: Pergamon Press; 1990.